Research Square

Preprints are preliminary reports that have not undergone peer review.
They should not be considered conclusive, used to inform clinical practice,
or referenced by the media as validated information.

Craniosynostosis and Intracranial Hypertension in RASopathies: A Report of Two Cases with SHOC2 and KRAS Mutations

Kotaro Ishimoto

noukotaro@gmail.com

Osaka City General Hospital

Noritsugu Kunihiro

Osaka City General Hospital

Ryoko Umaba

Osaka City General Hospital

Tomoya Ishiguro

Osaka City General Hospital

Hiroaki Sakamoto

Osaka City General Hospital

Case Report

Keywords: Craniosynostosis, RASopathies, Intracranial hypertension, Papilledema, SHOC2, KRAS

Posted Date: November 10th, 2026

DOI: https://doi.org/10.21203/rs.3.rs-10858469/v1

License: This work is licensed under a Creative Commons Attribution 4.0 International License.
Read Full License

Additional Declarations: No competing interests reported.

Title Page

Title: Craniosynostosis and Intracranial Hypertension in RASopathies: A Report of Two Cases with *SHOC2* and *KRAS* Mutations

Authors: Kotaro Ishimoto MD, Noritsugu Kunihiro MD, PhD, Ryoko Umaba MD, PhD, Tomoya Ishiguro MD, Hiroaki Sakamoto MD, PhD.

Affiliations: Department of Pediatric Neurosurgery, Osaka City General Hospital, Osaka, Japan.

Corresponding Author: Kotaro Ishimoto MD, Department of Pediatric Neurosurgery, Osaka City General Hospital, Osaka, Japan. Email: noukotaro@gmail.com

Keywords: Craniosynostosis; RASopathies; Intracranial hypertension; Papilledema; *SHOC2*; *KRAS*

Abstract

Background: Craniosynostosis is a known complication of RASopathies. Its potential to cause progressive intracranial hypertension, which compromises both neurodevelopment and visual function, is under-recognized. We report two cases presenting with papilledema.

Case Presentation: Case 1 was a 2-year-old boy with a *SHOC2* mutation (Noonan-like syndrome) who presented with multi-suture synostosis and papilledema. Case 2 was a 3-year-old girl with a *KRAS* mutation (cardiofaciocutaneous syndrome) presenting with pansynostosis and papilledema. Both patients underwent urgent cranial vault expansion. Postoperatively, papilledema resolved, and marked acceleration in psychomotor development was observed in both cases.

Conclusion: Craniosynostosis in RASopathies can lead to significant intracranial hypertension that could hamper psychomotor development as well as vision. Awareness of this progressive risk and careful evaluation, including fundoscopy, are essential for ensuring timely cranial decompression to facilitate developmental catch-up.

Introduction

RASopathies, caused by dysregulation of the RAS/MAPK signaling pathway, encompass congenital multisystem disorders including Noonan, cardiofaciocutaneous (CFC), and Costello syndromes. While characteristic craniofacial features are

hallmarks, craniosynostosis is a less common but distinct complication [1]. Current literature links *KRAS* and *SHOC2* mutations to premature suture fusion [2, 3]; however, severe craniosynostosis complicated by elevated intracranial pressure (ICP) requiring urgent surgery remains exceptionally rare. We present two RASopathy cases with *SHOC2* and *KRAS* mutations presenting with severe craniosynostosis and papilledema, requiring urgent cranial vault remodeling. We discuss the importance of careful evaluation including fundoscopy to detect silent progression and of timely decompression to facilitate developmental catch-up.

Case Presentation

Case 1

A boy was referred at 2.5 years of age for cranial deformity. Born at 38 weeks, his early infancy involved poor feeding and vomiting, requiring prolonged nasogastric tube feeding. Serial measurements revealed profound failure to thrive (e.g., at 25 months: height 72.6 cm, −4.73 standard deviations [SD]; weight 8.7 kg, −3.26 SD). Conversely, his head circumference showed progressive, disproportionate expansion, increasing from 44.0 cm (+0.17 SD) at 6 months to 51.2 cm (+1.88 SD) at 25 months. He exhibited characteristic facial features and atrial septal anomalies. Psychomotor development was significantly delayed (head control at 7 months, sitting at 14 months, only babbling at 2 years). Genetic analysis identified a heterozygous *SHOC2* mutation (c.4A>G, p.Ser2Gly), confirming Noonan-like syndrome with loose anagen hair. Marked scaphocephaly was noted at 2.5 years. Although vomiting was previously attributed to feeding difficulties, fundoscopy revealed bilateral papilledema. Three-dimensional computed tomography (3D-CT) demonstrated premature fusion of the metopic, sagittal, bilateral lambdoid, and lateral bilateral coronal sutures (Fig. 1). He underwent urgent cranial vault remodeling for elevated ICP. Postoperatively, vomiting ceased, appetite increased, and meaningful speech emerged. By 5.5 years, his development progressed steadily, achieving a Developmental Quotient of 67 (Kyoto Scale of Psychological Development) [4].

Case 2

A 3-year-old girl, born prematurely at 30 weeks with very low birth weight, was evaluated for progressive cranial deformity. She presented with characteristic facial features, cutis laxa, pulmonary stenosis, hypertrophic cardiomyopathy, and severe feeding difficulties necessitating a gastrostomy at 26 months. She exhibited profound, persistent global growth failure; at 3 years, her height was 72.5 cm (−6.27 SD), weight 9.7 kg (−2.25 SD), and head circumference was 44.7 cm (−3.13 SD). Psychomotor development was severely delayed (head control at 10 months, sitting at 27 months, no expressive speech at 3 years). Genetic analysis revealed a heterozygous *KRAS* mutation (c.179G>T, p.Gly60Val), confirming CFC syndrome. Following anterior fontanelle closure at 16 months, a bregmatic bony prominence progressed. 3D-CT demonstrated pansynostosis (Fig. 2). Fundoscopy revealed bilateral papilledema,

indicative of elevated ICP. Urgent cranial vault remodeling was performed, resolving the papilledema. Postoperatively, her neurodevelopmental trajectory noticeably improved, demonstrated by increased smiling and novel visual tracking abilities.

Discussion

Craniosynostosis is an increasingly recognized RASopathy complication, with 41 cases (including ours) reported since 2006 (Table 1). While the exact pathogenic mechanism remains unknown, reports speculate on an interaction between the FGFR and RAS/MAPK signaling pathways [3, 5].

Genetic etiology plays a critical role in the occurrence and severity of this complication. *KRAS* mutations exhibit a strikingly high association with suture fusion; Addissie et al. reported a ~10% (6/62) prevalence in *KRAS*-mutated Noonan syndrome, over 300-fold higher than the general population [5]. Serbinski et al. also identified *KRAS* variants in a large subset of cases (13/35) [6]. Furthermore, Ueda et al. noted that *KRAS* mutations frequently cause multisuture involvement, including pansynostosis, suggesting a stronger osteogenic stimulus than *BRAF* or *PTPN11* mutations [11]. Our cases align with these high-risk genetic profiles: Case 2 possessed a *KRAS* mutation with severe pansynostosis, and Case 1 carried a *SHOC2* mutation, which is similarly associated with severe multi-suture fusion [3].

Over half of the reported cases (22/41) were diagnosed after age 2, sometimes lacking evident abnormalities at initial radiological workups [6, 7]. In our cases, head deformities progressed from infancy to diagnoses at 2.5 (Fig. 1) and 3 years (Fig. 2), highlighting the frequency of late-onset or progressive craniosynostosis. On the other hand, cases diagnosed prenatally or in early infancy suggest early suturectomy is possible, emphasizing the dual importance of early detection and long-term surveillance [6].

Notably, 16 of the 41 reported cases did not undergo surgical intervention (Table 1), predominantly those with single sagittal fusions, suggesting conservative management is often chosen for presumed mild deformities. While some cases showed digital impressions, only one prior case documented papilledema as a definitive sign of elevated ICP. Our *SHOC2* and *KRAS* cases are uniquely significant: both demonstrated overt intracranial hypertension (papilledema) and marked psychomotor catch-up following decompression. This suggests late-onset cases may harbor insidious functional impairments warranting aggressive surgical management, even if initial presentations appear non-acute.

Non-specific symptoms of intracranial hypertension—like poor appetite, vomiting, or developmental stagnation—are easily misattributed to the underlying syndrome. In Case 1, vomiting and poor weight gain were initially managed as syndromic feeding issues. However, their resolution and the emergence of meaningful speech post-remodeling suggest they manifested insidious ICP elevation.

The functional burden of late-onset craniosynostosis may be significantly underestimated in RASopathies, masked by their complex medical status. Relying solely on classic neurological signs of elevated ICP or cosmetic appearance can delay necessary intervention. Unexplained developmental stagnation or persistent gastrointestinal symptoms should prompt comprehensive systemic, neurosurgical, and ophthalmological assessments—including routine fundoscopy—to detect progressive craniosynostosis and guide individualized surgical decisions.

Conclusion

Craniosynostosis in RASopathies can manifest as a severe, progressive condition with frequent late-onset presentations. Significant intracranial hypertension can develop insidiously, with non-specific symptoms like vomiting and developmental delay often masked by systemic complexity. Timely surgical decompression, determined through comprehensive evaluation, effectively promotes neurodevelopmental potential and facilitates significant catch-up.

Declarations

Acknowledgments

The authors would like to thank the patients and their families for their cooperation and consent to the publication of this case report.

Conflicts of Interest

The authors declare that they have no conflicts of interest.

Funding

The authors did not receive support from any organization for the submitted work. No funding was received to assist with the preparation of this manuscript.

Informed Consent

Written informed consent was obtained from the parents of both patients for the publication of this case report and any accompanying images.

Ethics Approval

This study was approved by the Ethics Committee of Osaka City General Hospital.

References

1. Kratz CP, Zampino G, Kriek M, et al. Craniosynostosis in patients with Noonan syndrome caused by germline KRAS mutations. Am J Med Genet A. 2009;149A(5):1036-1040. https://doi.org/10.1002/ajmg.a.32786
2. Brasil AS, Malaquias AC, Kim CA, et al. KRAS gene mutations in Noonan syndrome familial cases cluster in the vicinity of the switch II region of the G-domain: report of another family with metopic craniosynostosis. Am J Med Genet A. 2012;158A(5):1178-1184. https://doi.org/10.1002/ajmg.a.35270
3. Takenouchi T, Sakamoto Y, Miwa T, et al. Severe craniosynostosis with Noonan syndrome phenotype associated with SHOC2 mutation: clinical evidence of crosslink between FGFR and RAS signaling pathways. Am J Med Genet A. 2014;164A(11):2869-2872. https://doi.org/10.1002/ajmg.a.36705
4. Tatsuta N, Suzuki K, Sugawara T, Nakai K, Hosokawa T, Satoh H. Comparison of Kyoto Scale of Psychological Development and Bayley Scales of Infant Development second edition among Japanese Infants. J Spec Educ Res. 2013;2(1):17-24. https://doi.org/10.6033/specialeducation.2.17
5. Addissie YA, Kotecha U, Hart RA, Martinez AF, Kruszka P, Muenke M. Craniosynostosis and Noonan syndrome with KRAS mutations: expanding the phenotype with a case report and review of the literature. Am J Med Genet A. 2015;167A(11):2657-2663. https://doi.org/10.1002/ajmg.a.37259
6. Serbinski CR, Vanderwal A, Chadwell SE, et al. Prenatal and infantile diagnosis of craniosynostosis in individuals with RASopathies. Am J Med Genet A. 2024;194(2):195-202. https://doi.org/10.1002/ajmg.a.63397
7. Weaver KN, Care M, Wakefield E, Zarate YA, Skoch J, Gripp KW, Prada CE. Craniosynostosis is a feature of Costello syndrome. Am J Med Genet A. 2022;188(4):1280-1286. https://doi.org/10.1002/ajmg.a.62620
8. Schubbert S, Zenker M, Rowe SL, et al. Germline KRAS mutations cause Noonan syndrome. Nat Genet. 2006;38(3):331-336. https://doi.org/10.1038/ng1748
9. Lo FS, Lin JL, Kuo MT, et al. Noonan syndrome caused by germline KRAS mutation in Taiwan: report of two patients and a review of the literature. Eur J Pediatr. 2009;168(8):919-923. https://doi.org/10.1007/s00431-008-0858-z
10. Bertola D, Yamamoto G, Buscarilli M, Jorge A, Passos-Bueno MR, Kim C. The recurrent PPP1CB mutation p.Pro49Arg in an additional Noonan-like syndrome individual: broadening the clinical phenotype. Am J Med Genet A. 2017;173(3):824-828. https://doi.org/10.1002/ajmg.a.38070
11. Ueda K, Yaoita M, Niihori T, Aoki Y, Okamoto N. Craniosynostosis in patients with RASopathies: Accumulating clinical evidence for expanding the phenotype. Am J Med Genet A. 2017;173(9):2346-2352. https://doi.org/10.1002/ajmg.a.38337
12. McDonald BS, Pigors M, Kelsell DP, et al. Noonan syndrome with multiple lentigines and associated craniosynostosis. Clin Exp Dermatol. 2018;43(3):357-359. https://doi.org/10.1111/ced.13329

13. Davis AA, Zuccoli G, Haredy MM, et al. RASopathy in patients with isolated sagittal synostosis. Glob Pediatr Health. 2019;6:2333794X19846774. https://doi.org/10.1177/2333794X19846774
14. Rodríguez F, Ponce D, Berward FJ, Lopetegui B, Cassorla F, Aracena M. RAF1 variant in a patient with Noonan syndrome with multiple lentigines and craniosynostosis. Am J Med Genet A. 2019;179(8):1598-1602. https://doi.org/10.1002/ajmg.a.61203
15. Yamada M, Funato M, Kondo G, et al. Noonan syndrome-like phenotype in a patient with heterozygous ERF truncating variant. Congenit Anom (Kyoto). 2021;61(6):226-230. https://doi.org/10.1111/cga.12435
16. Nagai K, Niihori T, Okamoto N, et al. Duplications in the G3 domain or switch II region in HRAS identified in patients with Costello syndrome. Hum Mutat. 2022;43(1):3-15. https://doi.org/10.1002/humu.24287
17. Dentici ML, Niceta M, Lepri FR, et al. Loss-of-function variants in ERF are associated with a Noonan syndrome-like phenotype with or without craniosynostosis. Eur J Hum Genet. 2024;32(8):954-963. https://doi.org/10.1038/s41431-024-01642-7

Figure Legends & Tables

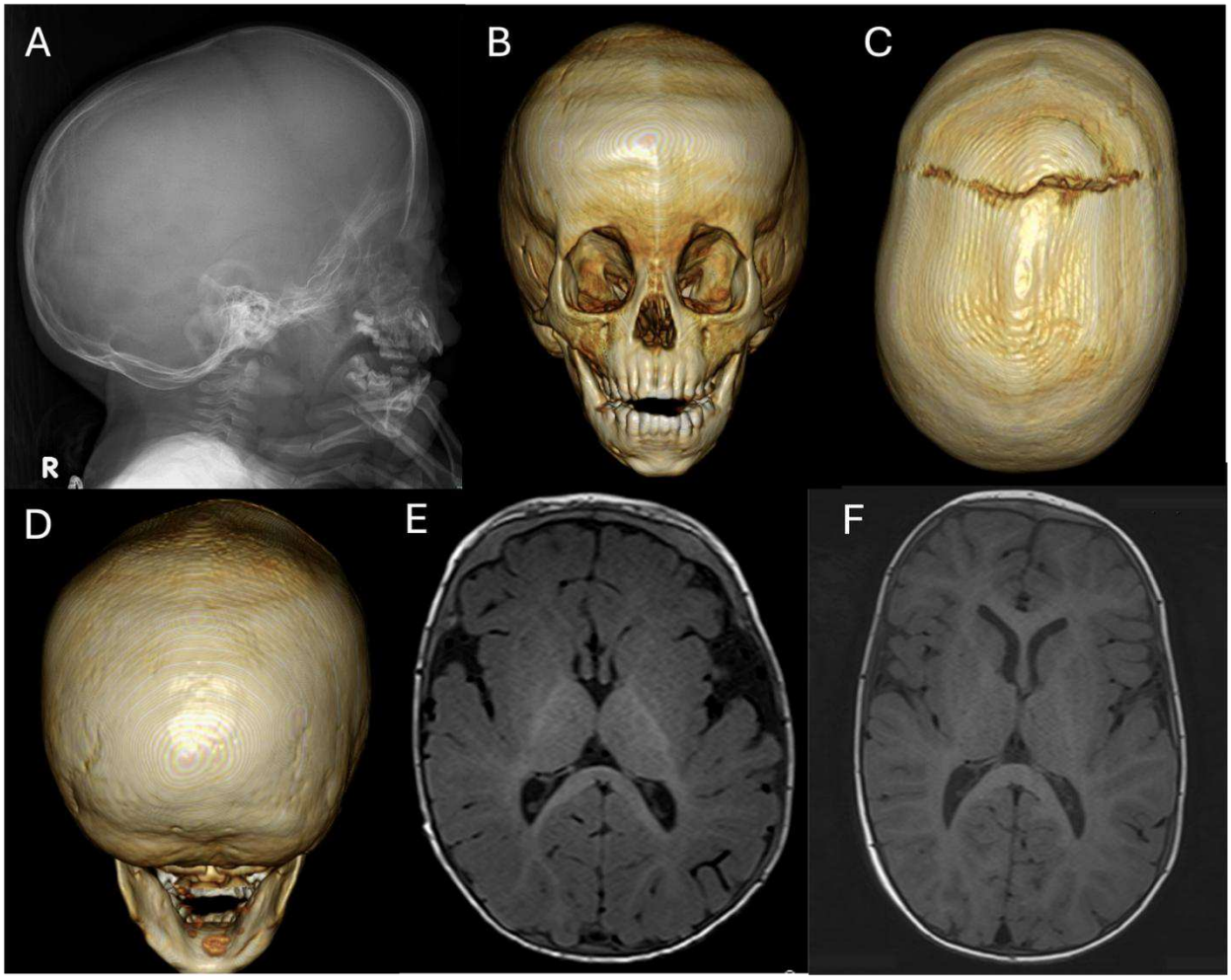

Fig. 1 Radiological findings of Case 1. **A** Lateral skull radiograph at 2 years and 6 months of age showing evident digital impressions in the occipital region. **B-D** Three-dimensional computed tomography (3D-CT) reconstructed images at 2 years and 6 months of age revealing premature fusion of the metopic, sagittal, bilateral lambdoid, and lateral portions of the bilateral coronal sutures. **E, F** Axial magnetic resonance imaging (MRI) at 1 year of age (**E**) and 2 years and 6 months of age (**F**), demonstrating the progressive development of scaphocephaly

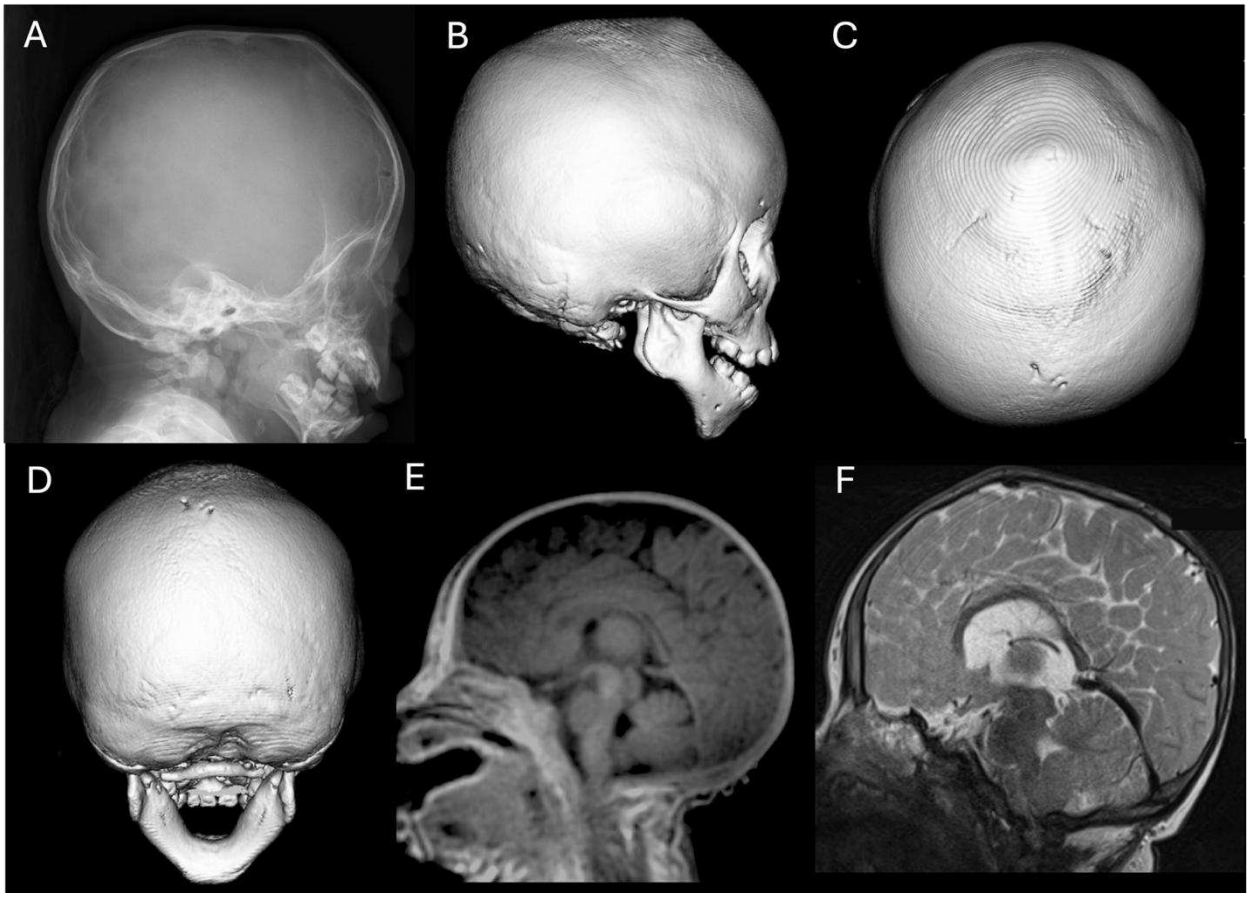

Fig. 2 Radiological findings of Case 2. **A** Lateral skull radiograph at 3 years of age showing diffuse digital impressions. **B-D** Three-dimensional computed tomography (3D-CT) reconstructed images at 3 years of age revealing premature fusion of all cranial sutures (pansynostosis) and a bony prominence at the anterior fontanelle. **E, F** Sagittal magnetic resonance imaging (MRI) at 3 months of age (**E**) and 3 years of age (**F**), indicating progressive changes with the development of anterior fontanelle bulging and tonsillar herniation in the latter scan

Table 1 Summary of reported cases of craniosynostosis associated with RASopathies

Reference	Syndrome (Gene)	Age at Craniosynostosis Diagnosis	Involved Sutures	Signs of elevated ICP	Surgical Intervention for Craniosynostosis
Our case (#1)	NSLAH (*SHOC2*)	2.5 years	Metopic, Sagittal, Bi-Lambdoid	Papilledema	Cranial vault remodeling
Our case (#2)	CFC (*KRAS*)	3 years	All Cranial Sutures	Papilledema	Cranial vault remodeling

Serbinski 2024 (#1)	NS (*PTPN11*)	Prenatal (34w)	R Lambdoid	No	endoscopic craniectomy
Serbinski 2024 (#2)	CFC (*KRAS*)	Birth	Bi-coronal	No	craniotomy
Serbinski 2024 (#3)	NS (*KRAS*)	Prenatal	R Coronal, Sagittal	No	endoscopic craniectomy
Serbinski 2024 (#4)	CFC (*KRAS*)	5 years	Sagittal	No	No
Serbinski 2024 (#5)	CFC (*KRAS*)	3 years	Multisuture	No	No
Dentici 2024 (#402)	NS-like (*ERF*)	Infancy	Lambdoid	No	Yes (details not specified)
Dentici 2024 (#601)	NS-like (*ERF*)	Infancy	Sagittal	No	Yes (details not specified)
Dentici 2024 (#1401)	NS-like (*ERF*)	Infancy	Metopic	No	Yes (details not specified)
Weaver 2022 (#1)	CS (*HRAS*)	1.9 years	Sagittal	No	Cranial vault remodeling, Fronto-orbital remodeling
Weaver 2022 (#2)	CS (*HRAS*)	2.8 years	Sagittal	No	No
Weaver 2022 (#3)	CS (*HRAS*)	3.5 years	R Coronal, Sagittal	Headaches	Posterior cranial vault remodeling (internal distraction)
Weaver 2022 (#4)	CS (*HRAS*)	3.5 years	Bi-coronal, Sagittal	No	Yes (details not specified)
Weaver 2022 (#5)	CS (*HRAS*)	2.5 years	Metopic	No	Cranial vault remodeling
Nagai 2021	CS (*HRAS*)	1.5 years	Sagittal	No	Not reported
Yamada 2021	NS-like (*ERF*)	10 years	Sagittal, Bi-lambdoid	No	No
Rodríguez 2019	NSML (*RAF1*)	2 weeks	Cloverleaf	Digital impressions	Yes
Davis 2019 (#1)	NS (*KRAS*)	5 months	Sagittal	Optic nerve pallor, papilledema	craniectomy and barrel stave osteotomy
Davis 2019 (#2)	CFC (*BRAF*)	4.5 years	Sagittal	No	No
Davis 2019 (#3)	CFC (*BRAF*)	2.4 years	Sagittal	No	No
Davis 2019 (#4)	NS (*BRAF*)	5 months	Sagittal	No	Right and left frontal craniectomy
Davis 2019 (#5)	NS (*PTPN11*)	3.5 years	Sagittal	No	No
McDonald 2018	NSML (*PTPN11*)	6 years	Sagittal	Yes (details not specified)	Yes (details not specified)
Bertola 2017	NSLAH (*PPP1CB*)	3 months	Sagittal, Bi-coronal	No	Cranioplasty
Ueda 2017 (#1)	CFC (*BRAF*)	3.4 years	Sagittal	Digital impressions	Cranioplasty
Ueda 2017 (#2)	CFC (*BRAF*)	3.5 years	Sagittal, Lambdoid	Digital impressions	Cranioplasty
Ueda 2017 (#3)	CFC (*BRAF*)	4.7 years	Sagittal	No	No
Ueda 2017 (#4)	CFC (*BRAF*)	12 years	R Squamosal	No	No
Ueda 2017 (#5)	CFC (*KRAS*)	4.9 years	All Cranial Sutures	Digital impressions	Cranioplasty
Ueda 2017 (#6)	CFC (*KRAS*)	17 years	All Cranial Sutures except in the caudal part of the Lambdoid suture	No	No
Ueda 2017 (#7)	NS (*PTPN11*)	7 years	Sagittal	Digital impressions	No
Ueda 2017 (#8)	NS (*PTPN11*)	9 years	Sagittal	Digital impressions	No
Ueda 2017 (#9)	NS (*PTPN11*)	5 years	Sagittal	Digital impressions	No
Addissie 2015	NS (*KRAS*)	2 months	Sagittal	No	No
Takenouchi 2014	NS (*SHOC2*)	2.25 years	R Coronal, Sagittal, Bi-lambdoid	Bulging fontanelle, No papilledema	Cranioplasty
Brasil 2012	NS (*KRAS*)	6 months	Metopic	No	Frontal and bi-temporal remodeling, Occipital remodeling
Kratz 2009 (#1)	NS (*KRAS*)	Neonate	Sagittal, Bi-coronal	Raised ICP (details not specified)	Yes (details not specified)
Kratz 2009 (#2)	NS (*KRAS*)	6 months	L Lambdoid	No	Yes
Lo 2009	NS (*KRAS*)	Unknown	Sagittal	No	No
Schubbert 2006	NS (*KRAS*)	1.1 years	Sagittal	No	No

CS: Costello Syndrome, **NS**: Noonan Syndrome, **CFC**: Cardiofaciocutaneous Syndrome, **NSML**: Noonan Syndrome with Multiple Lentigines, **NSLAH**: Noonan Syndrome-Like with Loose Anagen Hair