Research Square

Preprints are preliminary reports that have not undergone peer review.
They should not be considered conclusive, used to inform clinical practice,
or referenced by the media as validated information.

Free Floating Intraspinal Cyst in a 22-Month-Old Boy: A Case Report and Literature Review

Wang Fengting

wangft04@outlook.com

Shanghai Children's Medical Center, Shanghai Jiao Tong University School of Medicine

Gao Pingping

Shanghai Children's Medical Center, Shanghai Jiao Tong University School of Medicine

Xia Zeyang

Shanghai Children's Medical Center, Shanghai Jiao Tong University School of Medicine

Song Yunhai

Shanghai Children's Medical Center, Shanghai Jiao Tong University School of Medicine

Bao Nan

Shanghai Children's Medical Center, Shanghai Jiao Tong University School of Medicine

Yang Bo

Shanghai Children's Medical Center, Shanghai Jiao Tong University School of Medicine

---

Case Report

Keywords: Free-floating intraspinal cyst, Neuroepithelial cyst, Mobile spinal cyst, Pediatric neurosurgery

Posted Date: November 25th, 2026

DOI: https://doi.org/10.21203/rs.3.rs-10847854/v1

License: This work is licensed under a Creative Commons Attribution 4.0 International License. Read Full License

Additional Declarations: No competing interests reported.

Abstract

Background: Free-floating or mobile intraspinal cystic lesions are exceedingly rare, with the literature consisting mainly of isolated case reports. Their mobile nature within the cerebrospinal fluid can lead to intermittent or positional neurological symptoms, making early diagnosis challenging.

Case Presentation: We report a 22-month-old boy who presented with a three-month history of avoidance of walking. Magnetic resonance imaging (MRI) performed at an outside hospital revealed an intraspinal cystic lesion in the lower lumbar region. Notably, repeat preoperative MRI at our institution approximately one week later demonstrated that the cyst had shifted to the L3-L5 level, confirming its mobile nature. During surgery, a thin-walled, translucent cyst was found floating within the subarachnoid space without any pedicle or adhesion. The cyst was completely excised. Histopathological examination revealed a fibrous cyst wall lined by cuboidal epithelium, confirming the diagnosis of a neuroepithelial cyst. Postoperatively, the patient recovered uneventfully and resumed normal walking.

Conclusion: This case highlights the rare entity of a free-floating intraspinal neuroepithelial cyst in an infant. The change in cyst location between the outside hospital MRI and preoperative MRI underscores the importance of repeat imaging to confirm cyst mobility prior to surgery. Complete microsurgical excision resulted in excellent functional recovery. A focused review of the literature identified representative published cases of mobile or migrating intraspinal cystic lesions and cystic-appearing tumors, underscoring the rarity and heterogeneity of this condition.

1. Introduction

Intraspinal cysts are uncommon lesions, accounting for approximately 1–3% of spinal space-occupying lesions in older neurosurgical series [1]. While most intraspinal cysts are fixed to the spinal cord, nerve roots, or dura mater, a remarkable subset demonstrates mobility within the subarachnoid space [2]. Such "free-floating" or "mobile" cystic lesions are exceedingly rare, with reported examples largely limited to isolated case reports and small literature reviews [2–7]. The free-floating nature of these cysts is attributed to their smooth, non-adherent walls, which allow them to drift with changes in cerebrospinal fluid dynamics, patient posture, or gravitational forces [2]. This mobility can result in intermittent or positional neurological symptoms, as the cyst transiently compresses different neural structures depending on its location [2, 3].

The clinical presentation of free-floating cystic lesions can be insidious and intermittent [3]. In infants and toddlers, the presentation may be atypical, manifesting as gait abnormalities, developmental delay, unexplained irritability, or episodic weakness rather than the classic radicular pain or myelopathy seen in adults [3]. The subtle nature of these symptoms frequently leads to delayed diagnosis, as was the case in the present report.

Neuroepithelial (ependymal) cysts are benign congenital lesions thought to arise from sequestration of neuroepithelial cells during embryonic development [5, 8]. They are typically characterized by a thin, translucent wall lined by cuboidal or columnar epithelium and filled with clear, cerebrospinal fluid-like liquid [2, 5, 8]. The free-floating variant of intraspinal neuroepithelial cysts is exceptionally rare; to our knowledge, Bapat et al. reported the only prior intraspinal neuroepithelial cyst explicitly described as free-floating [2].

Herein, we report a rare case of a free-floating intraspinal neuroepithelial cyst in a 22-month-old boy presenting with avoidance of walking. We also present a focused review of representative published cases of mobile or migrating intraspinal cystic lesions and cystic-appearing tumors [2–7].

2. Case Presentation

2.1 History and Examination

A 22-month-old boy was admitted to our department in August, with a three-month history of avoidance of walking, which had progressively worsened over the past two weeks. The parents reported that the child had begun to avoid bearing weight on his lower limbs without any apparent trigger. Notably, there was no history of trauma, fever, or pain. The family had not initially sought medical attention because the child's limb movements appeared normal during play, and there was no tenderness on palpation. Over the two weeks prior to admission, the avoidance behavior became more pronounced, prompting referral to our hospital.

The child was the product of a full-term, uncomplicated vaginal delivery (G1P1), with no perinatal asphyxia. He was breastfed and had achieved developmental milestones appropriate for his age. His past medical history was significant only for a prior rotavirus infection. There was no family history of neurological disorders or spinal deformities.

On physical examination, the child was alert and interactive. There were no cutaneous stigmata of spinal dysraphism over the lumbosacral region. Neurological examination revealed normal muscle strength (grade 5/5) and tone in all four extremities. Deep tendon reflexes were symmetric and normoactive. There was no evidence of sensory deficit or pathological reflexes. The child demonstrated an obvious avoidance of walking, preferring to crawl or be carried rather than bear weight independently.

2.2 Imaging Studies

MRI of the lumbar spine performed at an outside hospital in July 2026, revealed an intraspinal cystic lesion in the lower lumbar region. The lesion demonstrated long T1 and long T2 signal characteristics, consistent with a cerebrospinal fluid-filled cyst. At that time, the cyst was located in the lower lumbar spinal canal, causing compression of the cauda equina (Fig. 1).

Preoperative MRI at our institution (Shanghai Children's Medical Center) in August 2026, approximately one week after the outside hospital study, revealed that the cystic lesion had shifted to the L3-L5 level. The lesion was now observed as a well-circumscribed, oval-shaped intradural extramedullary cystic mass at L3-L4, with isointense signal to cerebrospinal fluid on both T1-weighted and T2-weighted images. No internal septations or solid components were identified. Post-contrast imaging showed no enhancement of the cyst wall or contents. The conus medullaris was compressed and displaced cephalad. The filum terminale was thickened. The change in cyst location between the two MRI studies, obtained approximately one week apart, provided strong radiological evidence of the cyst's mobile nature (Fig. 2).

2.3 Surgical Procedure

The patient underwent surgery under general endotracheal anesthesia in the prone position. A midline longitudinal incision was made over the L4 spinous process, and following dissection through the subcutaneous tissue and paraspinal muscle layers, the lumbar spinal canal was exposed. Laminectomy was performed to expose the dura mater. Upon opening the dura, a thin-walled, translucent cyst was observed within the subarachnoid space; the cyst was completely free-floating without any pedicle or adhesions to the spinal cord, nerve roots, or dura, and was completely excised en bloc with gentle traction (Fig. 3). The filum terminale was identified as fibrotic and thickened with increased tension (diameter approximately 2 mm); it was coagulated bilaterally and transected. Neurolysis was performed to separate arachnoid adhesions around the cauda equina, and the spinal canal was irrigated with physiological saline. Hemostasis was confirmed, and the dura mater was closed in a watertight fashion. Specimens of the cyst wall and filum terminale were sent for histopathological examination.

2.4 Pathological Findings

Histopathological examination revealed the following:

Cyst specimen

The wall was composed predominantly of fibrous tissue lined by a single layer of cuboidal epithelium. There was evidence of fibrous degeneration, interstitial vascular dilatation, congestion, hemorrhage, and scattered inflammatory cell infiltration.

Filum terminale specimen

The specimen consisted of fibrous tissue with neuroepithelial structures and rare nerve fibers. Partial fibrous degeneration and interstitial vascular congestion were noted.

The presence of a cuboidal epithelial lining supported the diagnosis of a neuroepithelial/ependymal cyst [2, 5, 8]. This histopathological feature, combined with the intraoperative findings of a thin-walled, translucent, free-floating cyst and the cerebrospinal fluid-like magnetic resonance imaging signal, was highly characteristic of this entity [2, 5, 8]. The absence of goblet cells, mucinous epithelium, or a muscularis mucosae layer argued against enterogenous or neurenteric cysts [3, 9–11], while the lack of keratinous debris or fat excluded epidermoid and dermoid cysts [12]. Immunohistochemical staining was not available in the present case; therefore, the diagnosis was based on conventional histopathology and intraoperative and radiological findings.

2.5 Postoperative Course

The patient had an uneventful postoperative recovery. He was discharged in stable condition. At follow-up, the parents reported that the child no longer demonstrated avoidance of walking and had returned to normal ambulation. Neurological examination revealed normal muscle strength and tone in the lower extremities. No complications such as wound infection, cerebrospinal fluid leakage, or neurological deterioration were observed.

3. Literature Review

A focused search of the English-language literature was conducted using PubMed, Google Scholar, and Web of Science databases. Search terms included "free-floating intraspinal cyst," "mobile spinal cyst," "migrating spinal cyst," "neuroepithelial cyst," "enterogenous cyst," "arachnoid cyst," and "mobile spinal tumor" [2–7]. Cases were included when serial imaging, positional imaging, intraoperative observation, or author description supported mobility or a free-floating nature. Because the published literature is sparse and heterogeneous, Table 1 summarizes representative reported cases rather than an exhaustive catalogue of all mobile spinal lesions.

Table 1
Representative reported cases of mobile or free-floating intraspinal cystic lesions and cystic-appearing tumors in the literature.

Author, Year	Age/Sex	Location	Preoperative Symptoms	Pathology	Treatment	Outcome	Follow-up
Bapat et al., 2012 [2]	41/F	Lumbar (L1-L2/3)	Acute low back pain with bilateral lower limb radiculopathy	Neuroepithelial cyst	Complete excision	Symptom resolution	Not reported
Kojima et al., 2016 [3]	2 year 2 mo/M	Lumbar (L1-L3→T12-L1→L3-L4)	Intermittent paraplegia; unable to walk after coughing; language delay	Enterogenous cyst	Complete excision	No further paraplegia episodes	35 mo, no recurrence
Hyman et al., 1986 [4]	69 year / F	Cauda equina	Tonic-clonic seizures, lethargy, transient loss of consciousness, nuchal rigidity, flaccid severely paretic lower extremities	Cysticercosis (tapeworm cysts)	Medical/surgical	Progressively more alert; did not regain use of lower limbs	Not reported
Mastorakos et al., 2020 [5]	65 year/M	Lumbar (filum terminale)	Low back pain, lower extremity weakness	Myxopapillary ependymoma + filum ependymal cyst	Complete excision	Symptom resolution	Not reported
Hamabe et al., 2019 [6]	48 year/F	Spinal canal	dysuria and right leg pain	Schwannoma (completely cystic)	Complete excision	Symptom improvement after surgery	Not reported
Ghalaenovi & Fattahi, 2018 [7]	60 year/M	Lumbar cauda equina (L1/2 disc → posterior to L3 body → posterior to L2 body)	Left buttock and posterior thigh pain for 2 years, exacerbated at night; muscle spasm	Schwannoma (intradural extramedullary)	L1–L3 laminectomy; en bloc resection with sacrifice of involved nerve rootlet; L2/3 disc removal	Asymptomatic	3 mo
Present case, 2026	22 mo/M	Lower lumbar→L3-L5	Avoidance of walking (3 months), progressively worsening; no pain or tenderness	Neuroepithelial cyst	Complete excision + filum terminale sectioning	Normal ambulation; normal strength/tone	Early follow-up

4. Discussion

The present case represents a rare example of a free-floating intraspinal neuroepithelial cyst in an infant. To our knowledge, this is among the youngest reported patients with a mobile intraspinal cystic lesion and may represent the youngest reported free-floating intraspinal neuroepithelial cyst [2–5]. The following discussion focuses on the differential diagnosis, the unique pathophysiology of cyst mobility, and the importance of preoperative imaging in confirming cyst location.

4.1 Differential Diagnosis

The differential diagnosis of intraspinal cystic lesions includes several entities that can be distinguished based on clinical, radiological, and histopathological features [1–13]. Enterogenous and neurenteric cysts commonly occur in the cervical or thoracic spine, often in a ventral location, and may be associated with vertebral anomalies; histologically, they are characterized by cuboidal or columnar epithelium with gastrointestinal or respiratory differentiation, and may contain goblet cells, mucinous epithelium, cilia, or smooth-muscle elements [3, 9–11]. Complete surgical excision is generally preferred when feasible, although adherence to neural structures can limit resection and influence recurrence risk [9, 10]. Arachnoid cysts are lined by arachnoid membrane rather than true epithelium and typically show cerebrospinal fluid-isointense signal on magnetic resonance imaging [1]. Epidermoid and dermoid cysts are distinguished by squamous epithelial lining, keratinous debris, and/or fat-containing components [12]. In the present case, the lumbar intradural location, pure cerebrospinal fluid-like signal, intraoperative observation of a thin-walled translucent free-floating cyst without adhesions, and histopathological confirmation of a cuboidal epithelial lining without goblet cells, mucinous epithelium, muscularis mucosae, keratinous debris, or fat supported a neuroepithelial/ependymal cyst [2, 5, 8].

4.2 Mechanism of Cyst Mobility

The mobility of intraspinal cystic lesions is a rare and poorly understood phenomenon [2, 3]. Several mechanisms have been proposed. First, cysts with smooth, non-adherent walls may float freely within the subarachnoid space, drifting with cerebrospinal fluid pulsations, postural changes, or gravitational forces [2]. Second, cysts that have undergone repeated rupture and resealing may develop a slippery outer surface that prevents adhesion to surrounding structures [3]. Third, changes in cyst size or cerebrospinal fluid dynamics may facilitate movement; in tumor-associated cases, lesion mobility may also be indirect evidence of an adjacent occult cyst [5]. In our case, the cyst was completely free of adhesions to the spinal cord, nerve roots, or dura, which allowed it to be removed intact with gentle traction. The thin, translucent wall suggested a long-standing lesion with minimal inflammatory reaction [2, 5, 8].

4.3 Clinical Implications

Free-floating intraspinal cystic lesions pose unique diagnostic challenges [2, 3]. Their intermittent or positional symptoms may be mistaken for functional disorders, musculoskeletal problems, or transient neurological events [3]. In infants and toddlers, the presentation is particularly subtle, as seen in our case, where avoidance of walking was the sole symptom for three months. Magnetic resonance imaging is the diagnostic modality of choice, typically demonstrating a well-circumscribed, cerebrospinal fluid-isointense intradural lesion without enhancement [1, 2]. However, the mobile nature of these cysts may result in variable appearance on serial imaging, as demonstrated by Kojima et al. [3], in whom the cyst migrated from L1-L3 to T12-L1 and then to L3-L4 between episodes. Repeat, dynamic, or positional magnetic resonance imaging may be helpful in suspected cases [3]. Surgical treatment involves complete microsurgical excision whenever possible. The free-floating nature of these cysts often facilitates en bloc removal, as the lack of adhesions minimizes risk of injury to neural structures [2, 3]. In our case, the combination of cyst excision and filum terminale sectioning addressed both the compressive lesion and the thickened filum terminale, resulting in complete resolution of symptoms.

It is therefore important to obtain repeat preoperative MRI as close to the surgical date as possible to confirm the current cyst location and avoid inaccurate surgical level localization [3]. In the present case, the documented change in cyst location between the outside hospital MRI and our preoperative MRI (obtained approximately one week apart) provided compelling radiological evidence of mobility and allowed precise localization to the L3-L5 level, enabling targeted laminectomy and complete excision without unnecessary extension of the surgical exposure.

5. Conclusion

We report a rare case of a free-floating intraspinal neuroepithelial cyst in a 22-month-old boy presenting with avoidance of walking. The change in cyst location between the outside hospital MRI and preoperative MRI, obtained approximately one week apart, provided evidence of the cyst's mobile nature and underscored the importance of repeat preoperative imaging to confirm current cyst location prior to surgical intervention. The diagnosis was supported by characteristic magnetic resonance imaging findings and confirmed by the intraoperative observation of a mobile, pedicle-free cyst and histopathological evidence of a cuboidal epithelial lining [2, 5, 8].

Complete microsurgical excision of the cyst combined with filum terminale transection resulted in complete resolution of symptoms. Our focused review identified representative published cases of mobile or migrating intraspinal cystic lesions and cystic-appearing tumors, highlighting the exceptional rarity and heterogeneity of this condition [2–7]. The free-floating nature of these cysts, while rare, may facilitate complete surgical excision and excellent functional recovery [2, 3]. This case underscores the importance of considering mobile intraspinal cystic lesions in the differential diagnosis of young children with subtle gait abnormalities, even in the absence of classic signs of spinal cord compression [2, 3].

Declarations

Ethics approval and consent to participate: Not applicable.

Consent for publication: Written informed consent was obtained from the patient's parents for publication of this case report and any accompanying images.

Availability of data and materials: All data generated or analyzed during this study are included in this published article.

Competing interests: The authors declare that they have no competing interests.

Funding: No funding was received for this study.

Authors' contributions: Yang Bo performed the surgery and supervised the case. Sun Lianping, Song Yunhai and Bao Nan supervised the case. Gao Pingping and Wang Fengting participated in the surgical procedure and drafted the manuscript. All authors reviewed and approved the final manuscript.

References

1. Wilkins RH, Odom GL. Spinal intradural cysts. In: Vinken PJ, Bruyn GW, editors. Handbook of Clinical Neurology. New York: North Holland; 1976:55–102.
2. Bapat MR, Ansari MHSA, Paknikar KP, Rathi PC, Patel CS. Free floating, intraspinal, neuroepithelial cyst: A case report. Int J Case Rep Images. 2012;3(6):38–41. doi:10.5348/ijcri-2012-06-136-CR-9
3. Kojima S, Yoshimura J, Takao T, et al. Mobile spinal enterogenous cyst resulting in intermittent paraplegia in a child: case report. J Neurosurg Pediatr. 2016;18(4):448–451. doi:10.3171/2016.4.PEDS15666
4. Hyman AD, Gray CE, Lanzieri C, Belman AS. Tapeworm cysts of the cauda equina. AJNR Am J Neuroradiol. 1986;7(5):977–978.
5. Mastorakos P, Pomeraniec IJ, Shah S, Shoushtarizadeh A, Quezado MM, Heiss J. Mobile myxopapillary ependymoma with associated filum terminale cyst. World Neurosurg. 2020;139:337–342. doi:10.1016/j.wneu.2020.04.095
6. Hamabe F, Soga S, Imabayashi H, Matsunaga A, Shinmoto H. Mobile spinal schwannoma with a completely cystic appearance. Am J Case Rep. 2019;20:859–863.
7. Ghalaenovi H, Fattahi A. Migrating spinal intradural schwannoma with adjacent disc herniation: A case report and brief literature review. Surg Neurol Int. 2018;9:228. doi:10.4103/sni.sni_284_18
8. Wackym PA, Feuerman T, Gade GF, Dubrow TJ. Ependymal cyst of the spinal cord presenting with acute paraplegia. J Neurol Neurosurg Psychiatry. 1988;51(6):885. doi:10.1136/jnnp.51.6.885
9. Menezes AH, Traynelis VC. Spinal neurenteric cysts in the magnetic resonance imaging era. Neurosurgery. 2006;58(1):97–105.
10. Buddappa S, et al. Isolated Intramedullary Spinal Neurenteric Cysts: Case Report and Literature Review. Asian J Neurosurg. 2025;20(2):408–412.
11. Liu CX, Meng B, Li YB, Bai H, Wu ZX. A rare case of thoracic spinal intradural extramedullary enterogenous cyst with acute onset: case report and literature review. Ann R Coll Surg Engl. 2019;101(6):e142-e146.
12. Roux A, Mercier C, Larbrisseau A, Dube LJ, Dupuis C, Del Carpio R. Intramedullary epidermoid cysts of the spinal cord. Case report. J Neurosurg. 1992;76:528–533.
13. Chavhan GB, Shroff MM. Twenty classic signs in neuroradiology: a pictorial essay. Indian J Radiol Imaging. 2009;19(2):135–145.

Figures

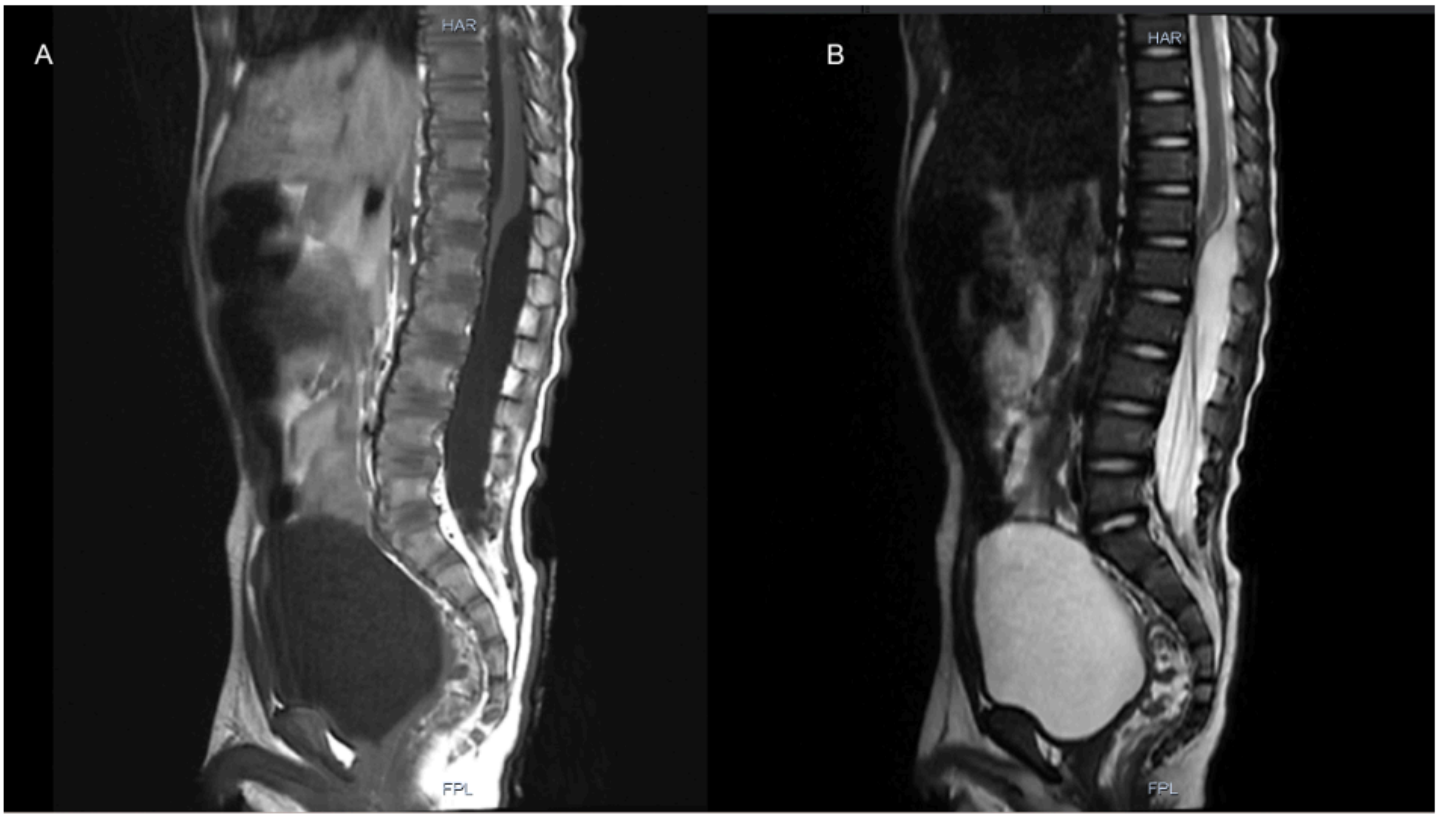

Figure 1

Sagittal T1- (A) and T2- (B) weighted MRI obtained at an outside hospital demonstrating a intraspinal cystic lesion in the lower lumbar region.

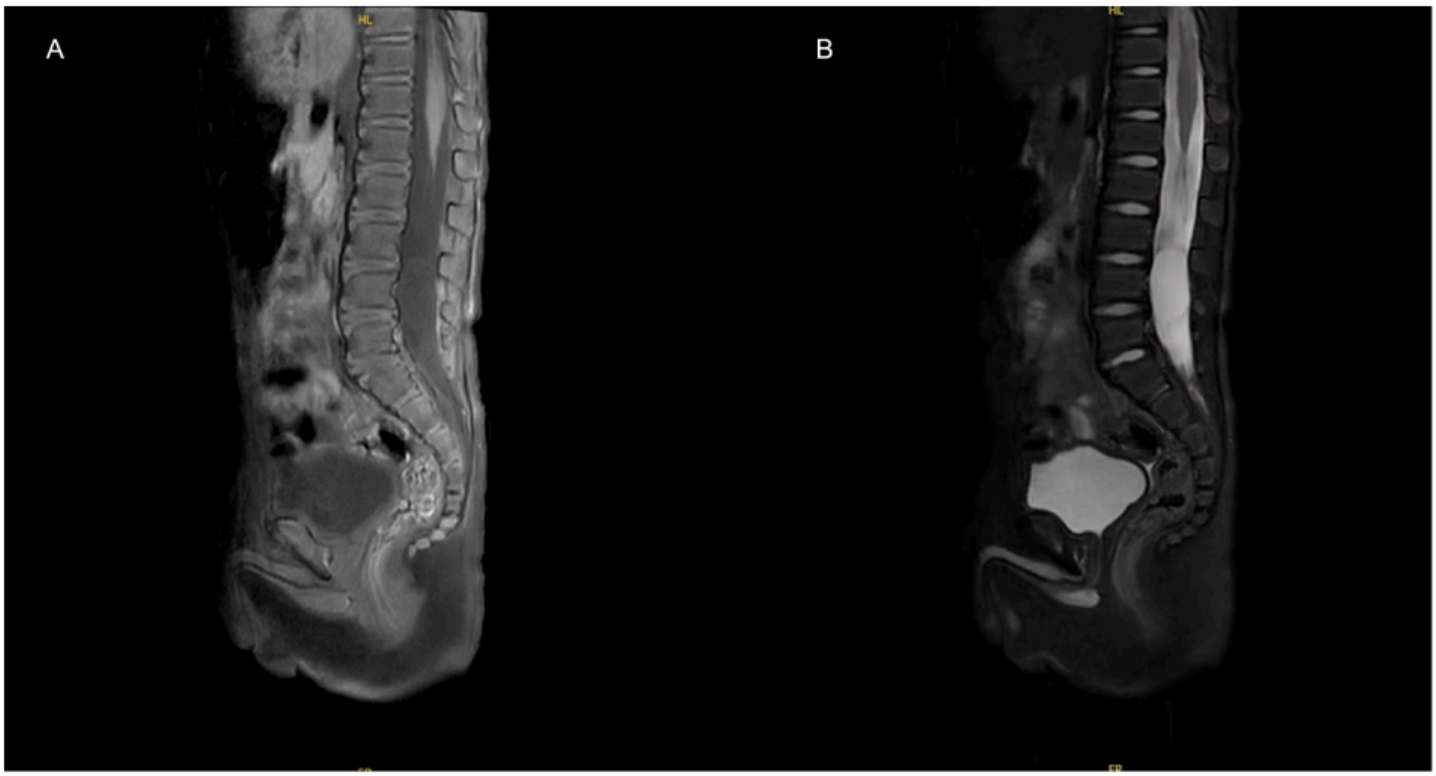

Figure 2

Preoperative sagittal T1-weighted (A) and T2-weighted (B) MRI from our institution showing the cystic lesion now localized to the L2-L3 level.

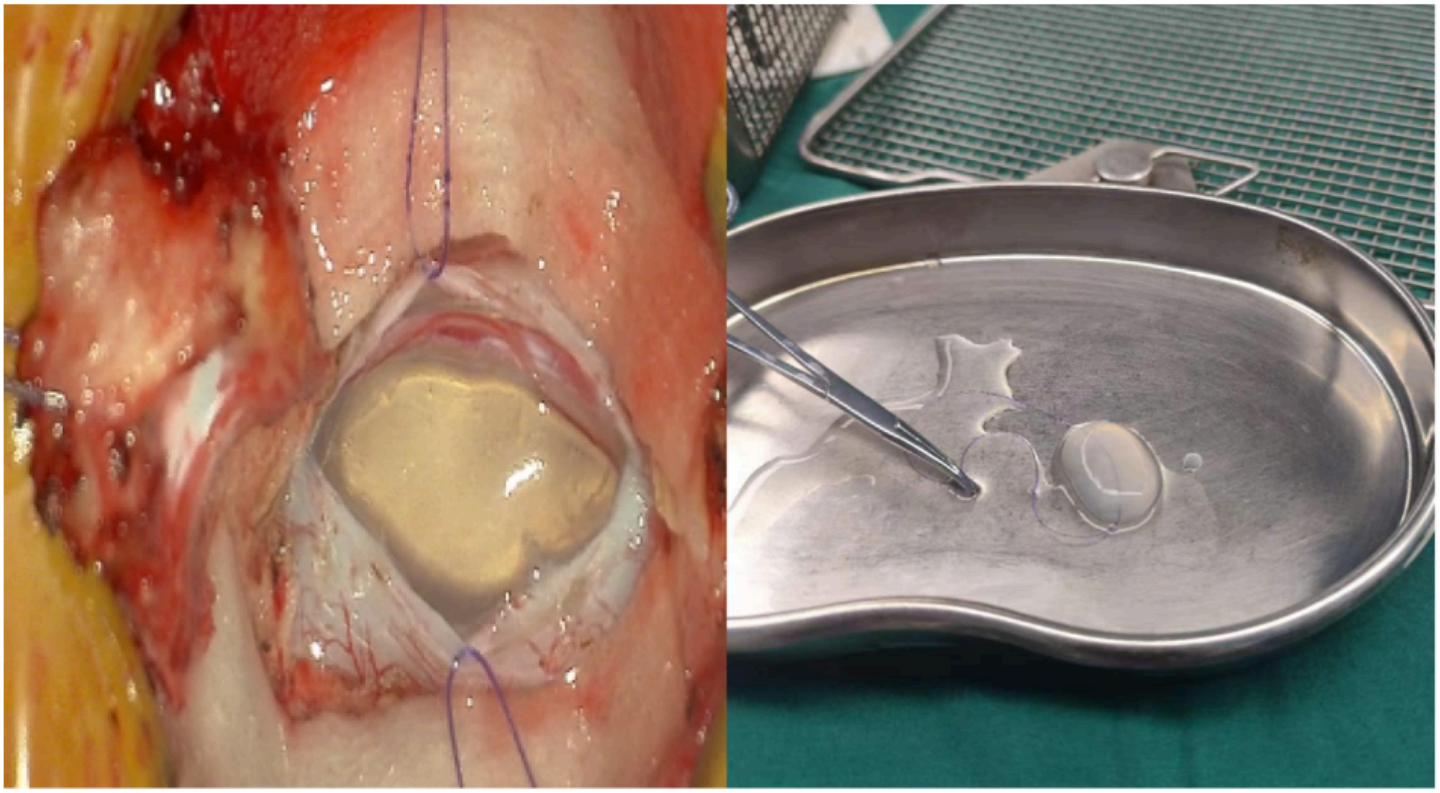

Figure 3

Intraoperative photograph showing the thin-walled, translucent cyst floating within the subarachnoid space after dural opening.

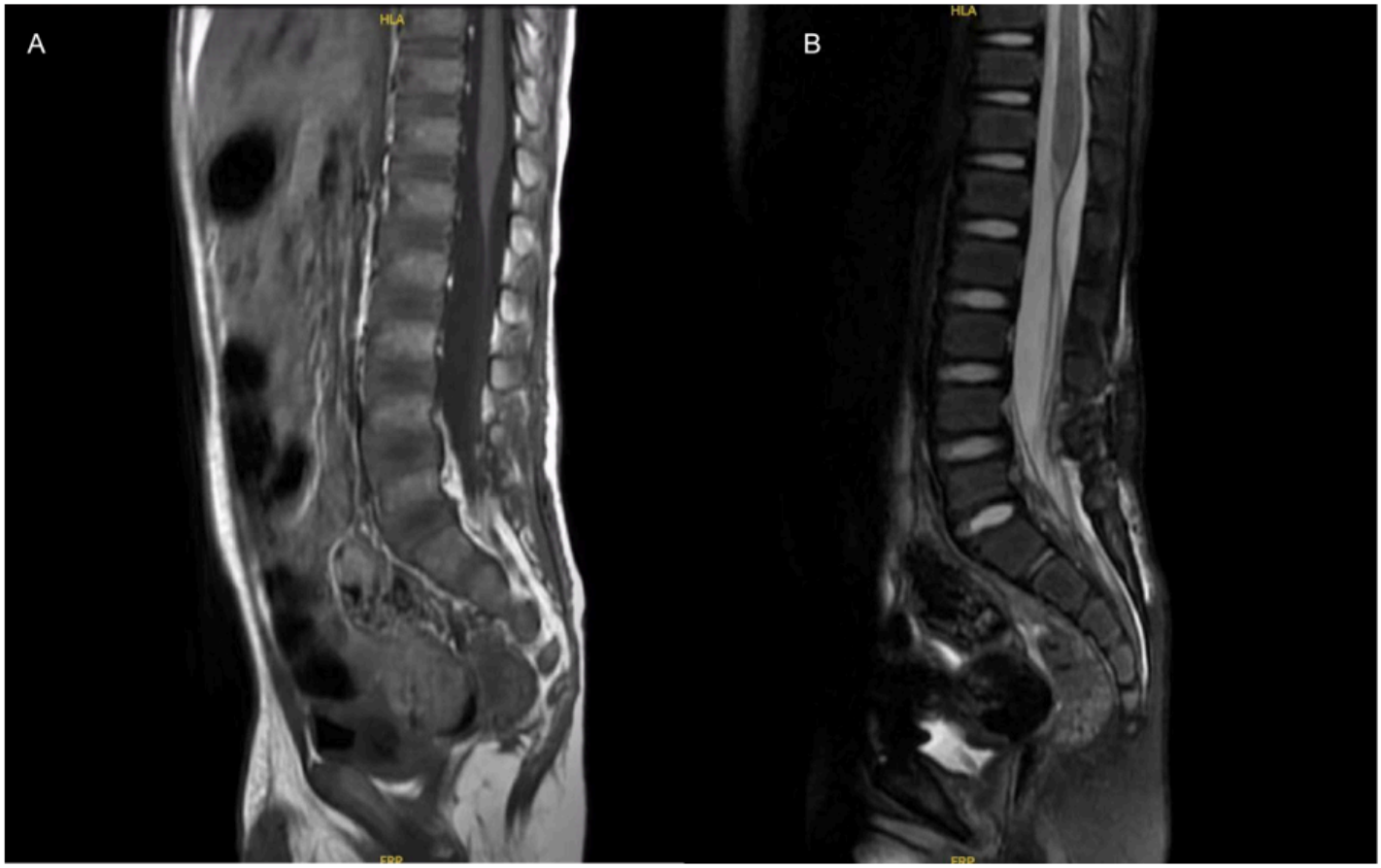

Figure 4

Postoperative sagittal T1-weighted (A) and T2-weighted (B) MRI showing complete resection of the cystic lesion.