Research Square

Preprints are preliminary reports that have not undergone peer review.
They should not be considered conclusive, used to inform clinical practice,
or referenced by the media as validated information.

Papillary renal neoplasm with reversed polarity in the setting of ipsilateral malformation

Jiandong Zhang
Chinese PLA General Hospital
Xiaohui Ding
Chinese PLA General Hospital
Tengyu Weng
The Third Medical Center of Chinese PLA General Hospital
Hao Gong
Chinese PLA General Hospital
Wei Wang
Beijing Chao-Yang Hospital Affiliated Capital Medical University
Liangyou Gu
guliangyouyd1@126.com
Chinese PLA General Hospital

Case Report

Keywords: ipsilateral malformation, PRNRP, VEN, breast hypoplasia

Posted Date: September 24th, 2026

DOI: https://doi.org/10.21203/rs.3.rs-10804753/v1

License: This work is licensed under a Creative Commons Attribution 4.0 International License.
Read Full License

Additional Declarations: No competing interests reported.

Abstract

Ipsilateral developmental malformations affecting the extremity skin, breast and kidney are rare, and their coexistence with renal neoplasms is extremely uncommon. We herein describe a patient presenting with a right renal tumour accompanied by ipsilateral verrucous epidermal nevus and breast hypoplasia. Regrettably, the patient received multiple physical examinations and three surgical procedures over 35 years, yet renal evaluation was neglected throughout all workups, resulting in delayed identification of renal developmental defects and concurrent malignancy. This article firstly summarizes syndromes characterized by ipsilateral developmental malformations involving cutaneous, mammary and renal tissues to facilitate recognition of such disorders. We then systematically introduce papillary renal neoplasm with reversed polarity (PRNRP) confirmed by this case, a newly categorized renal tumour subtype, including its incidence, diagnosis, treatment and prognosis. Four clinical challenges and three core clinical takeaways encountered during the patient's management are further summarized. By presenting this rare case, summarizing knowledge of ipsilateral developmental anomalies, elaborating on PRNRP and sharing our clinical experience, we aim to raise clinicians' awareness of ipsilateral malformations, emphasize thorough history taking and physical examination, value past medical history, and advocate comprehensive multi-organ evaluation to optimize patient care.

Case Report

A 35-year-old woman presented with a primary complaint of incidental finding of a solid mass during physical examination for the past 1 month at Senior Department of Urology in Chinese PLA General Hospital, Beijing, China, in December, 2025. Her medical history was notable for congenital ipsilateral verrucous epidermal nevus(VEN) extending from the right lumbar region to the foot and ipsilateral breast hypoplasia(**figure A, B**), and three prior surgical procedures performed in 2012, 2018, and 2023 for VEN, childbirth, and vocal polyp, respectively. To clarify the nature of the right renal mass, the patient underwent a series of examinations, including urinary tract ultrasonography, contrast-enhanced renal ultrasonography, contrast-enhanced urinary tract CT(**figure C**), renal magnetic resonance imaging, and PET/CT. These imaging indicated: 1) A right renal mass with suspected malignant potential; 2) Multiple right renal cysts including complex cysts classified as Bosniak IIF and peripelvic renal cysts. Nevertheless, the nature of right renal mass could not be definite. Further evaluation on above images revealed right renal insufficiency based on morphological abnormalities and absent contrast agent excretion. Further split renal function testing confirmed nearly non-function of the right kidney. Accordingly, laparoscopic radical right nephrectomy was performed(**figure D**). Subsequently, multiple postoperative pathological examinations ultimately confirmed the lesion as papillary renal neoplasm with reversed polarity (PRNRP) supported by typical histopathological morphology, immunohistochemical profiling, and KRAS missense mutations, which exhibits low malignant potential with low risks of recurrence and metastasis[5,6]. Therefore, regular surveillance alone was recommended without adjuvant therapy. Half-year postoperative follow-up showed normal renal function and no evidence of tumor recurrence or distant metastasis.

Figure: Clinical and radiological images

(A) Photographs of the hypoplastic right breast and verrucous epidermal nevus(VEN). (B) Photograph of VEN of the right lower limb. (C) CT demonstrating right renal mass with multiple cysts. (D) Gross section view of the resected right nephrectomy specimen. Yellow arrow indicates hypoplastic breast, red arrows indicate VEN, and blue arrows indicate dysplastic right kidney. R: right.

Ipsilateral malformation

The ipsilateral co-occurrence of cutaneous, mammary, and renal malformations is extremely rare, and progression of the renal lesion to an tumor renders this presentation even more uncommon. We herein describe a patient presenting with a right renal tumour accompanied by ipsilateral verrucous epidermal nevus and breast hypoplasia. This case does not satisfy the diagnostic criteria for any of the nine well-defined or seven incompletely characterized epidermal nevus syndromes reported in prior literature[1,2]. To our knowledge, no previous studies have documented this specific triple-organ malformation phenotype. We propose this case represents an intermediate phenotype of these syndromes[3], which likely form a disease spectrum explained by embryonic mosaicism. Differences in mutant gene dosage and embryonic mutation timing lead to diverse mosaic patterns and distinct postnatal clinical manifestations. These conditions share six core features as follows: 1、Uniform time window: All occur during organogenesis (4–9 week), when limb buds, mammary primordia, urogenital ridges, and skin differentiate synchronously. 2、Uniform spatial distribution: Strictly ipsilateral, along Blaschko's lines, with clear midline demarcation. 3、Uniform germ layer origin: Involvement of the surface ectoderm, intermediate mesoderm, and neural crest cells (homologous to epidermis, mammary stroma, renal interstitium, and limb connective tissue). 4、Uniform pathway dysregulation: High-frequency involvement of the RAS/MAPK, Wnt/Hedgehog, and TBX pathways. 5、Uniform pathogenesis: Somatic mosaicism (X-inactivation mosaicism/early embryonic clonal mosaicism) as the core mechanism underlying unilateral multi-organ synchronous malformations. 6、Treatment、Treatment is mainly symptomatic, and gene-based therapies are currently under investigation[4].

PRNRP

First officially classified in 2019, PRNRP represents a low-grade subtype of papillary renal cell carcinoma (PRCC), comprising 4.0%–8.6% of PRCC and 0.49% of all renal neoplasms[7]. As a rare renal epithelial tumor, it lacks specific clinical manifestations and presents no distinct gender predominance, mainly affecting middle-aged and elderly populations. The majority of PRNRP lesions are detected incidentally as solitary, well-circumscribed renal masses or complex renal cysts during routine imaging examinations, while symptomatic cases with lumbago or hematuria are extremely rare, making it clinically indistinguishable from other conventional renal cell carcinomas.

The definitive diagnosis of PRNRP depends on the combination of typical histopathological morphology, immunohistochemical (IHC) profiling, and molecular genetic testing[4]. The most pathognomonic

histological feature is reversed nuclear polarity, characterized by apical localization of tumor cell nuclei away from the basement membrane. Immunophenotypically, PRNRP exhibits diffuse positivity for GATA3 and L1CAM and consistent negativity for vimentin and p504s, which differentiates it from other PRCC subtypes. Genetically, recurrent somatic KRAS missense mutations primarily occurring at codon 12 serve as the hallmark molecular signature of PRNRP.

Surgical resection is the mainstream treatment for localized PRNRP. Nephron-sparing partial nephrectomy is the preferred approach, whereas radical nephrectomy is reserved for tumors with large volume or complicated by severe irreversible renal dysfunction. Postoperative adjuvant therapy is generally not required. PRNRP confers an excellent long-term prognosis due to its inherent indolent biological behavior, low nuclear grade, small tumor size, and early T-stage presentation. Our institutional cohort data further support this favorable prognosis: a total of 15 PRNRP patients were enrolled with a median follow-up of 41.3 months[4]. Most cases exhibited no tumor recurrence or disease progression after surgery, with only one patient developing local recurrence at 1 year postoperatively. Although the overall recurrence risk is considerably low, such individual cases remind clinicians that adverse prognostic events may still occur, necessitating regular long-term postoperative surveillance for all PRNRP patients.

Lesson From this case: four challenges and three reminders

Four major clinical challenges were encountered in this patient's diagnosis and treatment: preoperative diagnosis, preoperative decision-making, definitive postoperative diagnosis, and postoperative treatment strategy. Firstly, excessive preoperative investigations were potentially performed for preoperative diagnosis. KRAS mutation represents a hallmark feature of PRNRP and also serves as a key molecular characteristic of VEN. Failure to recognize the medical history linked to KRAS mutations led to unnecessary redundant examinations. Secondly, preoperative decision-making(surveillance or surgical intervention) was highly challenging due to undetermined nature of the renal mass. Thirdly, definitive postoperative diagnosis was time-consuming. The patient underwent three sequential pathological examinations lasting 35 days, including routine histopathology, supplementary immunohistochemistry and next-generation sequencing genetic testing. Integrating the patient's history of VEN associated with KRAS mutations enables timely targeted testing, thus shortening the diagnostic interval. Fourthly, optimal postoperative management was initially unclear. After systematic literature review on PRNRP, we confirmed that this rare neoplasm generally confers a favourable prognosis. Active surveillance is currently the most reasonable management strategy.

Three key clinical takeaways are summarized: recognizing the diagnostic value of past medical history, evaluating comprehensively malformations, and updating continuously medical knowledge. First, PRNRP, a newly classified subtype of PRCC defined in 2019, requires clinicians to maintain updated medical knowledge to master its typical features, therapeutic strategies and prognostic profiles for optimal patient care. Second, developmental malformations frequently involve multiple organs synchronously, mandating full systemic assessment to formulate individualized treatment plans. For instance, this

patient received routine physical examinations and three surgical procedures prior to PRNRP diagnosis, yet renal evaluation was overlooked throughout these workups, resulting in irreversible complete renal dysfunction at detection. Last but not least, full attention should be paid to historical information for diagnosis. Early recognition of the molecular link between KRAS mutations, VEN and PRNRP would have greatly simplified preoperative diagnosis, surgical decision-making, postoperative pathological confirmation and long-term surveillance for both clinicians and patients.

By reporting the diagnostic and therapeutic challenges encountered in this rare case, we aim to raise clinicians' awareness of PRNRP and ipsilateral developmental malformations. We also advocate sustained professional learning, adequate emphasis on historical medical clues during clinical workup, and standardized multi-organ screening, all of which contribute to improved clinical management for similar patients.

Declarations

Clinical trial number

not applicable.

This was a retrospective observational report. Written informed consent was obtained from the patient, who agreed and consented to the use of her clinical data and images for publication.

Consent for publication

All authors have reviewed and approved the manuscript for publication.

Competing interests

We declare no competing interests.

Funding

Not applicable.

Author Contribution

Jiandong Zhang (writing the original draft); Xiaohui Ding (equal contribution, pathology resources, validation); Tengyu Weng (equal contribution, dermatology resources, validation); Hao Gong (review); Wei Wang (conceptualisation, review and editing); Liangyou Gu (supervision, review and editing, correspondence). All authors read and approved the final manuscript. Written informed consent for publication was obtained from the patient.

References

1. Rudolf H. The group of epidermal nevus syndromes Part I. Well defined phenotypes[. J] J Am Acad Dermatol. 2010;63:1–22. quiz 23 – 4.
2. Rudolf H. The group of epidermal nevus syndromes Part II. Less well defined phenotypes[. J] J Am Acad Dermatol. 2010;63:25–30. quiz 31 – 2.
3. Yu J, Wei L, Shilin D, et al. Flumethasone-salicylic acid cream effectively flattened verrucous epidermal nevus: a case report[. J] J Dermatolog Treat. 2025;37:2603129.
4. Xingyuan Jiang MY, Jeng Z, Yang et al. De Novo Germline L858R EGFR Variants and Generalized Acanthosis Nigricans.[J].JAMA Dermatol, 2026, 162: 236–44.
5. Tao Wang X, Ding X, Huang et al. Papillary renal neoplasm with reverse polarity-a comparative study with CCPRCC, OPRCC, and PRCC1.[J].Hum Pathol, 2022, 129: 60–70.
6. Lee YI, Park JM, Yoon SY, et al. Papillary renal neoplasm with reverse polarity shows benign behavior: Results from a 77-case clinicopathological and molecular study. [J]. Ann Diagn Pathol. 2026;80:152498.
7. Kwon JW, Wang P, Wanjari P, et al. Renal Tumorigenesis via RAS/RAF/MAPK Pathway Alterations Beyond Papillary Renal Neoplasm With Reverse Polarity.[J]. Am J Surg Pathol. 2025;49:1266–78.

Figures

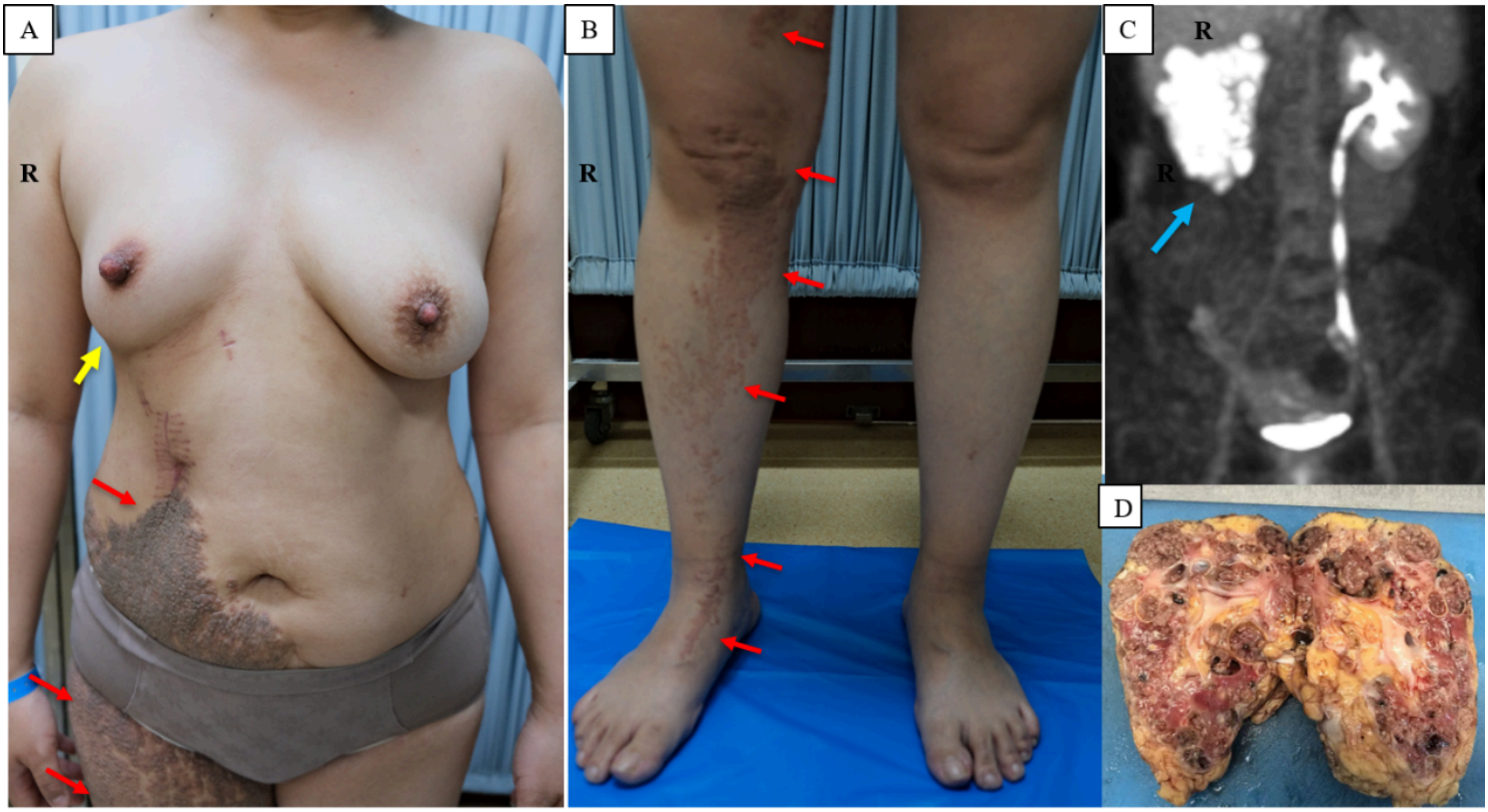

Figure 1

Clinical and radiological images

(A) Photographs of the hypoplastic right breast and verrucous epidermal nevus(VEN). (B) Photograph of VEN of the right lower limb. (C) CT demonstrating right renal mass with multiple cysts. (D) Gross section view of the resected right nephrectomy specimen. Yellow arrow indicates hypoplastic breast, red arrows indicate VEN, and blue arrows indicate dysplastic right kidney. R: right.