Research Square

Preprints are preliminary reports that have not undergone peer review.
They should not be considered conclusive, used to inform clinical practice,
or referenced by the media as validated information.

Left Ventricular Air Embolism and Cardiac Arrest following Percutaneous Needle Biopsy of a Pulmonary Nodule: A Case Report

Samuel P. Massion

samuel.massion@ucsf.edu

University of California San Francisco

Alexander J. Beagle

University of California San Francisco

James A. Frank

University of California San Francisco

Case Report

Keywords: Air embolism, cardiac arrest, image-guided biopsy, peripheral lung nodules, Biopsy, Needle / adverse effects, case report

Posted Date: November 1st, 2026

DOI: https://doi.org/10.21203/rs.3.rs-10781711/v1

License: This work is licensed under a Creative Commons Attribution 4.0 International License.
Read Full License

Additional Declarations: No competing interests reported.

Abstract

Background

Left ventricular air embolism is a rare yet potentially fatal complication of percutaneous lung needle biopsies. They can precipitate cardiac arrest when air enters the pulmonary veins and obstructs forward blood flow through the left ventricle. We report a case in which intraprocedural imaging enabled recognition of left-sided intracardiac air during cardiac arrest and highlight management strategies that contributed to successful resuscitation.

Case Presentation:

A 78-year-old man underwent an elective computed tomographic (CT)-guided biopsy of a left upper lobe lung nodule. After core biopsy was obtained, he complained of sudden-onset chest pain followed by unresponsiveness and loss of palpable pulses. Cardiopulmonary resuscitation was initiated following Advanced Cardiac Life Support guidelines. Intraprocedural CT imaging revealed an air embolism within the left ventricular apex without involvement of the right heart or pulmonary circulation. The patient was placed in a modified right lateral decubitus and Trendelenburg position utilizing hospital bed wedges and an automatic mechanical chest compression device. The trachea was intubated, and he was ventilated with 100% FiO2. Hyperbaric oxygen facilities were unavailable. He was resuscitated with interval resolution of intracardiac air and discharged three weeks later.

Conclusion

Physicians should maintain a high index of suspicion for left ventricular air embolism as a potential cause of cardiac arrest after percutaneous lung biopsy. Prompt recognition, supplemental oxygen therapy, and standard resuscitation measures remain the mainstay of treatment for hemodynamic collapse due to air embolism. Future study is needed to define optimal positional management based on the site of air embolism; venous versus arterial, or right versus left heart chambers.

Background

Air embolism is a rare but potentially severe complication of any medical procedure involving vascular access, in which air enters the venous or arterial circulation (1). For percutaneous transthoracic lung biopsies, the pooled incidence of symptomatic systemic air embolism is approximately 0.08%. While rare and usually asymptomatic, up to one-third of symptomatic cases result in sequelae or death (2). They carry significant risk of further complications due to obstruction of blood flow in systemic or coronary circulation, potentially leading to myocardial infarction, arrhythmias, stroke, or cardiac arrest (3). Left ventricular (LV) air embolism is a particularly dangerous variant of this complication and associated with a higher risk of unfavorable outcomes. The 2025 American Heart Association (AHA) guidelines include

the first dedicated section on gas embolism resuscitation (4), however evidence-based recommendations specific to LV air embolism and in the context of cardiac arrest remain limited. We present a case of cardiac arrest after percutaneous lung biopsy, in which intraprocedural imaging enabled prompt recognition of left-sided intracardiac air and guided resuscitative management.

Case Presentation

A 78-year-old man with a history of compensated alcohol-associated cirrhosis and prior tobacco use presented for an elective CT-guided biopsy of a pulmonary nodule concerning for malignancy. He was referred for this biopsy after a CT scan during a prior hospitalization had incidentally revealed a 1.5 cm mixed solid and ground glass nodule in the left upper lobe. He underwent preoperative screening without any contraindications to this procedure.

The procedure was performed under local anesthesia with the patient in a supine position. Under CT guidance, a 19-gauge, 6 cm coaxial needle was inserted into the edge of the lesion (Fig. 1). Two fine needle aspirates were obtained with 20-gauge Chiba needles, and a single core biopsy was obtained. After core biopsy was obtained, the patient complained of acute, severe chest pain and rapidly became unresponsive without a palpable pulse. Procedural electrocardiographic monitors showed sinus rhythm, consistent with cardiac arrest due to pulseless electrical activity. Cardiopulmonary resuscitation (CPR) was initiated immediately following Advanced Cardiac Life Support (ACLS) guidelines.

Review of the CT imaging revealed a 2.2 cm x 1.0 cm air embolism within the LV apex (Fig. 2). There was no evidence of air in the right heart or pulmonary circulation. The patient was immediately placed in a combined right lateral decubitus and Trendelenburg position. Hospital bed wedges and a rigid board were utilized to maintain this position while adequate compressions were delivered by a mechanical chest compression device. Endotracheal intubation was performed and mechanical ventilation initiated with 100% fraction of inspired oxygen (FiO2). Hyperbaric oxygen facilities were unavailable. In addition to the air embolus, point of care ultrasound indicated a partial left sided pneumothorax, and needle decompression was performed without significant immediate clinical effect. Point of care blood gas analysis did not reveal any major abnormalities including pH, electrolytes, and hemoglobin. No other obvious causes for his arrest were identified during the resuscitation or afterward. An arterial line was placed for invasive hemodynamic monitoring, and a femoral central venous catheter was placed for administration of intravenous fluids, vasopressors, and additional medications.

Sustained return of spontaneous circulation (ROSC) was achieved after approximately one hour of resuscitation following ACLS protocols. The patient was then transferred to the Intensive Care Unit. The patient regained consciousness with his mental status intact and without any neurological deficits compared to his baseline. The following day, repeat CT scan demonstrated complete resolution of the intracardiac free air. Transthoracic echocardiogram did not reveal a patent foramen ovale. He recovered well and was discharged three weeks later without any significant sequela.

Discussion

LV air embolism is a very rare but potentially severe complication from CT-guided percutaneous lung needle biopsies. The more common complications related to this procedure are 1) pneumothorax and 2) pulmonary hemorrhage (5, 6). The reported incidence of air embolism from CT-guided lung biopsies ranges from 0.02–0.40% (7–9), and the left ventricle is the most detected site of air embolism during these procedures (10). The actual incidence of air embolus as a complication may be higher due to potential underreporting of asymptomatic cases. Moreover, the morbidity and mortality rate for symptomatic cases is significant, with a systematic review demonstrating one-third of patients with symptomatic air embolism after percutaneous transthoracic lung biopsy suffered sequela or death (2).

The proposed mechanism for developing an air embolism in this case is direct introduction of air into the pulmonary vein through a hollow biopsy needle. Air can thereby travel via the pulmonary venous circulation into the left sided heart chambers. In addition to direct entrainment, as the needle traverses the lung parenchyma tract formations can form between airways and vasculature, known as bronchovenous fistulas. Factors that increase the risk of air embolism during a lung biopsy include lesion location near vasculature, in the lower lobes, or above the level of the left atrium; prone patient positioning; greater needle penetration depth into the tumor; and obtaining multiple biopsy samples (7). Positioning the patient with the lesion in an ipsilateral dependent position—below the level of the left atrium—theoretically lowers the risk of air embolism, as the resulting increase in pulmonary venous pressure relative to alveolar pressure raises the pressure gradient that air must overcome to enter the vasculature. (11). In this case, the target lesion was above the level of the left atrium during the procedure, which may have increased the risk of air entrainment into the vasculature.

There are very few reported cases of a LV air embolism after CT-guided lung biopsy causing cardiac arrest and successfully resuscitated (12, 13). This patient's positive outcome highlights several key aspects in managing such cases. Prompt radiologic recognition was critical in identifying the etiology of this patient’s cardiac arrest and in delineating the precise location and extent of the embolism. In this case, CT images obtained during the biopsy procedure revealed the diagnosis of left ventricular air embolism. Radiologists play a key role by carefully evaluating images for intravascular air in the left sided heart chambers, as well as for needle tip positioning near pulmonary vasculature. Given pneumothorax and pulmonary hemorrhage are more common complications, clinicians leading resuscitative efforts must maintain a high index of suspicion for air embolism to avoid prematurely attributing cardiac arrest to alternative causes such as tension pneumothorax. Once air embolism is suspected or confirmed, supportive therapies should be administered immediately with consideration of positioning the patient to prevent further embolization.

Oxygenation with 100% fraction of inspired oxygen (FiO2) was used in this case and is a key principle in the management of air embolism; Class I (strong) and Level C-EO (Expert Opinion) recommendation by the 2025 AHA guidelines for adults and children with life threatening gas embolism (4). High FiO2 accelerates bubble size reduction by enhancing nitrogen reabsorption from the embolism, while

improving tissue oxygenation and minimizing ischemia (14). In severe cases, hyperbaric oxygen therapy can be a useful adjunct, where patients breathe 100% oxygen at significantly higher pressures than atmospheric pressure in a pressurized chamber (15); the benefit is most evident when administered early, within six hours of symptom onset (16). Hyperbaric oxygen therapy was not available in this case, and specialized centers that offer this intervention must weigh the potential benefits with risks of transferring the patient.

The physiologically rational positioning strategy for LV air embolism includes the right lateral decubitus and Trendelenburg positions, allowing air to migrate away from the outflow tract toward the LV apex (14). This prevents air from obstructing the LV outflow tract or migrating toward the coronary arteries and systemic circulation. Some studies recommend a patient with arterial air embolism should be placed in the supine position (17). Since arterial blood flow is more forceful than venous, air bubbles may still be propelled forward despite patient being in a Trendelenburg or head down position. Trendelenburg position also has the potential of exacerbating cerebral edema that is typically induced by cerebral air embolism. In contrast, right-sided air embolism is often managed with the patient in the left lateral decubitus position, also known as Durant's maneuver, to trap air toward the right atrium and prevent obstruction or entry into the main pulmonary artery (18). Nonetheless, the superiority of lateral body positioning to supine positioning with any air embolism, venous or arterial, has not been extensively investigated. These practices are primarily informed by case reports, case series, retrospective studies, and clinical judgment. The 2025 AHA guidelines for gas embolism highlight the supine or recovery position on a level surface as reasonable positions for patients with life threatening gas embolism; Class 2a (moderate) and Level B-NR (nonrandomized) recommendation (4). In our case, the use of hospital bed wedges was an effective method for maintaining targeted positioning, while a mechanical chest compression device continually delivered high-quality chest compressions in such a position. In the absence of specialized medical equipment, manual CPR should likely be delivered with the patient in the supine position to ensure effective chest compressions. Positioning must not complicate or distract from primary resuscitation efforts.

Conclusion

Left ventricular air embolism should be considered in the differential diagnosis for cardiac arrest during or immediately after percutaneous lung biopsy. Review of intraprocedural imaging is important to identify and locate any intracardiac air, distinguishing between left and right sided heart chambers. In this case of cardiac arrest and left ventricular air embolism following percutaneous lung biopsy, resuscitation via ACLS protocols was supplemented by right lateral decubitus and Trendelenburg position intended to relieve left ventricular outflow tract obstruction. Furthermore, an automatic mechanical chest compression device was used to maintain uninterrupted compressions during repositioning with hospital bed wedges. While associated with a favorable outcome, contribution of the specific positional measures cannot be established with a single case. Ideal positional management based on the site of embolism remains unclear and future study is needed to clarify whether positional interventions confer any measurable benefit for this rare but life-threatening complication.

Abbreviations

LV
Left ventricular
CT
Computed tomography
ACLS
Advanced cardiovascular life support
ICU
Intensive care unit
FIO2
Fraction of inspiring oxygen
ROSC
Return of spontaneous circulation
AHA
American Heart Association
EO
Expert Opinion
NR
Nonrandomized

Declarations

Ethics Statement

No ethical approval was required due to the nature of the manuscript.

Consent

Written informed consent was obtained from the patient's family for publication of this case report and accompanying images. A copy of the written consent is available for review by the editor-in-chief of this journal on request.

Conflicts of interest

The authors declare no conflicts of interest.

Funding

The authors declare there are no sources of funding for this case report.

Author Contribution

S.M. conducted the literature search, wrote the main manuscript text, and prepared figures 1-3. All authors reviewed, revised, and approved the manuscript.

Acknowledgments

No third-party services were involved, and no AI software has been used to create the manuscript.

Data Availability Statement

Data sharing not applicable to this article as no datasets were generated or analyzed during the current study.

References

1. McCarthy CJ, Behravesh S, Naidu SG, Oklu R. Air Embolism: Diagnosis, Clinical Management and Outcomes. Diagnostics (Basel). 2017;7(1).
2. Lee JH, Yoon SH, Hong H, Rho JY, Goo JM. Incidence, risk factors, and prognostic indicators of symptomatic air embolism after percutaneous transthoracic lung biopsy: a systematic review and pooled analysis. Eur Radiol. 2021;31(4):2022–33.
3. Lang D, Reinelt V, Horner A, Akbari K, Fellner F, Lichtenberger P, et al. Complications of CT-guided transthoracic lung biopsy: A short report on current literature and a case of systemic air embolism. Wien Klin Wochenschr. 2018;130(7–8):288–92.
4. Cao D, Arens AM, Chow SL, Easter SR, Hoffman RS, Lagina AT, 3rd, et al. Part 10: Adult and Pediatric Special Circumstances of Resuscitation: 2025 American Heart Association Guidelines for Cardiopulmonary Resuscitation and Emergency Cardiovascular Care. Circulation. 2025;152(16_suppl_2):S578-S672.
5. Lee SM, Park CM, Lee KH, Bahn YE, Kim JI, Goo JM. C-arm cone-beam CT-guided percutaneous transthoracic needle biopsy of lung nodules: clinical experience in 1108 patients. Radiology. 2014;271(1):291–300.
6. Wiener RS, Schwartz LM, Woloshin S, Welch HG. Population-based risk for complications after transthoracic needle lung biopsy of a pulmonary nodule: an analysis of discharge records. Ann Intern Med. 2011;155(3):137–44.
7. Freund MC, Petersen J, Goder KC, Bunse T, Wiedermann F, Glodny B. Systemic air embolism during percutaneous core needle biopsy of the lung: frequency and risk factors. BMC Pulm Med. 2012;12:2.
8. Galvis JM, Nunley DR, Zheyi T, Dinglasan LAV. Left ventricle and systemic air embolism after percutaneous lung biopsy. Respir Med Case Rep. 2017;22:206–8.

9. Ishii H, Hiraki T, Gobara H, Fujiwara H, Mimura H, Yasui K, et al. Risk factors for systemic air embolism as a complication of percutaneous CT-guided lung biopsy: multicenter case-control study. Cardiovasc Intervent Radiol. 2014;37(5):1312–20.
10. Liu SH, Fu Q, Yu HL, Yang Q, Hu YB, Zhang ZX, et al. A retrospective analysis of the risk factors associated with systemic air embolism following percutaneous lung biopsy. Exp Ther Med. 2020;19(1):347–52.
11. Glodny B, Schonherr E, Freund MC, Haslauer M, Petersen J, Loizides A, et al. Measures to Prevent Air Embolism in Transthoracic Biopsy of the Lung. AJR Am J Roentgenol. 2017;208(5):W184-W91.
12. Rahman ZU, Murtaza G, Pourmorteza M, El Minaoui WK, Sethi P, Mamdouhi P, et al. Cardiac Arrest as a Consequence of Air Embolism: A Case Report and Literature Review. Case Rep Med. 2016;2016:8236845.
13. Viqas Z, Yar A, Yaseen M, Khalid M. Cardiac Arrest Due to Air Embolism: Complicating Image-guided Lung Biopsy. Cureus. 2018;10(9):e3295.
14. Mirski MA, Lele AV, Fitzsimmons L, Toung TJ. Diagnosis and treatment of vascular air embolism. Anesthesiology. 2007;106(1):164–77.
15. Ohashi S, Endoh H, Honda T, Komura N, Satoh K. Cerebral air embolism complicating percutaneous thin-needle biopsy of the lung: complete neurological recovery after hyperbaric oxygen therapy. J Anesth. 2001;15(4):233–6.
16. Blanc P, Boussuges A, Henriette K, Sainty JM, Deleflie M. Iatrogenic cerebral air embolism: importance of an early hyperbaric oxygenation. Intensive Care Med. 2002;28(5):559–63.
17. Jorens PG, Van Marck E, Snoeckx A, Parizel PM. Nonthrombotic pulmonary embolism. Eur Respir J. 2009;34(2):452–74.
18. Lambert MJ, 3rd. Air embolism in central venous catheterization: diagnosis, treatment, and prevention. South Med J. 1982;75(10):1189–91.

Figures



Figure 1

Chest CT scan showing the biopsy needle penetrating the left upper lung nodule



Figure 2

Chest CT scan showing air in the left ventricular apex after core biopsy

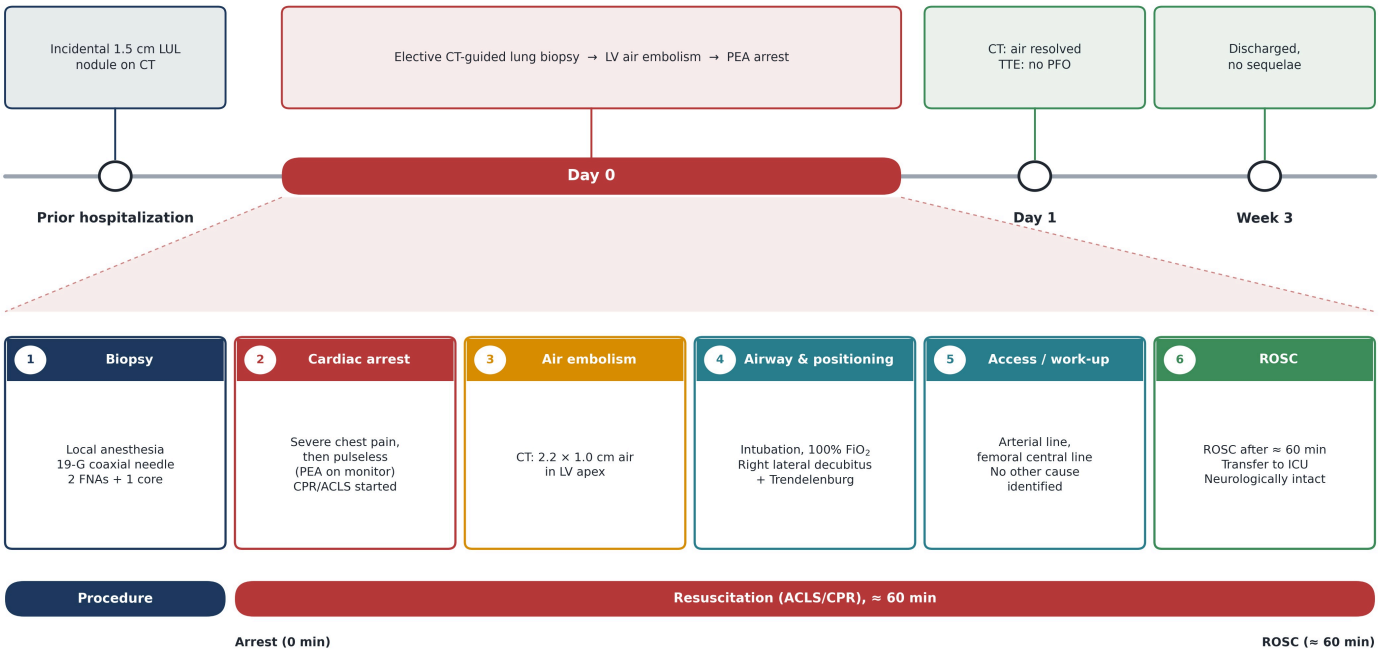

ACLS, advanced cardiac life support; CPR, cardiopulmonary resuscitation; FNA, fine needle aspirate; ICU, intensive care unit; LUL, left upper lobe; LV, left ventricle; PEA, pulseless electrical activity; PFO, patent foramen ovale; ROSC, return of spontaneous circulation; TTE, transthoracic echocardiogram.

Figure 3

Timeline of clinical events