Research Square

Preprints are preliminary reports that have not undergone peer review.
They should not be considered conclusive, used to inform clinical practice,
or referenced by the media as validated information.

Post-infectious anti basement membrane antibody vasculitis

Roua Mankai

roua.mankai@fmt.utm.tn

Mohamed Taher Maamouri University Hospital

Wafa Garbouj

Mohamed Taher Maamouri University Hospital

Salma Dghaies

Mohamed Taher Maamouri University Hospital

Wafa Skouri

Mohamed Taher Maamouri University Hospital

Manel Lajmi

Mohamed Taher Maamouri University Hospital

Haifa Tounsi

Mohamed Taher Maamouri University Hospital

Zaineb Alaya

Mohamed Taher Maamouri University Hospital

Raja Amri

Mohamed Taher Maamouri University Hospital

Case Report

Keywords: Anti glomerular basemant membrane antibody disease, infection and anti GBM, pleuro-pneumopathy

Posted Date: September 10th, 2026

DOI: https://doi.org/10.21203/rs.3.rs-10732106/v1

License: This work is licensed under a Creative Commons Attribution 4.0 International License.
Read Full License

Additional Declarations: No competing interests reported.

Abstract

Background :

Anti-glomerular basement membrane antibody vasculitis is an autoimmune disease belonging to the primary systemic vasculitis of the small vessels, whose pathophysiology incriminates several environmental, toxic and infectious factors.

Case presentation :

We report the case of a 50-year-old male smoker, ethylic, balanced diabetic on diet who was initially hospitalized in the pneumology department for pneumopathy with pyo-pneumothorax treated with drainage and antibiotics. During hospitalization, he developed a rapidly progressive acute renal failure with preserved diuresis (creatinine clearance from 97.8ml/min to 14ml/min in 15 days) with the appearance of an hypereosinophilia at 4600 elements/mm3, the 24-hour proteinuria was zero.

The immunological work-up showed antinuclear antibodies were positive at 1/400 by Indirect Immunofluorescence , anti glomerular basement membrane (anti-GBM) antibodies were positive at 3 crosses by Immunodot and anti neutrophil cytoplasm antibodies were negative.

The clinico-biological evolution was favorable, with normalization of the parameters after the control of the infectious episode. The patient was referred to internal medicine for further investigation. The immunological check-up after 3 months showed a decrease in anti-nuclear antibodies to 1/200 and negativation of the anti- GBM antibodies. The infectious origin of anti-GBM positivity was accepted, and the patient underwent clinical, biological and immunological monitoring with no need for immunosuppressive treatment, given the disappearance of all abnormalities at a distance from the infection.

Conclusion :

Clinicians should remain aware of infection-induced pseudo-Goodpasture presentations to avoid unnecessary immunosuppression and tailor treatment appropriately.

Introduction

Anti-glomerular basement membrane antibody disease (anti GBM) is a rare autoimmune disease with a male preponderance : the first peak is at the age of 30 and the second peak is in the 60s affecting men and women equally (1). It affects the glomerular basement membrane, leading to rapidly progressive glomerulonephritis, and the alveolar membranes, causing intra-alveolar haemorrhage, which defines the pneumo-renal syndrome. We report the case of a patient who presented a post-infectious pneumo-renal syndrome with transient anti-GBM.

Case presentation

This is the case of a 50-year-old male smoker, alcoholic, who has a balanced diabetis on a diet. He was admitted to the pneumology department for a pyo-pneumothorax, with a clinical infectious syndrome and a biological inflammatory syndrome without bacteremia, drained for 1 month and put on probabilistic antibiotic therapy targeting staphylococcus without identification of a germ: 5 days of amoxicillin-clavulanic acid and amikacin followed by 17 days of metronidazole with no improvement and persistent fever. The diagnosis of infective endocarditis was ruled out by transthoracic and transoesophageal ultrasound, both were normal. A thoraco-abdomino-pelvic CT scan was ordered in search of a deep infectious site, showing right upper and lower lobar pulmonary parenchymal condensations associated with a small pleural effusion suggestive of persistent infectious pleuropneumopathy. Antibiotic therapy was changed to vancomycin for 20 days, then to teicoplanin for 14 days in view of the recurrence of several episodes of venitis.

The evolution was marked by the disappearance of fever with lasting apyrexia and C reactive protein negativation. However, rapidly progressive renal failure set in (Fig. 1), with preserved diuresis, negative 24-hour proteinuria, hyper eosinophilia at 2900 rechecked at 2700elements/mm3 and renal ultrasound without abnormalities. There were no extra pulmonary signs.

In view of this pneumo-renal syndrome, an immunological work-up was requested, showing : Anti-nuclear antibodies positive at 1/400 by indirect immunofluorescence, anti GBM positive at 3croix by immunodot, anti proteinase 3 as well as anti myeloperoxidase were negative.

After the infectious episode had been brought under control, he was referred to internal medicine on day 15 of discharge for further investigation. He had no complaints and his physical examination was normal.

Biological tests showed disappearance of the hyper-eosinophilia and normalization of renal function.

An immunological check-up was requested 3 months later: Anti-nuclear antibodies positive at 1/200 with negativation of anti-GBM antibodies.

The infectious origin of this pseudo-Good-Pasture's syndrome was retained, and the course of action was therapeutic abstinence and monitoring.

Discussion

The importance of this observation lies in highlighting the role of environmental factors in triggering anti GBM disease, including tobacco (1). Pesticides may also play a direct role in triggering the disease (2).

According to the literature, iatrogenicity is incriminated, but the pathophysiology is still poorly elucidated concerning the role of drugs in disrupting autoimmune processes. Immunotherapy was incriminated in the case of a patient with melanoma and pulmonary metastases who developed anti-GBM vasculitis after treatment with checkpoint inhibitors. Probably, the podocyte and glomerular damage induced by the treatment, which is known to be nephrotoxic, led to the unmasking of cryptic antigens, loss of self-

tolerance and autoimmunity (3). The role of Covid 19 vaccination was noted in one case. The type of vaccine was not specified, and the patient received her 2nd dose 14 days before the onset of symptoms. The diagnosis of anti-GBM vasculitis was confirmed on renal biopsy, and anti-GBM antibodies were negative (4).

The hypothesis of an association between upper respiratory tract infections and pulmonary infections has been put forward by several teams, with the latter modifying capillary permeability, inducing local inflammatory lesions and possibly altering the structure of the basement membrane.

Infectious episodes, especially viral ones, have been incriminated in triggering relapses of underlying Good Pasture disease, notably cytomegalovirus and Covid 19. Several cases have been reported in the literature. Cytomegalovirus-Covid19 co-infection was described in one case (5).

They are involved in triggering the inflammatory cascade, being the primum movens of the onset of the disease with a chronic course. Such cases have been encountered with covid19 during the pandemic, when the evolution of the disease led to an indication for immunosuppressive drugs (6, 7).

The particularity of our observation also lies in the spontaneously favorable evolution of our case without recourse to specialized treatments. Anti-GBM was considered a false positive in a case of anti-MBG vasculitis secondary to heptavirus infection (1).

Bacterial infectious factors have also been incriminated, as demonstrated by an observation of a 72-year-old man who developed anti-GBM vasculitis during staphylococcal aureus osteomyelitis. The course was comparable to our patient's, spontaneously favorable after control of the infectious episode by antibiotic therapy (8).

Clinically, during the course of anti-GBM vasculitis, renal involvement is almost constant. It is characterized by rapidly progressive glomerulonephritis leading to acute renal failure, non-nephrotic proteinuria and hematuria. Pulmonary involvement is present in 40–60% of cases, in the form of intra-alveolar haemorrhage showing a pulmonary infiltrate on chest CT (9).

The initial creatinine level is a predictive factor of prognosis: if it's below 500µmol/liter, the one-year survival rate is 100%, and the rate of recovery of renal function is 95%, especially if the patient has not required hemodialysis sessions (10), as in our patient's case.

The prognosis of anti-GBM disease has been revolutionized by the simultaneous use of corticosteroids, cytostatic agents and plasma exchange. This treatment leads to a rapid reduction, in less than two months, in the level of anti-GBM antibodies, which then disappear from the circulation (11). However, the role played by infectious agents in certain cases, and the possibility of spontaneous remission once the infection has been controlled, make the use of corticosteroids and immunosuppressants an aggravating factor, since they lead to immunodepression, enabling the infectious agent to remain in the body and the autoimmune process to persist.

Conclusion

The presenatition of an infection-associated anti-GBM syndrome as a pneumo-renal syndrome is rare. It underscores the potential role of environmental and infectious factors in unmasking autoimmunity and suggests that careful evaluation of the underlying cause may allow for conservative management in selected cases. Clinicians should remain aware of infection-induced pseudo-Goodpasture presentations to avoid unnecessary immunosuppression and tailor treatment appropriately.

Abbreviations

Anti GBM : anti glomerular basement membran antibody

Declarations

Author Contribution

I would like to express my deepest gratitude to all the authors mentioned in the contribution of this article. Author WG designed the study. Author MR wrote the first draft of the manuscript and did the modifications recommended by the journal in every step of the publication. Authors SD, SW , ZA , HTand LM managed the littérature. Author RA validated the final version. All authors read and approved the final manuscript.

***The authors report no conflicts of interest*

References

1. Zijlstra H, Mulder A, Geeraedts F, Visser F (2018) Falsely positive anti-glomerular basement membrane antibodies in a patient with hantavirus induced acute kidney injury - a case report. BMC Nephrol 19(1):286
2. Marques C, Plaisier E, Cacoub P, Cadranel J, Saadoun D (2020) Mise au point sur la maladie des anticorps anti-membrane basale glomérulaire ou syndrome de Goodpasture. La Revue de Médecine Interne. Jan 41(1):14–20
3. Periklas K, Abhinav T (2021) Atypical anti-glomerular basement membrane glomerulonephritis in a patient with metastatic melanoma treated with mitogen-activated protein kinase and immune checkpoint inhibitors: a case report. J Med Case Rep. ;15(1)
4. Nagai K, Iwase M, Ueda A (2022 Mai) A case of anti-GBM nephritis following centipede bites and COVID-19 vaccination. CEN Case Rep 11(2):166–170
5. Winkler A, Zitt E, Sprenger-Mähr H, Soleiman A, Cejna M, Lhotta K (2021) SARS-CoV-2 infection and recurrence of anti-glomerular basement disease: a case report. BMC Nephrol 22(1):75
6. Bouzidi M, Kefi A, Khelili R, Hajji M, Dardou G, Abdelghani KB et al (2022) Vascularite à anticorps anti-membrane basale glomérulaire secondaire au Covid-19: observation inédite ! La Revue De Med

Interne Jui 43:A158

7. Koc NS, Yildirim T, Saglam A, Arici M, Erdem Y (2021) A patient with COVID-19 and anti-glomerular basement membrane disease. Nefrologia (Engl Ed) 41(4):471–473
8. Tomohisa Y, Komei S et al (2021) Atypical anti-glomerular basement membrane disease complicated by methicillin-susceptible Staphylococcus aureus infection-related rapidly progressive glomerulonephritis: a case report and literature review. CEN case Rep. ;10(3)
9. Fai2r Maladie des anticorps anti-membrane basale glomérulaire: Généralités [en ligne]. 2020 [cité 30 oct 2023]. Disponible à l'URL: https://www.fai2r.org/les-pathologies-rares/x-autres-vascularites/la-maladie-des-anticorps-anti-membrane-basale-glomerulaire/generalites/
10. Lingaraj U, Mallappa S, Neminah R, Mohan S, Venkatesh L, Gurusiddaiah S et al (2017) A Mini-Epidemic of anti-glomerular basement membrane disease: Clinical and epidemiological study. Saudi J Kidney Dis Transpl 28(5):1057
11. Carron PL, Heitz M, Gierczak V, Truche A, Mingat N, Sirajedine K et al (2016) Utilisation du rituximab pour le traitement de la maladie des anticorps anti-membrane basale glomérulaire (anti-MBG). Néphrologie & Thérapeutique. Sep 12(5):358–359

Figures

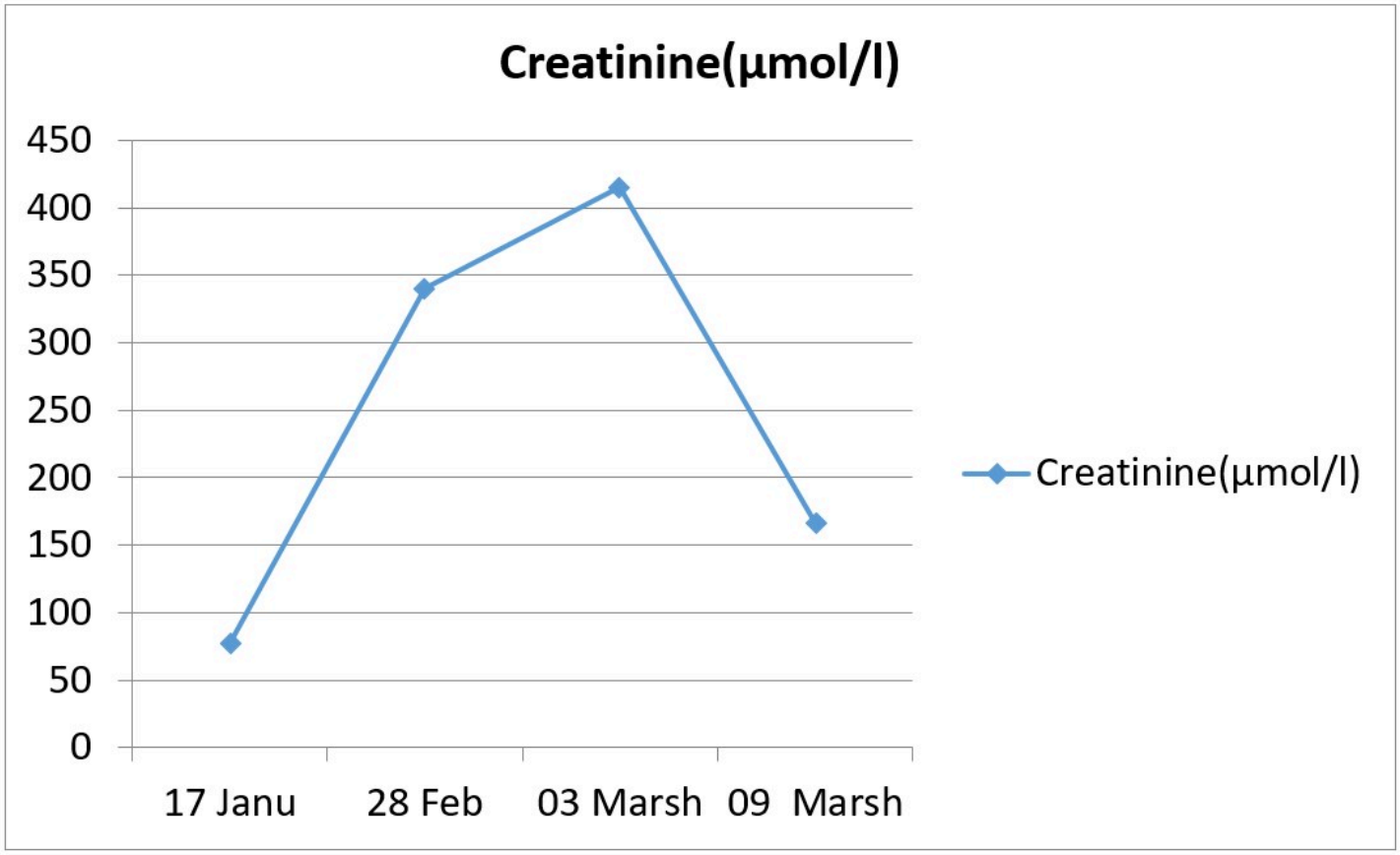

Figure 1

Evolution of renal function over time