Research Square

Preprints are preliminary reports that have not undergone peer review.
They should not be considered conclusive, used to inform clinical practice,
or referenced by the media as validated information.

Posterior Thoracic Dekyphosis and Fusion Versus Posterior Decompression and Fusion in the Treatment for Non-Ambulatory Patients with Multilevel Thoracic Ossification of the Posterior Longitudinal Ligament: A Retrospective Case-control Study

Zixuan Xu
Peking University Third Hospital
Guanghui Chen
Peking University Third Hospital
Yuanyu Hu
Peking University Third Hospital
Shuai Jiang
Peking University Third Hospital
Xinhu Guo
Peking University Third Hospital
Woquan Zhong
Peking University Third Hospital
Weishi Li
Peking University Third Hospital
Feifei Zhou
Peking University Third Hospital
Chuiguo Sun
sunchuiguo@163.com
Peking University Third Hospital

Research Article

Keywords: Multilevel thoracic ossification of the posterior longitudinal ligament, surgical strategy, dekyphosis, circumferential decompression

Posted Date: September 8th, 2026

DOI: https://doi.org/10.21203/rs.3.rs-10692380/v1

License: This work is licensed under a Creative Commons Attribution 4.0 International License.
Read Full License

Additional Declarations: No competing interests reported.

Abstract

Background

Multilevel thoracic ossification of the posterior longitudinal ligament (m-TOPLL) is frequently associated with severe neurological impairment and poor postoperative recovery. Posterior decompression and fusion (PDF) is the traditional operation strategy. Thoracic posterior dekyphosis and fusion (TPDF) has recently been introduced as an alternative surgical strategy for severe m-TOPLL. However, the advantages and disadvantages of between TPDF and PDF have not yet been compared. This study aimed to compare the clinical outcomes of TPDF and PDF in non-ambulatory patients with m-TOPLL.

Methods

A retrospective study was conducted involving patients who underwent surgical treatment for m-TOPLL at a single institution between 2015 and 2023. Patients were matched according to preoperative neurological status and thoracic kyphosis angle (TK). Demographic characteristics, radiographic parameters and surgical outcomes were compared between the TPDF and PDF groups.

Results

No significant differences were observed between the two groups regarding demographic characteristics and radiographic parameters. Compared with the PDF group, the TPDF group demonstrated significantly greater postoperative improvement in lower-extremity motor function (3 (2) vs. 1 (3), P = 0.017) and a superior mJOA recovery rate (72.5% ± 18.5% vs. 59.6% ± 23.2%, P = 0.034). However, postoperative cerebrospinal fluid leakage (CSFL) occurred more frequently in the PTDF group (20/25 vs. 13/25, P = 0.037).

Conclusion

TPDF provides superior neurological recovery compared with conventional PDF in non-ambulatory patients with severe m-TOPLL. Although TPDF is associated with a higher incidence of CSFL, operative duration and blood loss can be maintained within acceptable ranges when performed by experienced surgical teams.

Introduction

Thoracic ossification of the posterior longitudinal ligament (TOPLL) is a relatively uncommon but challenging cause of thoracic spinal stenosis[1]. Conservative management is generally ineffective in symptomatic patients, and progressive neurological deterioration often necessitates surgical intervention. Owing to the anterior location of the ossified lesion relative to the spinal cord and the

physiological thoracic kyphosis, surgical treatment is technically demanding and frequently associated with unsatisfactory neurological recovery[2–4].

Posterior decompression and fusion (PDF), the most commonly performed indirect decompression procedure, achieves decompression through posterior laminectomy without directly addressing ventral spinal cord compression caused by the ossified posterior longitudinal ligament. Although PDF is technically less demanding and associated with a relatively lower risk of catastrophic neurological injury, its decompressive efficacy may be limited in patients with severe ventral compression, particularly in those with multilevel disease[5, 6].In contrast, direct decompression procedures, including anterior or circumferential resection of the ossified lesion, provide more complete ventral decompression of the spinal cord. Nevertheless, these procedures are technically challenging and carry substantial risks[7]. And the surgical difficulty increases further in patients with multilevel thoracic ossification of the posterior longitudinal ligament (m-TOPLL) [8–10].

To overcome the limitations of conventional surgical strategies for m-TOPLL, thoracic posterior dekyphosis and fusion (TPDF) was proposed, a novel surgical technique that combines posterior laminectomy, limited circumferential decompression, and thoracic kyphosis correction[11]. This technique aims to reduce ventral spinal cord compression and longitudinal spinal cord tension while avoiding severe complications associated with extensive anterior thoracic approaches. In addition, controlled spinal shortening achieved during thoracic dekyphosis may improve spinal cord perfusion and facilitate neurological recovery.

However, the comparative advantages and disadvantages of TPDF relative to conventional PDF have not yet been comprehensively evaluated. Therefore, the present study aimed to compare the surgical outcomes of TPDF and PDF in non-ambulatory m-TOPLL patients with comparable baseline neurological and sagittal alignment characteristics.

Materials and Methods

Study Design and Patient Selection

This retrospective matched cohort study included patients who underwent surgical treatment for multilevel thoracic ossification of the posterior longitudinal ligament (m-TOPLL) at a single tertiary spine center between January 2015 and December 2023. The study was conducted in accordance with the Declaration of Helsinki and was approved by the institutional ethics committee.

Patients were eligible for inclusion if they met the following criteria: (1) radiologically confirmed thoracic OPLL involving more than three vertebral segments; (2) severe thoracic myelopathy resulting in non-ambulatory status before surgery; and (3) a minimum postoperative follow-up duration of 24 months. Exclusion criteria included: (1) concomitant thoracic spinal disorders, including spinal fracture, tumor, severe thoracic disc herniation, spinal deformity, or severe ossification of the ligamentum flavum; (2) neurological disorders affecting functional assessment, such as cerebral infarction with severe sequelae

or syringomyelia; and (3) other systemic diseases potentially influencing neurological evaluation, including peripheral neuropathy, severe lower-extremity arterial disease, or severe urological dysfunction.

To minimize baseline differences in neurological status and sagittal alignment between the two groups, patients were matched according to the preoperative modified Japanese Orthopaedic Association (mJOA) score and thoracic kyphosis (TK) angle, given the importance of kyphosis correction in the PTDF strategy. Ultimately, 25 patients were included in each surgical group.

Data Collection

Baseline demographic data included age, sex, body mass index (BMI), duration of symptoms, and duration of non-ambulatory status before surgery. Operation related variables included operative duration, intraoperative blood loss, and postoperative complications, including cerebrospinal fluid leakage (CSFL), transient neurological deterioration, epidural hematoma, surgical site infection, and wound dehiscence.

Radiographic evaluation was performed using computed tomography (CT) and magnetic resonance imaging (MRI). Imaging parameters included:

1. Thoracic region affected by OPLL, categorized as upper thoracic (T1–5), middle thoracic (T5–9), or lower thoracic (T9–L1);
2. Morphological classification of OPLL at the most severely compressed segment as either beak-type or flat-type;
3. Spinal canal occupying ratio, defined as the ratio of the ossified mass area to the spinal canal area at the most severely affected level;
4. Thoracic kyphosis (TK) angle (T1–12 Cobb angle) and fusion-segment kyphosis (FSK) angle (Cobb angle between the cranial and caudal vertebrae of the fused segments), measured on sagittal CT images; and
5. Presence of intramedullary high-intensity areas (HIA) on T2-weighted MRI.

Neurological function was assessed using the mJOA scoring system for thoracic myelopathy. Postoperative neurological recovery was evaluated at the final follow-up, which was performed at least 24 months after surgery. The mJOA recovery rate was calculated using the following formula: [(postoperative mJOA score – preoperative mJOA score) / (11 – preoperative mJOA score)] × 100%. The primary outcome is final follow-up mJOA recovery rate, and secondary outcomes include postoperative lower-extremity motor score and postoperative complications.

Surgical Techniques

Posterior Decompression and Fusion

The surgical levels were identified fluoroscopically using a C-arm imaging system. A standard posterior midline approach was used to expose the laminae and facet joints. Bilateral pedicle screws were inserted at the planned fusion levels. Longitudinal troughs were created along the medial margins of the bilateral facet joints to separate the posterior spinal canal wall from the lateral elements. The laminae were carefully elevated, and adhesions between the dura mater and ossified structures were meticulously released. En bloc laminectomy was then performed to achieve posterior decompression. Finally, appropriately contoured titanium rods were connected to the pedicle screws to complete posterior stabilization and fusion. (Fig. 1).

Posterior Thoracic Dekyphosis and Fusion

The TPDF procedure was performed through the same posterior midline approach. Following pedicle screw insertion and en bloc laminectomy, circumferential decompression was performed at the apex of the thoracic kyphosis using the “IV + V + VI” decompression technique to partially resect the ventral ossified posterior longitudinal ligament[12]. Autologous bone grafting was performed at the circumferential decompression level. Controlled thoracic dekyphosis and limited spinal shortening were subsequently achieved through posterior compression along the instrumentation construct, allowing closure of the posterior vertebral column at the decompression level. This maneuver aimed to reduce longitudinal tension on the thoracic spinal cord and increase the distance between the spinal cord and ventral ossified lesion. (Fig. 2).

Statistical Analysis

Statistical analyses were performed using SPSS software version 25.0. Continuous variables with normal distribution were expressed as mean ± standard deviation and compared using the independent-samples t test. Non-normally distributed variables were presented as median with interquartile range and analyzed using the Wilcoxon rank-sum test. Categorical variables were analyzed using the chi-square test or Fisher’s exact test, as appropriate. All statistical tests were two-sided, and a P value < 0.05 was considered statistically significant.

Results

A total of 50 patients with severe multilevel thoracic ossification of the posterior longitudinal ligament (m-TOPLL) were included in the study, comprising 25 patients in the posterior decompression and fusion (PDF) group and 25 patients in the thoracic posterior dekyphosis and fusion (TPDF) group. Baseline demographic characteristics are summarized in Table 1. No significant differences were observed between the two groups with respect to age, sex distribution, body mass index (BMI), prevalence of diabetes mellitus, duration of symptoms, duration of non-ambulatory status, or preoperative mJOA score (all $P > 0.05$).

Table 1
Comparison of basic data between PDF and TPDF groups

Age		**PDF(n = 25)**	**TPDF(n = 25)**	**P**
		48.6 ± 10.6	**47.8 ± 9.5**	**0.816**
Gender	Male	9	6	1.000
	Female	16	19	
Diabetes mellitus	Yes	2	5	0.415
	No	23	20	
BMI (kg/m²)		30.3(7.3)	29.1(6.1)	0.920
Duration of the medical history (months)		12(32.5)	5.5(9)	0.231
Duration of inability to walk (months)		2(2.5)	1(1.5)	0.215
Preoperative mJOA score		2(1)	2(2)	0.897

Note: PDF: posterior decompression and fusion; TPDF: thoracic posterior dekyphosis and fusion; BMI: body mass index; mJOA: modified Japanese Orthopaedic Association

Radiographic findings are presented in Table 2. The mean number of operated segments did not differ significantly between the PDF and TPDF groups (5.1 ± 2.2 vs. 4.6 ± 2.5, P = 0.557). Similarly, no statistically significant differences were identified regarding the thoracic region affected by OPLL, OPLL morphology, spinal canal occupying ratio, or the presence of intramedullary high-intensity signal on T2-weighted MRI (all P > 0.05). Preoperative sagittal alignment parameters were also comparable between the two groups. The TK angle was 30.7° ± 8.9° in the PDF group and 30.2° ± 7.9° in the TPDF group (P = 0.628), whereas the FSK angle was 20.5° ± 5.2° and 22.5° ± 4.6°, respectively (P = 0.304).

Table 2
Comparison of imaging characteristics between PDF and TPDF groups

Average value of operation segments		**PDF(n = 25)**	**TPDF(n = 25)**	**P**
		5.1 ± 2.2	**4.6 ± 2.5**	**0.557**
Upper thoracic spine		12	18	0.083
Middle thoracic spine		19	23	0.247
Lower thoracic spine		9	8	0.765
Thoracic kyphosis		30.7 ± 8.9	30.2 ± 7.9	0.628
Fusion section kyphosis		20.5 ± 5.2	22.5 ± 4.6	0.304
Spinal canal occupying rate		66.5%±10.9%	64.8%±10.2%	0.356
HIA on MRI	Yes	21	23	0.663
	No	4	2	
Type of OPLL	Flat	12	7	0.145
	Beak	13	18	

Note: PDF: posterior decompression and fusion; TPDF: thoracic posterior dekyphosis and fusion; HIA: high-intensity areas; MRI: magnetic resonance imaging

Perioperative outcomes and postoperative neurological recovery are summarized in Table 3. The mean operative duration per segment was longer in the TPDF group than in the PDF group (32.0 ± 10.4 min vs. 25.6 ± 5.7 min), although the difference did not reach statistical significance (P = 0.078). Similarly, mean intraoperative blood loss per segment was greater in the TPDF group (102.8 ± 38.7 mL vs. 71.9 ± 33.1 mL), without a statistically significant difference between groups (P = 0.533). The incidence of postoperative cerebrospinal fluid leakage (CSFL) was significantly higher in the TPDF group than in the PDF group (20/25 vs. 13/25, P = 0.037). However, no significant differences were observed between the two groups regarding transient neurological deterioration or other major postoperative complications, including epidural hematoma, surgical site infection, and wound-related complications. Patients treated with TPDF demonstrated significantly better postoperative lower-extremity motor function scores compared with those treated with PDF (3 (2) vs. 1 (3), P = 0.017). In addition, the TPDF group achieved a significantly greater mJOA recovery rate than the PDF group (72.5% ± 18.5% vs. 59.6% ± 23.2%, P = 0.034).

Table 3
Comparison of data related to operation and prognosis between PDF and TPDF groups

Operation duration of per segment (min)		**PDF(n = 25)**	**TPDF(n = 25)**	**P**
		25.6 ± 5.7	**32.0 ± 10.4**	**0.078**
Blood loss of per segment (ml)		71.9 ± 33.1	102.8 ± 38.7	0.533
CSFL	Yes	13	20	0.037
	No	12	5	
Transient neurological deterioration	Yes	6	7	0.747
	No	19	18	
Epidural hematoma	Yes	1	1	1.000
	No	24	24	
Postoperative mJOA -lower limb motor function score		1(3)	3(2)	0.017
RR		59.6%±23.2%	72.5%±18.5%	0.034

Note: PDF: posterior decompression and fusion; TPDF: thoracic posterior dekyphosis and fusion; mJOA: modified Japanese Orthopaedic Association; CSFL: cerebrospinal fluid leakage; RR: recovery rate

Discussion

Multilevel thoracic ossification of the posterior longitudinal ligament remains one of the most challenging spinal disorders to manage surgically because of the anatomical and biomechanical characteristics of the thoracic spine. In the present study, we compared the clinical outcomes of TPDF and conventional PDF in non-ambulatory patients with severe m-TOPLL. The principal finding of this matched retrospective cohort was that PTDF was associated with greater neurological recovery than conventional PDF in selected non-ambulatory patients with severe m-TOPLL, as reflected by higher postoperative lower-extremity motor function (3 (2) vs. 1 (3), P = 0.017) and mJOA recovery rate (72.5% ± 18.5% vs. 59.6% ± 23.2%, P = 0.034). This neurological benefit was accompanied by a higher incidence of CSFL.

Posterior decompression and fusion is currently one of the most widely adopted surgical strategies for thoracic OPLL because of its technical simplicity and relatively lower risk of catastrophic spinal cord injury. Nevertheless, the mechanism of decompression achieved by PDF is indirect and relies primarily on posterior migration of the spinal cord after laminectomy. In patients with severe ventral compression and physiological thoracic kyphosis, posterior spinal cord shift is often limited, resulting in insufficient decompression of the ventral spinal cord. Consequently, neurological recovery after conventional PDF may remain suboptimal, particularly in patients with m-TOPLL, with recovery rate from 40%-60%[5, 6, 13].

In 2008, Professor Kawahara N proposed a method for m-TOPLL involving anterior resection of OPLL combined with posterior reduction of thoracic kyphosis to reduce spinal cord tension[14]. However, because the anterior transthoracic approach causes substantial trauma[5, 15], a new surgical strategy – TPDF was proposed[11]. This research showed that TPDF significantly improved the prognosis of m-TOPLL patients, but the specific advantages and disadvantages of TPDF technique compared with conventional PDF have remained unclear.

Preoperative mJOA score has been shown to influence postoperative neurological recovery in patients with thoracic spinal stenosis [16]. Therefore, we carefully matched patients in the two groups to ensure comparability regarding this variable. In addition, because TPDF involves modification of TK and FSK angles, we also ensured that these angles did not differ significantly between groups to allow a valid comparison of surgical efficacy. Beyond preoperative mJOA score and affected thoracic level, other potential confounders—including age, diabetes mellitus, symptom duration, number of operated segments, presence of intramedullary high-intensity signal on MRI, OPLL morphology, and spinal canal occupying ratio—were comparable between the two groups. Under these well-matched conditions, we found that TPDF was associated with significantly greater improvement in postoperative lower-extremity motor function and overall neurological recovery compared with PDF.

By combining limited circumferential decompression with thoracic dekyphosis correction, TPDF not only partially relieves ventral compression and reduces longitudinal tension on the thoracic spinal cord but also limits the extent of surgical trauma, the duration of the surgery, and the amount of bleeding. The thoracic spinal cord is physiologically stretched along the kyphotic thoracic spine. In the presence of anterior ossified compression, the spinal cord becomes further tensioned and compressed against the ventral ossified mass. Even after posterior decompression alone, the ability of the spinal cord to migrate posteriorly remains limited. Thoracic dekyphosis correction may therefore reduce spinal cord tension and create additional space between the spinal cord and the ventral ossified lesion, consistent with the “bowstring” relaxation mechanism previously described in thoracic deformity surgery. Moreover, controlled spinal shortening during TPDF may improve spinal cord perfusion and microcirculation[17], thereby promoting neurological recovery following chronic spinal cord compression.

Nevertheless, the TPDF technique has several disadvantages. Because manipulation over the spinal cord ventral surface was required, the incidence of dural tear and CSFL was increased (20/25 vs. 13/25, P = 0.037). CSFL may increase the risk of secondary intracranial hypotension symptom, epidural cerebrospinal fluid cysts, and other serious complications[18]. Operative time and blood loss were inevitably higher in TPDF surgery than in PDF, which posed new challenges to patient safety. However, using our novel circumferential decompression technique, the mean operative time per segment and blood loss per segment in the TPDF group, though higher than those in the PDF group, did not reach statistical significance (25.6 ± 5.7 min vs. 32.0 ± 10.4 min, P = 0.078; 71.9 ± 33.1 mL vs. 102.8 ± 38.7 mL, P = 0.533).

Limitation

This study has several limitations. First, its retrospective, single-center design introduces potential selection and indication bias, as treatment allocation was not randomized and may have been influenced by unmeasured clinical or anatomical factors. Although matching for preoperative mJOA score and TK angle reduced measured baseline heterogeneity, residual confounding cannot be excluded. Second, the small sample size limited statistical power for detecting differences in secondary outcomes and precluded robust assessment of interactions or extensive multivariable adjustment. Third, the single-center, single-team setting may have introduced center- or team-specific effects and limits the generalizability of the findings. Finally, long-term radiographic outcomes, including maintenance of sagittal alignment and fusion status, were not comprehensively assessed. Larger prospective multicenter studies are needed to validate the potential benefits and risks of PTDF in this highly selected patient population

Conclusion

Thoracic posterior dekyphosis and fusion (TPDF) demonstrated superior neurological recovery compared with conventional posterior decompression and fusion (PDF) in non-ambulatory patients with severe multilevel thoracic ossification of the posterior longitudinal ligament (m-TOPLL). By combining limited circumferential decompression with thoracic dekyphosis correction, TPDF may more effectively reduce ventral spinal cord compression and longitudinal spinal cord tension, thereby facilitating postoperative neurological improvement. Although TPDF was associated with a higher incidence of postoperative cerebrospinal fluid leakage, operative duration and intraoperative blood loss remained within acceptable ranges when the procedure was performed by experienced surgical teams.

Abbreviations

m-TOPLL
multilevel thoracic ossification of the posterior longitudinal ligament
PDF
Posterior decompression and fusion
TPDF
thoracic posterior dekyphosis and fusion
TK
thoracic kyphosis
FSK
fusion-segment kyphosis angle
CT
computed tomography
MRI
magnetic resonance imaging
CSFL
cerebrospinal fluid leakage

BMI
body mass index
mJOA
modified Japanese Orthopaedic Association
HIA
high-intensity areas
RR
recovery rate

Declarations

Ethics approval and consent to participate: The Ethical Committee of Peking University Third Hospital approved this research (IRB00006761). Written informed consent and consent for publication were obtained.

Consent for publication: Not applicable.

Availability of data and materials: The datasets analysed during the current study are available from the corresponding author on reasonable request.

Competing interests: The authors have no financial or proprietary interests in any material discussed in this article.

Funding: This study was funded by Peking University Third Hospital Talent Incubation Fund (Grant Number: Y77477-03), The Peking University Third Hospital Clinical Cohort Project (Grant Number: BYSYDL2022009), Natural Science Foundation of Beijing Municipality (Grant Number: 7252164), The National Natural Science Fund of China (Grant Number: 82302745), and Key Clinical Projects of Peking University Third Hospital (No. BYSYZD2024006).

Authors' contributions: ZX wrote this article; YH and GC collected the data. GC and SJ analysed the data. XG and WZ provided guidance on statistics. ZC and WL designed the study. FZ and CS guide the entire research.

References

1. Chen G, Fan T, Yang X, Sun C, Fan D, Chen Z. The prevalence and clinical characteristics of thoracic spinal stenosis: a systematic review. Eur Spine J. 2020;29(9):2164–72.
2. Saiwai H, Okada S, Hayashida M, Harimaya K, Matsumoto Y, Kawaguchi KI, et al. Surgery-related predictable risk factors influencing postoperative clinical outcomes for thoracic myelopathy caused by ossification of the posterior longitudinal ligament: a multicenter retrospective study. J Neurosurg Spine. 2020;32(5):703–9.

3. Xu N, Yu M, Liu X, Sun C, Chen Z, Liu Z. A systematic review of complications in thoracic spine surgery for ossification of the posterior longitudinal ligament. Eur Spine J. 2017;26(7):1803–9.
4. Imagama S, Ando K, Takeuchi K, Kato S, Murakami H, Aizawa T, et al. Perioperative Complications After Surgery for Thoracic Ossification of Posterior Longitudinal Ligament: A Nationwide Multicenter Prospective Study. Spine (Phila Pa 1976). 2018;43(23):E1389–97.
5. Yamazaki M, Mochizuki M, Ikeda Y, Sodeyama T, Okawa A, Koda M, et al. Clinical results of surgery for thoracic myelopathy caused by ossification of the posterior longitudinal ligament: operative indication of posterior decompression with instrumented fusion. Spine (Phila Pa 1976). 2006;31(13):1452–60.
6. Koda M, Furuya T, Okawa A, Inada T, Kamiya K, Ota M, et al. Mid- to long-term outcomes of posterior decompression with instrumented fusion for thoracic ossification of the posterior longitudinal ligament. J Clin Neurosci. 2016;27:87–90.
7. Zhu S, Wang Y, Yin P, Su Q. A systematic review of surgical procedures on thoracic myelopathy. J Orthop Surg Res. 2020;15(1):595.
8. Takahata M, Ito M, Abumi K, Kotani Y, Sudo H, Minami A. Clinical results and complications of circumferential spinal cord decompression through a single posterior approach for thoracic myelopathy caused by ossification of posterior longitudinal ligament. Spine (Phila Pa 1976). 2008;33(11):1199–208.
9. Hu P, Yu M, Liu X, Liu Z, Jiang L. A circumferential decompression-based surgical strategy for multilevel ossification of thoracic posterior longitudinal ligament. spine journal: official J North Am Spine Soc. 2015;15(12):2484–92.
10. Kim SY, Hyun SJ, Kim KJ, Jahng TA. Surgical Outcomes According to Dekyphosis in Patients with Ossification of the Posterior Longitudinal Ligament in the Thoracic Spine. J Korean Neurosurg Soc. 2020;63(1):89–98.
11. Sun C, Chen Z, Chen G, Li W, Qi Q, Guo Z, et al. A new de-tension-guided surgical strategy for multilevel ossification of posterior longitudinal ligament in thoracic spine: a prospective observational study with at least 3-year follow-up. spine journal: official J North Am Spine Soc. 2022;22(8):1388–98.
12. Chen G, Chen Z, Li W, Zeng Y, Zhong W, Sun C. IV + V+VI Circumferential Decompression Technique for Thoracic Myelopathy Caused by the Ossification of Posterior Longitudinal Ligament or Hard Disc Herniation. Spine (Phila Pa 1976). 2020;45(22):1605–12.
13. Lei J, Hu P, Liu X, Zhou H, Tang Y, Li T, et al. Balancing Efficacy and Safety for Non-ambulatory Thoracic OPLL: Superior Mobility with Circumferential Decompression but Higher Risks - A Retrospective Analysis. Global Spine J. 2026;16(2):1156–64.
14. Kawahara N, Tomita K, Murakami H, Hato T, Demura S, Sekino Y, et al. Circumspinal decompression with dekyphosis stabilization for thoracic myelopathy due to ossification of the posterior longitudinal ligament. Spine (Phila Pa 1976). 2008;33(1):39–46.

15. Kato S, Murakami H, Demura S, Yoshioka K, Hayashi H, Tsuchiya H. Novel surgical technique for ossification of posterior longitudinal ligament in the thoracic spine. J Neurosurg Spine. 2012;17(6):525–9.
16. Tayal A, Mitra P, Modak A, Asri S, Garg K. Factors predicting the outcome of thoracic ossification of ligamentum flavum (OLF) surgery: A systematic review and meta-analysis. J Clin Neurosci. 2025;142:111649.
17. Kawahara N, Tomita K, Kobayashi T, Abdel-Wanis ME, Murakami H, Akamaru T. Influence of acute shortening on the spinal cord: an experimental study. Spine (Phila Pa 1976). 2005;30(6):613–20.
18. Hu PP, Liu XG, Yu M. Cerebrospinal Fluid Leakage after Thoracic Decompression. Chin Med J (Engl). 2016;129(16):1994–2000.

Figures

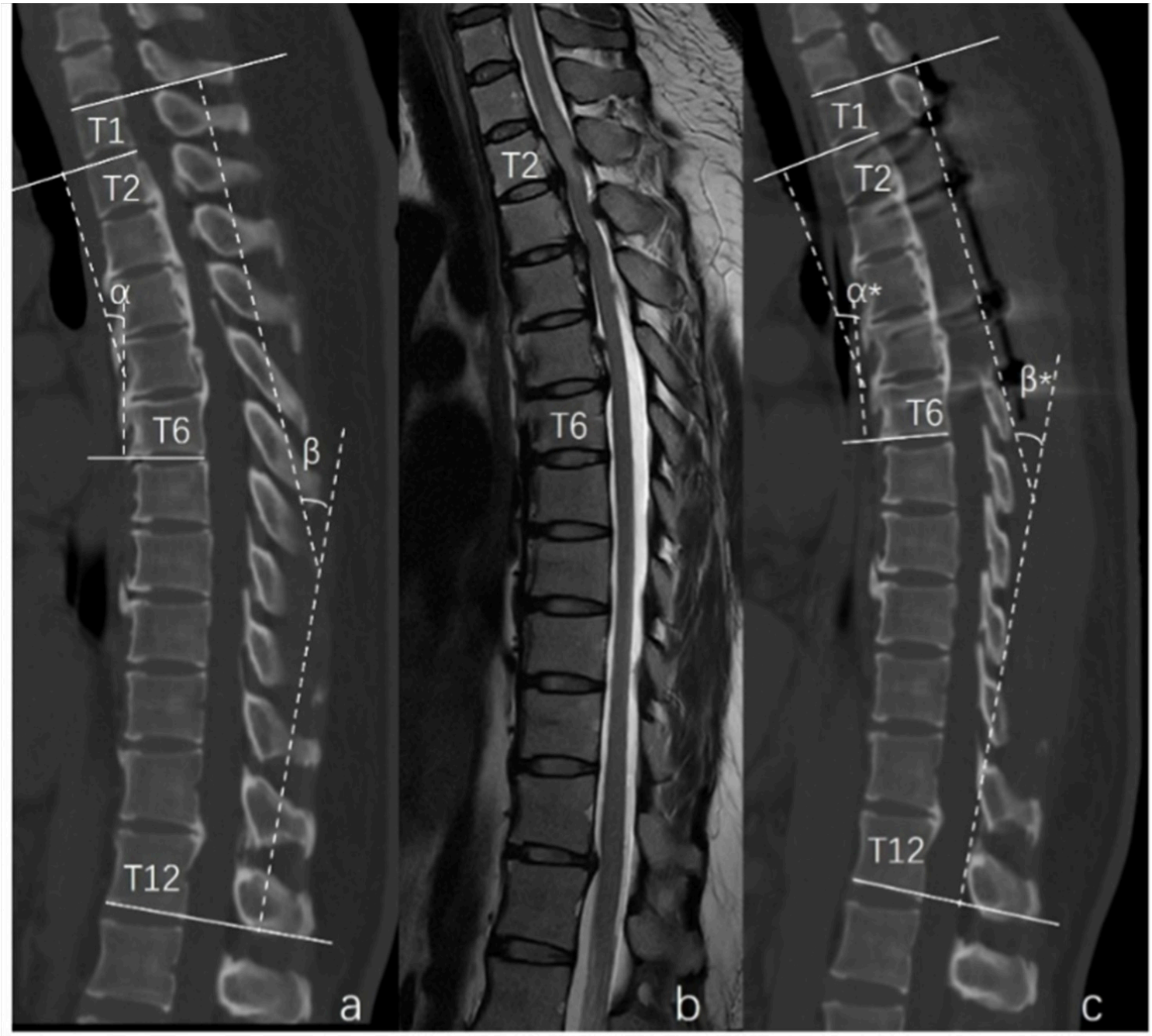

Figure 1

Case 1, a 40-year-old female, had numbness and weakness in both lower extremities and was unable to walk for one month. Preoperative CT (A) and MRI (B) showed T2-6 flat-type OPLL, and she underwent T2-6 PDF surgery. CT showed that preoperative FSK was 18.4° and TK was 26.3° (A). One week after the operation, CT showed FSK was 17.8° and TK was 27.4° (C).

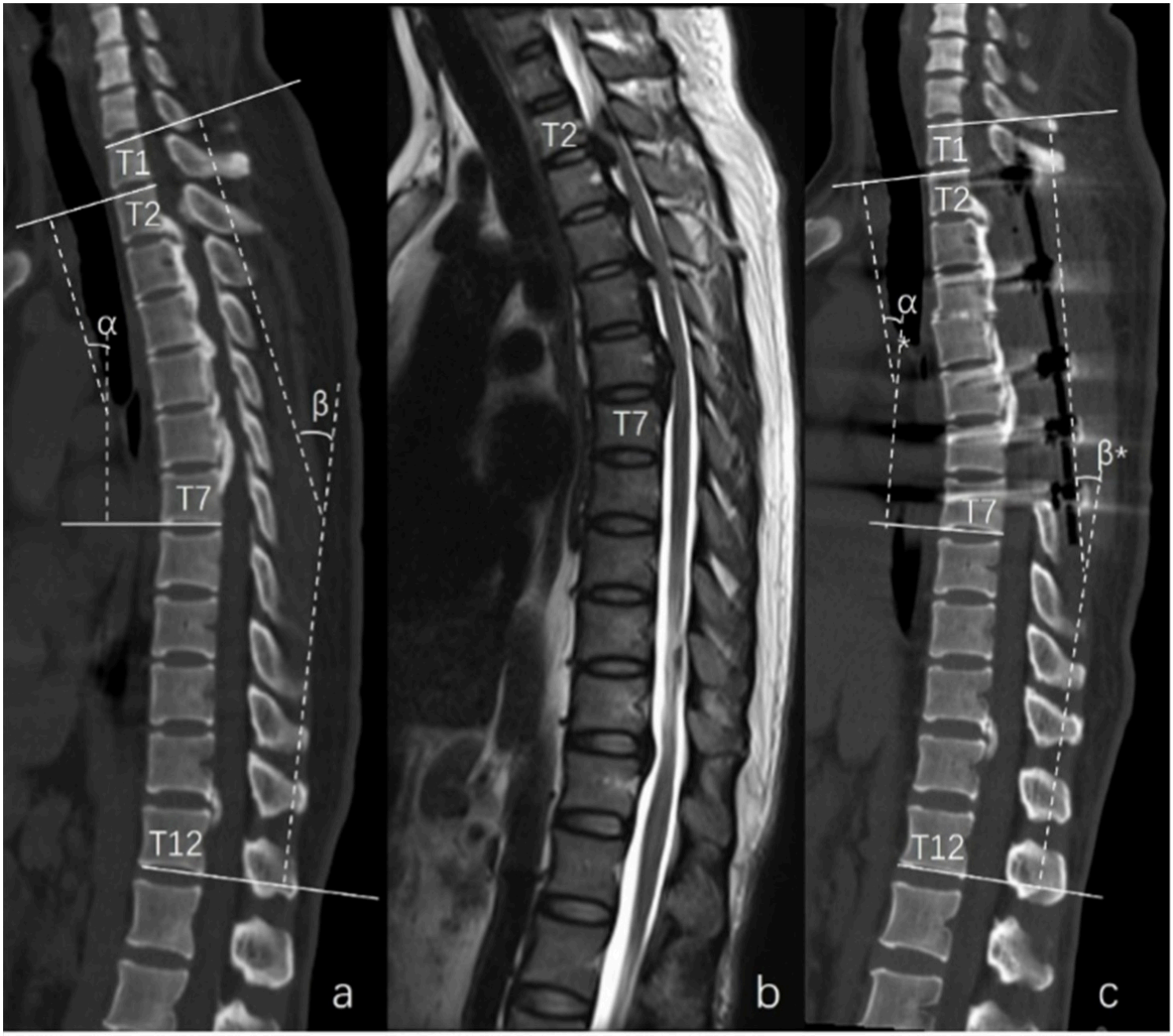

Figure 2

Case 2, female, 44 years old, numbness and weakness in both lower limbs for 6 months, unable to walk for 1 month. Preoperative CT (A) and MRI (B) showed T2-7 beak-type OPLL. She underwent T2-7 PTDF (circumferential decompression at T4-5) surgery. Preoperative CT showed FSK 18.5° and TK 24.1° (A), and 1 week after surgery, CT showed FSK 14.3° and TK 17.3° (C)