Research Square

Preprints are preliminary reports that have not undergone peer review.
They should not be considered conclusive, used to inform clinical practice,
or referenced by the media as validated information.

Artificial intelligence–assisted detection of lung cancer using bronchoscopic images

Yun Su Sim

sysliver@naver.com

Hallym University Kangnam Sacred Heart Hospital

Soo Jung Kim

Hallym University Kangnam Sacred Heart Hospital

Hayoung Choi

Hallym University Kangnam Sacred Heart Hospital

Tae Rim Shin

Hallym University Kangnam Sacred Heart Hospital

Junghyun Kim

Hallym University Dongtan Sacred Heart Hospital

Nisan Aryal

MTEG

Deok-Seok Kim

MTEG

Research Article

Keywords: Lung cancer, Bronchoscopy, Deep learning, Artificial intelligence, Convolutional neural network, Computer-aided diagnosis

Posted Date: September 4th, 2026

DOI: https://doi.org/10.21203/rs.3.rs-10597190/v1

License: This work is licensed under a Creative Commons Attribution 4.0 International License.
Read Full License

Additional Declarations: No competing interests reported.

Abstract

Background

Bronchoscopy plays a key role in the diagnosis of lung cancer; however, its diagnostic performance is variable and operator-dependent. This study aimed to develop and evaluate deep learning models for lung cancer detection using white light bronchoscopic images.

Methods

Bronchoscopic images were retrospectively collected from 1,828 patients at two independent institutions between January 2016 and December 2024. Two convolutional neural network architectures, ResNet34 and EfficientNet-B1, were trained for binary classification of normal versus lung cancer images using strict patient-level dataset splitting. Model performance was evaluated using accuracy, sensitivity, specificity, positive predictive value, negative predictive value, and area under the receiver operating characteristic curve (AUC). Subtype classification into four histologic categories was additionally explored.

Results

For binary classification, ResNet34 achieved an accuracy of 0.945, sensitivity of 0.905, specificity of 0.985, and AUC of 0.980. EfficientNet-B1 showed marginally superior performance, with an accuracy of 0.952, sensitivity of 0.911, specificity of 0.992, and AUC of 0.985. For subtype classification, squamous cell carcinoma showed the relatively highest sensitivity in both models (ResNet34: 0.733, EfficientNet-B1: 0.727), whereas adenocarcinoma showed the lowest (ResNet34: 0.162, EfficientNet-B1: 0.393); overall subtype classification performance was modest.

Conclusions

Deep learning models applied to white light bronchoscopic images demonstrated high diagnostic performance for lung cancer detection, with EfficientNet-B1 showing marginally superior performance over ResNet34. These findings suggest that AI-assisted bronchoscopy may serve as a clinically useful adjunct for lung cancer detection. Prospective multicenter validation is warranted before clinical implementation.

Introduction

Lung cancer remains the leading cause of cancer-related mortality worldwide, accounting for approximately 18% of all cancer deaths globally[1]. Early and accurate diagnosis is essential for improving patient outcomes, as survival rates decline substantially with advancing disease stage.

Bronchoscopy is an endoscopic procedure that allows direct visualization of the airways and is widely used in the diagnosis of lung cancer, particularly for centrally located tumors where endobronchial lesions can be directly visualized and sampled[2,4]. Endobronchial lesions refer to abnormal mucosal findings observed during bronchoscopy, including mucosal irregularity, nodularity, or mass formation, which may represent malignant or pre-malignant changes. For visible endobronchial lesions, the sensitivity of bronchoscopy has been reported to be approximately 80–90%; however, diagnostic yield decreases substantially for peripheral or less obvious lesions, and performance varies considerably depending on operator expertise[2,4,5]. Invasive procedures such as percutaneous needle biopsy carry risks of complications including pneumothorax and bleeding[3], underscoring the need for improved diagnostic approaches.

In recent years, artificial intelligence (AI), particularly deep learning, has demonstrated significant potential in medical image analysis[6–9]. AI-based systems have achieved expert-level performance in polyp detection during gastrointestinal endoscopy and have shown high accuracy in lung cancer detection using computed tomography imaging[6–9].

In the field of bronchoscopy, AI has been explored across a range of applications, including airway anatomy recognition, navigation assistance, endobronchial ultrasound (EBUS)-based malignancy classification, and assessment of bronchoscopic competency[10,12,21–24]. A recent systematic review by Cold et al. identified 20 studies applying AI to bronchoscopy, categorized into three domains: airway anatomy and navigation, computer-aided diagnosis in EBUS, and rapid on-site evaluation[12]. Despite this growing body of work, only a few studies have attempted deep learning-based lung cancer detection using white light bronchoscopic images[11,13–16]. These studies have reported promising results; however, they are limited by single-center designs, relatively small datasets, and the use of image-level rather than patient-level dataset splitting, which may introduce data leakage and overestimate model performance.

Therefore, in this study, we aimed to develop and validate deep learning models for lung cancer detection and subtype classification using white light bronchoscopic images from two independent institutions, applying strict patient-level dataset splitting to ensure methodological rigor.

Methods

Study design and data source

This retrospective multicenter study included patients who underwent bronchoscopy between January 2016 and December 2024 at Hallym University Kangnam Sacred Heart Hospital and Hallym University Dongtan Sacred Heart Hospital. All bronchoscopic procedures were performed by pulmonologists.

Bronchoscopic images were retrospectively collected and reviewed. Image labeling was performed independently by two pulmonologists. In cases of disagreement, the final label was determined by discussion and mutual agreement between the two pulmonologists.

The study dataset comprised 1,828 patients (N), including 1,231 normal cases and 597 lung cancer cases, and 14,118 bronchoscopic images (n), including 11,827 normal images and 2,291 lung cancer images (Table 1). The dataset was divided at the patient level into training, validation, and test sets to avoid information leakage between subsets.

Table 1
Overview of the study dataset and data split

Category	Train	Validation	Test	Total
Patients, N				
Normal	862	184	185	1231
Lung cancer	422	87	88	597
Total patients	1284	271	273	1828
Images, n				
Normal	8292	1752	1783	11827
Lung cancer	1639	347	305	2291
Total images	9931	2099	2088	14118

Patients correspond to individual bronchoscopic examinations. Images were obtained from bronchoscopic procedures. Low-quality images, including motion-blurred or no-signal images, were excluded during dataset preparation. N, number of patients; n, number of images.

Image selection and dataset preparation

Bronchoscopic images were obtained from routine clinical practice. Low-quality images, including motion-blurred or no-signal images, were excluded during dataset preparation through manual review by the labeling pulmonologists.

For the binary classification task, images were categorized as either normal or lung cancer. For the subtype classification task, lung cancer images were further categorized into adenocarcinoma, squamous cell carcinoma, small cell lung cancer, and other histologic subtypes. The dataset was divided into training, validation, and test sets at the patient level, comprising 9,931, 2,099, and 2,088 images (n), respectively.

Model development

Two convolutional neural network architectures, ResNet34 and EfficientNet-B1, were selected for binary classification of bronchoscopic images. ResNet34 was chosen for its proven effectiveness in medical image classification tasks and its ability to train deep networks without vanishing gradient issues

through residual skip connections[17]. EfficientNet-B1 was selected for its compound scaling strategy that efficiently balances network depth, width, and input resolution, achieving superior performance with fewer parameters compared to other architectures[18]. Both architectures have demonstrated competitive performance in lung-related image classification tasks[19,20].

Both models were initialized with ImageNet pretrained weights and fine-tuned on the bronchoscopic image dataset. Images in the training set were used for model training, and those in the validation set were used for monitoring performance and selecting the best model during training. The test set was used only for final performance evaluation. Models were trained using the Adam optimizer with a learning rate of 0.0001 and a batch size of 128 for 150 epochs. The model checkpoint with the best validation accuracy was saved during training and used for final performance evaluation. For the binary classification task, binary cross-entropy loss with class weighting was applied to address class imbalance between normal and lung cancer images. For the subtype classification task, cross-entropy loss with class weighting was applied across the four subtypes. Data augmentation was performed on the training dataset, with multiple transformations applied simultaneously to each image to improve model generalizability. This included random affine transformations with rotations up to 15°, horizontal and vertical translations of up to 10%, scaling between 0.9 and 1.1, and shearing up to 0.1 radians. Images were resized to 224 × 224 pixels and normalized before being input into the models.

Subtype classification

Since lung cancer subtypes are defined by histopathological criteria, their distinction based on white light bronchoscopic appearances alone is inherently challenging. Nevertheless, we additionally explored whether the deep learning models could differentiate between major histologic subtypes based solely on bronchoscopic images, given that different subtypes may exhibit distinct endoscopic features. Lung cancer images were classified into four categories: squamous cell carcinoma (SQC), small cell lung cancer (SCLC), adenocarcinoma (ADC), and other histologic subtypes. Both ResNet34 and EfficientNet-B1 models were applied using the same patient-level split strategy.

Outcome measures and performance evaluation

Model performance for binary classification was evaluated using accuracy, sensitivity, specificity, positive predictive value, negative predictive value, and the area under the receiver operating characteristic curve (AUC). For subtype classification, sensitivity and positive predictive value were calculated for each subtype. Confusion matrices and receiver operating characteristic curves were used to visualize model performance.

Statistical analysis

Descriptive statistics were used to summarize the dataset. Model performance metrics were calculated on the independent test set. All analyses were performed using Python 3.10.6 with PyTorch 2.1.0.

Ethics statement

This study was approved by the Institutional Review Boards of Hallym University Kangnam Sacred Heart Hospital and Hallym University Dongtan Sacred Heart Hospital (HKS 2024-05-001-004). All methods were performed in accordance with the relevant guidelines and regulations. The requirement for informed consent was waived due to the retrospective nature of the study.

Results

Dataset characteristics

A total of 1,828 patients and 14,118 bronchoscopic images were included in the final dataset after excluding low-quality images (Fig. 1), and were divided into training, validation, and test sets at the patient level (Table 1).

Performance of deep learning models for lung cancer detection

Both deep learning models demonstrated high performance in distinguishing lung cancer from normal bronchoscopic images (Table 2, Fig. 2).

Table 2
Performance of deep learning models for lung cancer detection

Model	Accuracy	Sensitivity	Specificity	PPV	NPV	AUC
ResNet34	0.945	0.905	0.985	0.911	0.980	0.980
EfficientNet-B1	0.952	0.911	0.992	0.952	0.990	0.985

PPV, positive predictive value; NPV, negative predictive value; AUC, area under the receiver operating characteristic curve.

The ResNet34 model achieved an accuracy of 0.945, sensitivity of 0.905, specificity of 0.985, and AUC of 0.980. The EfficientNet-B1 model showed slightly improved performance, with an accuracy of 0.952, sensitivity of 0.911, specificity of 0.992, and AUC of 0.985.

The ROC curves of both models demonstrated excellent discriminative ability, with EfficientNet-B1 showing a marginally higher AUC than ResNet34 (Fig. 2).

Confusion matrix analysis

The confusion matrices for lung cancer detection are shown in Fig. 3A. The ResNet34 model correctly classified 1,756 normal images and 276 lung cancer images, with 27 false positives and 29 false negatives, yielding a sensitivity of 0.905 and specificity of 0.985. The EfficientNet-B1 model correctly classified 1,769 normal images and 278 lung cancer images, with 14 false positives and 27 false negatives, yielding a sensitivity of 0.911 and specificity of 0.992. Both models achieved high classification performance, and EfficientNet-B1 demonstrated a notably lower false positive rate compared with ResNet34 (14 vs. 27), suggesting superior specificity in distinguishing normal from malignant bronchoscopic findings.

Subtype classification performance

The confusion matrices for lung cancer subtype classification are shown in Fig. 3B, and performance metrics are summarized in Table 3. Overall, subtype classification performance was modest for both models. Among the four subtypes, squamous cell carcinoma showed the relatively highest sensitivity in both ResNet34 and EfficientNet-B1 (0.733 and 0.727, respectively), with PPV of 0.532 and 0.556, respectively. Small cell lung cancer demonstrated intermediate sensitivity in both models (ResNet34: 0.310, EfficientNet-B1: 0.352), with PPV of 0.352 and 0.409, respectively. Adenocarcinoma showed the most notable difference between models: ResNet34 achieved a sensitivity of 0.162 with PPV of 0.393, whereas EfficientNet-B1 showed substantially higher sensitivity of 0.393 with PPV of 0.431. Other subtypes showed the lowest sensitivity across both models (ResNet34: 0.120, EfficientNet-B1: 0.200), with PPV of 0.250 and 0.217, respectively.

Table 3
Performance of deep learning models for lung cancer subtype classification

Subtype	**ResNet34**		**EfficientNet-B1**	
	Sensitivity	**PPV**	**Sensitivity**	**PPV**
Squamous cell carcinoma (n = 1055)	0.733	0.532	0.727	0.556
Small cell lung cancer (n = 606)	0.310	0.352	0.352	0.409
Adenocarcinoma (n = 399)	0.162	0.393	0.393	0.431
Others (n = 231)	0.120	0.250	0.250	0.217
n values indicate the number of images in the test set. PPV, positive predictive value.				

Discussion

In this study, we developed and evaluated deep learning models for lung cancer detection and subtype classification using bronchoscopic images from two independent institutions, in contrast to prior white light bronchoscopic studies that were all conducted at single centers. Both ResNet34 and EfficientNet-B1 demonstrated high diagnostic performance for binary classification, achieving AUC values of 0.980

and 0.985, respectively, with EfficientNet-B1 showing marginally superior performance across all metrics. These results suggest that deep learning-based analysis of bronchoscopic images has the potential to serve as a reliable tool for assisting clinicians in the detection of lung cancer during bronchoscopic examination.

A recent systematic review by Cold et al. identified 20 studies applying AI to bronchoscopy, categorized into three domains: airway anatomy and navigation, CADx in EBUS, and rapid on-site evaluation[12]. Only a few studies have attempted deep learning-based lung cancer detection using white light bronchoscopic images[11,13–16]. These studies generally reported relatively high accuracy; however, only Deng et al. provided a detailed breakdown of sensitivity and specificity[16]. Deng et al. reported a sensitivity of 0.978 using ResNet101 with image-level splitting, which was comparable to our results; however, the specificity was considerably lower at 0.833 compared with 0.985 and 0.992 achieved by ResNet34 and EfficientNet-B1 in the present study[16]. The relatively lower specificity may in part reflect the use of image-level rather than patient-level dataset splitting, which can introduce data leakage and lead to overestimation of model performance. Furthermore, none of the prior bronchoscopic studies directly compared EfficientNet and ResNet architectures. In the present study, EfficientNet-B1 demonstrated marginally superior performance compared with ResNet34 across all binary classification metrics. This finding is consistent with previous studies using CT and chest X-ray images, which have consistently reported superior performance of EfficientNet over ResNet in lung cancer classification tasks[19,20]. This superior performance may be attributed to EfficientNet's compound scaling strategy, which simultaneously optimizes network depth, width, and input resolution, as well as its layered feature extraction mechanism, in which each stage builds upon representations learned by the previous layer, facilitating the learning of increasingly complex visual patterns[19]. The current models were developed using still images from bronchoscopic procedures and do not incorporate additional clinical information such as computed tomography findings or pathologic data. Integration of bronchoscopic AI with complementary modalities, such as endobronchial ultrasound (EBUS), radial EBUS, or CT-based navigation bronchoscopy, may offer a more comprehensive diagnostic approach and warrants further investigation.

To our knowledge, no previous study has attempted deep learning-based subtype classification of lung cancer using white light bronchoscopic images, making direct comparison with prior work difficult. While deep learning has been applied to histopathological slides and CT images for lung cancer subtype classification, the feasibility of such classification based solely on bronchoscopic appearances has not previously been investigated. The modest subtype classification performance observed in the present study is likely attributable to the inherent difficulty of distinguishing histopathologically defined subtypes based on visual bronchoscopic features alone. Squamous cell carcinoma showed the relatively highest sensitivity in both models, which may reflect its tendency to present as a centrally located, exophytic endobronchial lesion that is more readily identifiable on white light bronchoscopy, as well as the largest number of training images available for this subtype (n = 1,055). In contrast, adenocarcinoma showed the lowest sensitivity, likely because it more commonly arises peripherally and may present with subtle or absent endobronchial findings, and had fewer training images available (n = 399). A similar pattern of

subtype-dependent performance was reported by Deng et al.[16], further supporting the notion that these differences reflect inherent characteristics of each subtype rather than model limitations alone.

This study has several limitations. First, its retrospective design may introduce selection bias, and prospective validation in a real-time clinical setting is warranted. Second, a substantial class imbalance existed between normal and lung cancer images (11,827 vs. 2,291), which was addressed through class weighting during model training; however, collecting a larger and more balanced dataset in future studies would be expected to further improve model performance and generalizability. Third, the relatively small number of images for certain subtypes, particularly adenocarcinoma and other histologic subtypes, may have limited subtype classification performance. Future studies with larger and more balanced subtype datasets are needed to improve classification accuracy.

In conclusion, deep learning models applied to white light bronchoscopic images demonstrated high diagnostic performance for lung cancer detection, with EfficientNet-B1 showing marginally superior performance over ResNet34. These findings suggest that AI-assisted bronchoscopy has the potential to serve as a clinically useful adjunct for lung cancer detection, particularly in resource-limited settings or institutions with high bronchoscopic workloads. Future studies should investigate whether AI-assisted bronchoscopy provides greater benefit to less experienced bronchoscopists compared to expert endoscopists, and should explore the integration of bronchoscopic AI with complementary modalities such as EBUS, radial EBUS, or CT-based navigation bronchoscopy to further enhance diagnostic accuracy. Prospective multicenter validation with larger datasets will be essential to establish the clinical applicability of these models before implementation in routine bronchoscopic practice.

Abbreviations

ADC: Adenocarcinoma; AI: Artificial intelligence; AUC: Area under the receiver operating characteristic curve; CADx: Computer-aided diagnosis; EBUS: Endobronchial ultrasound; PPV: Positive predictive value; ROC: Receiver operating characteristic; SCLC: Small cell lung cancer; SQC: Squamous cell carcinoma

Declarations

Ethics approval and consent to participate

This study was approved by the Institutional Review Boards of Hallym University Kangnam Sacred Heart Hospital and Hallym University Dongtan Sacred Heart Hospital (HKS 2024-05-001-004). The requirement for informed consent was waived due to the retrospective nature of the study.

Consent for publication

Not applicable.

Availability of data and materials

The datasets generated and analysed during the current study are not publicly available due to patient privacy considerations but are available from the corresponding author on reasonable request.

Competing interests

The authors declare that they have no competing interests.

Funding

This research was supported by Hallym University Medical Center Research Fund.

Authors' contributions

Y.S.S. conceived and designed the study, supervised the project, and wrote the manuscript. S.J.K., H.C., and T.R.S. contributed to data collection and clinical annotation. J.K. contributed to data collection. N.A. and D.S.K. developed the deep learning models and performed the analysis. All authors read and approved the final manuscript.

Acknowledgements

Not applicable.

References

1. Sung H, Ferlay J, Siegel RL, Laversanne M, Soerjomataram I, Jemal A, et al. Global Cancer Statistics 2020: GLOBOCAN Estimates of Incidence and Mortality Worldwide for 36 Cancers in 185 Countries. CA Cancer J Clin. 2021;71:209–49.
2. Du Rand IA, Blaikley J, Booton R, Chaudhuri N, Gupta V, Khalid S, et al. British Thoracic Society guideline for diagnostic flexible bronchoscopy in adults: accredited by NICE. Thorax. 2013;68(Suppl 1):i1–44.
3. Rivera MP, Mehta AC, Wahidi MM. Establishing the diagnosis of lung cancer: Diagnosis and management of lung cancer, 3rd ed: American College of Chest Physicians evidence-based clinical practice guidelines. Chest. 2013;143:eS142–65.
4. Nadig TR, Chen AC, Donovan C, Flandes JC, Kheir F, Lamb CR, et al. Guided Bronchoscopy for the Evaluation of Pulmonary Lesions: An Updated Meta-analysis. Chest. 2023;163:1589–98.
5. Ost DE, Ernst A, Lei X, Kovitz KL, Benzaquen S, Diaz-Mendoza J, et al. Diagnostic Yield and Complications of Bronchoscopy for Peripheral Lung Lesions. Results of the AQuIRE Registry. Am J Respir Crit Care Med. 2016;193:68–77.
6. Urban G, Tripathi P, Alkayali T, Mittal M, Jalali F, Karnes W, et al. Deep Learning Localizes and Identifies Polyps in Real Time With 96% Accuracy in Screening Colonoscopy. Gastroenterology. 2018;155:1069–e10788.

7. Ardila D, Kiraly AP, Bharadwaj S, Choi B, Reicher JJ, Peng L, et al. End-to-end lung cancer screening with three-dimensional deep learning on low-dose chest computed tomography. Nat Med. 2019;25:954–61.
8. Wang P, Liu X, Berzin TM, Glissen Brown JR, Liu P, Zhou C, et al. Effect of a deep-learning computer-aided detection system on adenoma detection during colonoscopy (CADe-DB trial): a double-blind randomised study. Lancet Gastroenterol Hepatol. 2020;5:343–51.
9. Mikhael PG, Wohlwend J, Yala A, Karstens L, Xiang J, Takigami AK, et al. Sybil: A Validated Deep Learning Model to Predict Future Lung Cancer Risk From a Single Low-Dose Chest Computed Tomography. J Clin Oncol. 2023;41:2191–200.
10. Hotta T, Fujiwara T, Takigawa N, Ichihara E, Harada D, Kubo T, et al. Deep learning-based diagnosis from endobronchial ultrasonography images of pulmonary lesions. Sci Rep. 2022;12:13710.
11. Vu VG, Nguyen DM, Tran CT, Nguyen TN, Le TL, Pham HN, et al. BM-BronchoLC - A rich bronchoscopy dataset for anatomical landmarks and lung cancer lesion recognition. Sci Data. 2024;11:321.
12. Cold KM, Iyengar P, Konge L, Clementsen PF, Hostrup Nielsen H, Annema JT, et al. Artificial intelligence in bronchoscopy: a systematic review. Eur Respir Rev. 2025;34:240274.
13. Liu Q, Zheng H, Jia Z, Shi Z. Tumor detection on bronchoscopic images by unsupervised learning. Sci Rep. 2025;15:245.
14. Tan T, Mao J, Zhang J, Shan F, Ji L, Liu J, et al. Optimize Transfer Learning for Lung Diseases in Bronchoscopy Using a New Concept: Sequential Fine-Tuning. IEEE J Transl Eng Health Med. 2018;6:1800808.
15. Setayeshi R, Vahidi J, Kozegar E, Tan T. An end-to-end multi-task deep learning framework for bronchoscopy image classification. Multimedia Syst. 2024;30:361.
16. Deng Y, Chen Y, Xie L, Wang L, Zhan J. The investigation of construction and clinical application of image recognition technology assisted bronchoscopy diagnostic model of lung cancer. Front Oncol. 2022;12:1001840.
17. He K, Zhang X, Ren S, Sun J. Deep residual learning for image recognition. Proc IEEE Conf Comput Vis Pattern Recognit. 2016:770–8.
18. Tan M, Le QV, EfficientNet. Rethinking model scaling for convolutional neural networks. Proc Int Conf Mach Learn. 2019;97:6105–14.
19. Raza R, Ayub H, Khan JA, Ahmad I, Salama AS, Damaševičius R, et al. Lung-EffNet: Lung cancer classification using EfficientNet from CT-scan images. Eng Appl Artif Intell. 2023;126:106902.
20. Kansal K, Chandra TB, Singh A. ResNet-50 vs. EfficientNet-B0: Multi-Centric Classification of Various Lung Abnormalities Using Deep Learning. Procedia Comput Sci. 2024;235:70–80.
21. Yoo JS, Kim J, Kim S, Lee BD, Kim YD. Deep learning for anatomical interpretation of video bronchoscopy images. Sci Rep. 2021;11:23765.

22. Winiarski S, Perch M, Clementsen PF, Folch EE, Iyengar P, Konge L, et al. Integrating Artificial Intelligence in Bronchoscopy and Endobronchial Ultrasound (EBUS) for Lung Cancer Diagnosis and Staging: A Comprehensive Review. Cancers (Basel). 2025;17:2835.
23. Brower D, Murgu SD. Artificial Intelligence in Interventional Pulmonology. Ther Adv Pulm Crit Care Med. 2025;20:29768675251353390.
24. Cao Z, Murgu SD. Artificial Intelligence in Respiratory Endoscopy. In: Murgu SD, editor. Principles and Practice of Interventional Pulmonology. Cham: Springer; 2025.

Figures

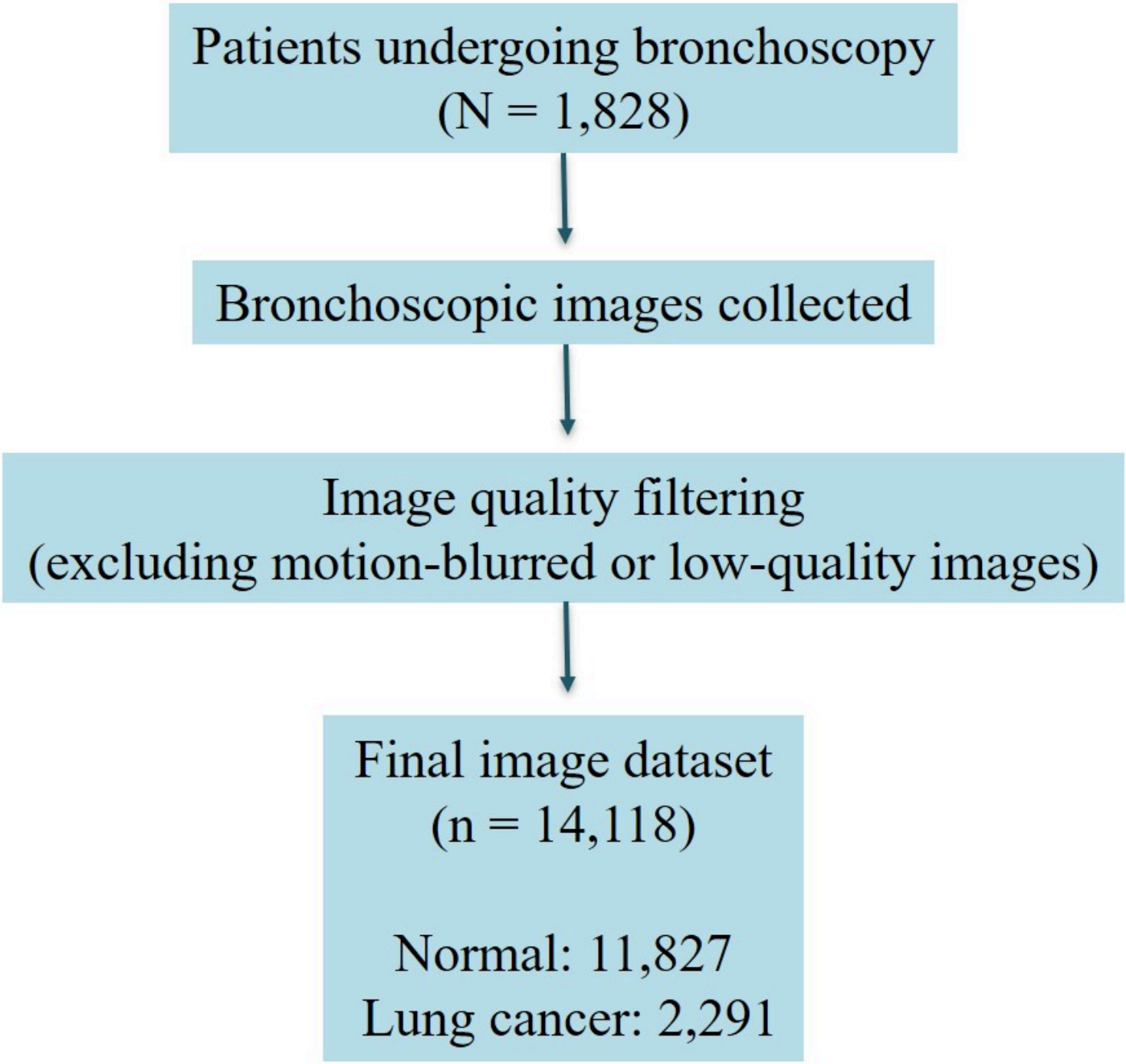

Figure 1

Study workflow and dataset construction.

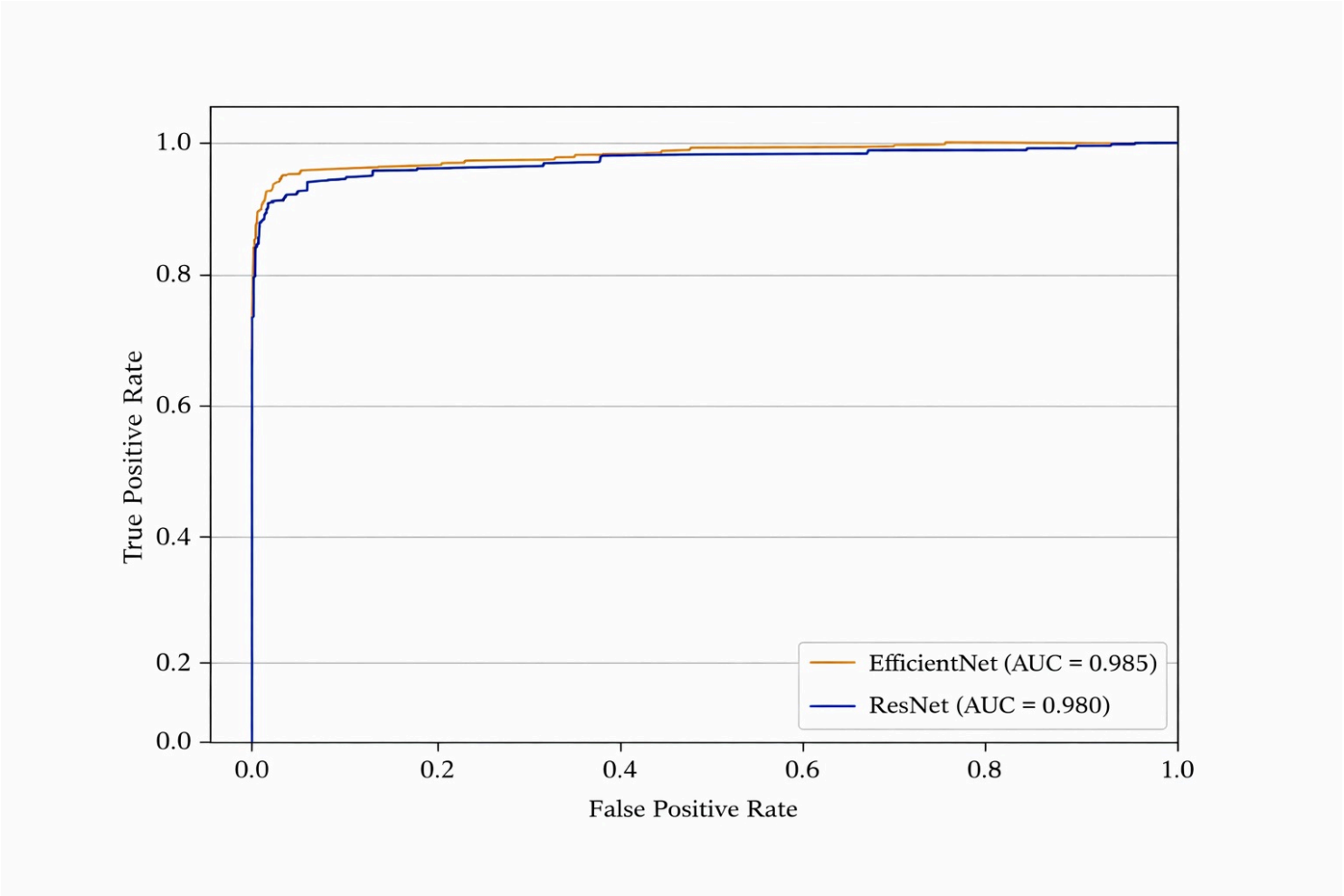

Figure 2

Receiver operating characteristic curves for lung cancer detection.

A)

ResNet34

		Predicted	
		Normal	Cancer
Actual	Normal	1756	27
	Cancer	29	276

EfficientNet-B1

		Predicted	
		Normal	Cancer
Actual	Normal	1769	14
	Cancer	27	278

B)

ResNet34

		Predicted			
		ADC	Others	SCLC	SQC
Actual	ADC	11	3	16	38
	Others	3	3	4	15
	SCLC	6	5	31	58
	SQC	8	5	37	126

EfficientNet-B1

		Predicted			
		ADC	Others	SCLC	SQC
Actual	ADC	22	6	8	32
	Others	2	5	6	15
	SCLC	14	6	27	53
	SQC	13	6	28	125

Figure 3

Confusion matrices for lung cancer detection and subtype classification. (ADC, adenocarcinoma; SCLC, small cell lung cancer; SQC, squamous cell carcinoma; Others, other histologic subtypes)