Research Square

Preprints are preliminary reports that have not undergone peer review.
They should not be considered conclusive, used to inform clinical practice,
or referenced by the media as validated information.

Femoral External Rotation Adjustment Improves Patellar Tracking but Does Not Affect Short-Term Clinical Outcomes in Robotic-Assisted Functional-Alignment TKA

Mengran Shen
Jiangsu Province (Suqian) Hospital
Yuzhu Wu
Chinese Academy of Medical Sciences and Peking Union Medical College
Hongxu Li
Peking University China-Japan Friendship School of Clinical Medicine
Qihan Ma
Chinese Academy of Medical Sciences & Peking Union Medical College
Bailiang Wang
China-Japan Friendship Hospital
Jinhui Ma
1402317340@qq.com

China-Japan Friendship Hospital

Research Article

Keywords: robotic-assisted total knee arthroplasty, femoral rotational adjustment, patellofemoral alignment, soft tissue release, functional alignment

Posted Date: August 12th, 2026

DOI: https://doi.org/10.21203/rs.3.rs-10529978/v1

License: This work is licensed under a Creative Commons Attribution 4.0 International License.
Read Full License

Additional Declarations: No competing interests reported.

Abstract

Background

Femoral rotational adjustment is a key intraoperative variable in robotic-assisted total knee arthroplasty (TKA) and may influence patellofemoral mechanics, soft tissue balancing, and anterior compartment morphology. However, the clinical and radiographic implications of individualized rotational adjustment remain incompletely understood. This study aimed to evaluate the effects of femoral external rotational adjustment on patellofemoral alignment, soft tissue release, anterior compartment morphology, and short-term clinical outcomes following robotic-assisted TKA.

Methods

A retrospective analysis was performed on 84 varus knees undergoing robotic-assisted TKA. Patients were stratified according to the magnitude of femoral external rotational adjustment into three groups: no adjustment (0°, n = 26), ≤ 2° adjustment (n = 33), and > 2° adjustment (n = 25). Radiographic assessments included postoperative posterior condylar angle (PCA), patellar tilt, lateral patellar displacement, and changes in anterior femoral morphology (ΔAPD, ΔAFO, and ΔPFJD). Associations between rotational adjustment, deformity severity, and soft tissue release were evaluated. Multivariable linear and logistic regression analyses were performed to identify independent predictors of patellofemoral alignment, soft tissue release, and postoperative understuffing. Clinical outcomes were assessed using WOMAC scores.

Result

Rotational adjustment independently improved lateral patellar tracking but not patellar tilt. Multivariable linear regression demonstrated that rotational adjustment was independently associated with reduced lateral patellar displacement (β=-0.150, P = 0.043), whereas patellar tilt was primarily determined by its preoperative value (β=-0.596, P < 0.001). Patients requiring greater rotational adjustment exhibited more severe preoperative varus deformity, reflected by lower HKA values (P = 0.034). Soft tissue release rates increased progressively across groups (23.1%, 33.3%, and 56.0%, respectively; P = 0.044). However, multivariable logistic regression identified preoperative HKA, rather than rotational adjustment, as the only independent predictor of soft tissue release (OR = 0.402, P < 0.001). No significant predictors of postoperative understuffing were identified. WOMAC scores improved substantially in all groups, with no significant between-group differences at baseline, 3 months, or 6 months postoperatively (all P > 0.05).

Conclusions

Femoral rotational adjustment in robotic-assisted TKA significantly influences patellofemoral alignment, particularly lateral patellar displacement, through both rotational and anterior femoral structural changes. However, it does not affect anterior compartment stuffing or the occurrence of stuffing. An external rotation adjustment greater than approximately 2° may be required to achieve meaningful improvement in patellar tracking

Clinical trial registration

Clinical trial number: not applicable.

Introduction

Total knee arthroplasty is one of the most successful surgical procedures for the treatment of end-stage knee osteoarthritis, providing substantial pain relief and functional improvement. Despite excellent implant survivorship, up to 20% of patients remain dissatisfied following TKA, with persistent anterior knee pain and patellofemoral dysfunction representing major causes of suboptimal outcomes[1, 2]. Femoral component rotational alignment is widely recognized as a key determinant of patellofemoral tracking, influencing patellar tilt, lateral displacement, and overall joint kinematics[3, 4]. Conventional techniques rely on anatomical landmarks such as the PCA and transepicondylar axis (TEA), but these references may not fully account for individual anatomical variation or soft-tissue balance[5, 6].

With the advent of robotic-assisted TKA, surgeons are able to achieve more precise and reproducible component positioning and, importantly, perform intraoperative adjustments to femoral rotation based on real-time gap balancing and soft-tissue tension[7, 8]. This has facilitated the increasing adoption of functional alignment strategies, in which femoral rotation is actively modified to optimize knee biomechanics. While previous studies have demonstrated that external rotation can improve patellar tracking and reduce lateralizing forces on the patella, its broader biomechanical consequences remain incompletely understood[9, 10]. In particular, it remains unclear whether increasing femoral external rotation may adversely affect anterior compartment stuffing, a phenomenon associated with changes in anterior femoral offset and potential overconstraint of the extensor mechanism[9, 11]. Whether rotational adjustment can simultaneously improve patellofemoral alignment while influencing anterior compartment morphology has not been systematically evaluated. Equally important, the clinical significance of radiographic optimization remains controversial. Although improved patellofemoral alignment is generally considered desirable, evidence linking radiographic improvements to patient-reported outcomes remains inconsistent. Whether intraoperative femoral rotational adjustment translates into superior short-term functional outcomes has not been clearly established.

Therefore, the purpose of this study was to investigate the effects of intraoperative femoral external rotational adjustment on patellofemoral alignment, anterior compartment morphology, soft tissue balancing, and clinical outcomes following robotic-assisted TKA. We hypothesized that greater external

rotational adjustment would improve patellofemoral alignment without substantially altering anterior compartment morphology, would not independently increase soft tissue release requirements after adjustment for deformity severity, and would have limited influence on short-term patient-reported outcomes.

Materials and methods

Patients enrollment

A total of 100 consecutive knees undergoing Mako robotic-assisted primary TKA between January 2023 and November 2025 were retrospectively reviewed. After application of the eligibility criteria (Fig. 1), 84 varus knees were included and categorized into three groups according to the magnitude of intraoperative femoral external rotational adjustment: no adjustment (0°), ≤ 2°, and > 2°. The 2° cutoff was selected as an operational threshold to distinguish minor rotational fine-tuning from more substantial rotational adjustment. This threshold also provided balanced subgroup sizes and allowed clinically interpretable comparisons among no adjustment, minor adjustment, and larger adjustment groups. Although our grouping was based on the magnitude of intraoperative rotational adjustment rather than the final femoral rotation, a threshold of approximately 2° has been reported to be associated with the lowest femoral stuffing in functionally aligned TKA, suggesting that this degree of rotation may also be biomechanically relevant[9]. This retrospective study was approved by the Ethics Committee of China-Japan Friendship Hospital (Approval No. 2025-KY-392). Written informed consent was obtained from all participants before enrollment. All procedures were conducted in accordance with the ethical standards of the institutional research committee and with the 1964 Declaration of Helsinki and its later amendments or comparable ethical standards.

Surgical Technique

The surgical procedure has been described previously[12]. Briefly, preoperative CT data were imported into the MAKO™ robotic system (Stryker, Mahwah, NJ, USA) for three-dimensional planning. All procedures were performed using a standard medial parapatellar approach without patellar resurfacing. Functional alignment planning was adjusted intraoperatively according to robotic gap assessment to achieve balanced flexion and extension gaps while preserving constitutional alignment. Femoral rotational alignment was dynamically modified based on gap balance and soft-tissue tension rather than fixed anatomical landmarks. Trial components were implanted, and knee stability and patellar tracking were reassessed. Selective soft-tissue release was performed only when satisfactory gap balance could not be achieved by component position adjustment alone. Ligament balance was re-evaluated after each release using the robotic navigation system before implantation of the definitive components.

Radiographic assessment

Preoperative and postoperative radiographic assessments were performed using standardized standing radiographs and computed tomography (CT). All measurements were independently performed by two fellowship-trained arthroplasty surgeons blinded to the study groups, and the mean values were used for analysis.

Preoperative assessment included hip–knee–ankle angle (HKA), constitutional alignment phenotype according to the Coronal Plane Alignment of the Knee (CPAK) classification, and native physiological femoral external rotation, defined as the angle between the surgical TEA and PCA on CT. Intraoperative femoral rotational adjustment was calculated as the difference between the final implanted femoral component rotation and the preoperative physiological femoral external rotation.

Postoperative X ray was used to evaluate patellofemoral alignment, including patellar tilt, and lateral patellar displacement. Anterior compartment morphology was assessed using anterior femoral offset (AFO), anterior–posterior diameter (APD), and patellofemoral joint distance (PFJD). As depicted in Fig. 2, we quantified three domains of alignment and morphology. Changes in these parameters (ΔAFO, ΔAPD, and ΔPFJD) were calculated as postoperative minus preoperative values. Based on postoperative anterior compartment morphology, knees were classified as understuffing, neutral filling, or overstuffing according to previously described methods. Understuffing was further analyzed as a binary outcome in multivariable regression analyses.

The intraobserver ICCs ranged from 0.86 to 0.94, and interobserver ICCs ranged from 0.82 to 0.91, indicating good to excellent measurement reliability.

Statistical analysis

Statistical analyses were performed using SPSS version 27.0 (IBM Corp., Armonk, NY, USA). Continuous variables are presented as mean ± SD and categorical variables as frequencies and percentages. Between-group comparisons were performed using one-way ANOVA or the chi-square test, as appropriate. Multivariable linear and binary logistic regression analyses were used to identify independent factors associated with patellofemoral alignment, soft tissue release, and postoperative understuffing. Interobserver and intraobserver reliability were evaluated using ICCs. A two-sided $P < 0.05$ was considered statistically significant.

Results

Patient characteristics

Baseline characteristics were comparable among groups except for preoperative HKA ($P = 0.034$), indicating that greater femoral rotational adjustment was associated with more severe varus deformity (Table 1).

Table 1
Patient characteristics

Variables	No adjustment (n = 26)	≤ 2° adjustment adjustment (n = 33)	> 2° adjustment (n = 25)	P value
Sex (male/female, n)	8/18	8/25	12/13	0.155
Age (years)	67.1 ± 6.6	69.7 ± 4.5	68.0 ± 8.0	0.266
BMI (kg/m²)	28.4 ± 4.3	29.0 ± 4.4	27.3 ± 3.1	0.898
Preoperative HKA (°)	172.6 ± 6.5	170.9 ± 4.7	168.0 ± 7.7	0.034*
Preoperative physiological ER (°)	3.8 ± 1.62	2.8 ± 1.32	3.9 ± 3.3	0.122
CPAK classification (n,%)				
Type I	20 (76.9%)	25 (75.8%)	25 (100%)	0.127
Type IV	2 (7.7%)	3 (9.1%)	0	
Type VII	4 (15.4%)	5 (15.1%)	0	

Data are presented as mean ± standard deviation (SD) or number (percentage), as appropriate. ER, external rotation; HKA, hip–knee–ankle angle; BMI, body mass index; CPAK, coronal plane alignment of the knee.

Radiographic outcomes across ER adjustment groups

Greater femoral rotational adjustment was associated with higher Postoperative femoral rotation relative to PCA ($P < 0.001$), larger changes in APD ($P = 0.023$), and greater improvement in lateral patellar displacement ($P = 0.025$). No significant group differences were observed for postoperative patellar tilt, postoperative lateral patellar displacement, ΔAFO, ΔPFJD, or Δ patellar tilt (all $P > 0.05$)(Table 2).

Table 2
Radiographic outcomes across groups

Variables	No adjustment (n = 26)	≤ 2° adjustment (n = 33)	> 2° adjustment (n = 25)	P value
Postoperative femoral rotation relative to PCA (°)	3.67 ± 1.64[a]	4.1 ± 1.6[b]	6.08 ± 2.44[ab]	< 0.001*
Postoperative Patellar tilt (°)	7.67 ± 3.58	9.1 ± 3.4	8.99 ± 2.83	0.232
Postoperative Lateral patellar displacement (mm)	1.77 ± 5.66	0.15 ± 4.8	−1.42 ± 5.1	0.096
ΔAPD (mm)	−2.1 ± 7.34[ab]	0.74 ± 8.1[a]	−5.21 ± 9.13[b]	0.023*
ΔAFO (mm)	−2.05 ± 2.8	−2.08 ± 4.04	−3.86 ± 3.53	0.11
ΔPFJD (mm)	−5.15 ± 3.07	−4.22 ± 2.63	−4.29 ± 3.26	0.454
ΔPatellar tilt (°)	−1.39 ± 5.34	-1.13 ± 3.28	−0.27 ± 2.8	0.556
ΔLateral displacement (mm)	−0.31 ± 5.74[a]	-2.1 ± 8.38[ab]	−5.38 ± 4.86[b]	0.025*

Values are presented as mean ± standard deviation (SD). Δ indicates the change from preoperative to postoperative measurements. Different superscript letters (a, b, c) indicate statistically significant differences between groups. P values represent overall group comparisons. * $p < 0.05$ indicates statistical significance.

Association between rotational adjustment, deformity severity, and soft tissue release

As shown in Fig. 3, greater femoral rotational adjustment was associated with lower preoperative HKA values, indicating more severe varus deformity (P = 0.034). Post hoc analysis showed significantly lower HKA values in the > 2° adjustment group than in the no-adjustment group.

Soft tissue release rates increased with the magnitude of rotational adjustment, from 23.1% in the no-adjustment group to 33.3% in the ≤ 2° group and 56.0% in the > 2° group (P = 0.044). After Bonferroni correction, only the > 2° adjustment group showed a significantly higher release rate than the no-adjustment group (P = 0.016) (Fig. 3). These findings suggest that greater rotational adjustment is associated with more severe preoperative deformity and a higher likelihood of soft tissue release.

Multivariable regression analyses

Multivariable regression analyses were performed to identify factors associated with patellofemoral alignment, soft tissue release, and postoperative understuffing (Fig. 4). Greater external rotational adjustment was independently associated with reduced lateral patellar displacement (β = −0.150, *P* =

0.043), whereas no association was observed with patellar tilt. ΔAFO was also independently associated with lateral patellar displacement (β = 0.283, *P* < 0.001), while the corresponding preoperative value remained the strongest predictor of both patellofemoral alignment parameters. For soft tissue release, preoperative HKA was the only independent predictor (OR = 0.402, *P* < 0.001). No independent predictors of postoperative understuffing were identified.

Clinical outcomes

WOMAC scores improved substantially in all groups during follow-up. The mean preoperative WOMAC scores ranged from 97.8 to 104.8, decreasing to 77.5–81.3 at 3 months and 69.6–72.7 at 6 months postoperatively. However, no significant differences were identified among the three ER adjustment groups at baseline (P = 0.431), 3 months (P = 0.222), or 6 months (P = 0.181).

Discussion

The present study investigated the clinical significance of individualized femoral external rotational adjustment during robotic-assisted functional alignment TKA. Three principal findings emerged. First, greater external rotational adjustment was independently associated with improved patellofemoral tracking, particularly reduced lateral patellar displacement, without increasing postoperative understuffing. Second, knees requiring greater rotational adjustment demonstrated more severe preoperative varus deformity, while preoperative HKA rather than rotational adjustment independently predicted the need for soft tissue release. Third, despite measurable radiographic improvements, short-term WOMAC outcomes were comparable among the three groups. Together, these findings suggest that individualized femoral rotational adjustment may optimize patellofemoral mechanics while preserving soft-tissue balance and anterior compartment morphology.

Previous studies have consistently demonstrated that femoral component rotation is a key determinant of patellofemoral mechanics, and excessive internal rotation has been associated with patellar maltracking, anterior knee pain, and inferior clinical outcomes[3, 11]. More recently, robotic-assisted TKA and functional alignment have enabled patient-specific component positioning based on dynamic gap balancing rather than fixed anatomical landmarks[13, 14]. However, most previous studies have focused on final rotational alignment or measured-resection techniques, whereas the clinical significance of intraoperative rotational adjustment itself has remained largely unexplored. Furthermore, little is known regarding its relationship with soft tissue release, anterior compartment morphology, and patellofemoral tracking.

The present study extends the current evidence by demonstrating that intraoperative rotational adjustment itself represents a meaningful surgical variable rather than merely a technical modification. We found that individualized external rotational adjustment independently improved lateral patellar tracking without increasing the likelihood of postoperative understuffing. Moreover, although larger rotational adjustments were associated with higher soft tissue release rates in univariate analysis,

multivariable regression demonstrated that preoperative deformity severity rather than rotational adjustment itself determined release requirement. These findings suggest that rotational adjustment should be interpreted as a marker of deformity complexity and an individualized balancing strategy within robotic-assisted functional alignment TKA.

Femoral component rotation is a key determinant of patellofemoral mechanics. Excessive internal rotation has consistently been associated with patellar maltracking, anterior knee pain, and inferior clinical outcomes, whereas appropriate external rotation improves patellofemoral tracking by optimizing trochlear orientation[3, 11, 15]. Consistent with previous studies, external rotational adjustment was independently associated with reduced lateral patellar displacement but not patellar tilt. This suggests that rotational adjustment mainly influences the translational component of patellar tracking, whereas patellar tilt is more dependent on native patellofemoral anatomy and soft-tissue balance. Furthermore, ΔAFO showed a stronger association with lateral patellar displacement than rotational adjustment, indicating that anterior femoral morphology and rotational alignment jointly contribute to patellofemoral mechanics[16–19].

A higher soft tissue release rate was observed in knees requiring greater than 2° of external rotational adjustment. However, this association disappeared after multivariable adjustment, with preoperative HKA emerging as the only independent predictor of release. These findings indicate that greater rotational adjustment does not directly increase the need for soft tissue release but instead reflects more severe preoperative varus deformity. Previous studies have demonstrated that ligament balancing and femoral rotational alignment are closely interconnected during TKA, as soft tissue release alters flexion-gap symmetry while rotational adjustment can be used to optimize residual gap imbalance[13, 20]. Our findings further suggest that, within a robotic-assisted functional alignment workflow, both rotational adjustment and release strategy are primarily determined by deformity severity rather than acting as independent surgical variables.

The present study found no significant association between rotational adjustment and postoperative understuffing. Although excessive modification of femoral component position may theoretically alter anterior compartment morphology, neither rotational adjustment nor preoperative deformity independently predicted understuffing. These findings suggest that controlled external rotational adjustment can improve patellofemoral tracking without substantially compromising anterior compartment morphology. Moreover, radiographic measurements of patellofemoral stuffing mainly reflect static anterior compartment morphology and may not fully capture the dynamic behavior of the patellofemoral joint during knee motion[21–23]. This may partly explain why postoperative understuffing was not independently associated with rotational adjustment in the present study.

Despite improved lateral patellar tracking, WOMAC scores were comparable among the three groups throughout follow-up. This suggests that short-term clinical outcomes after TKA are influenced more by overall pain relief, rehabilitation, and global knee function than by modest improvements in patellofemoral mechanics. In addition, WOMAC may not be sufficiently sensitive to detect subtle

changes in patellofemoral function. Longer-term studies incorporating patellofemoral-specific outcome measures are needed to clarify the clinical significance of rotational adjustment.

Several limitations should be acknowledged. First, this was a retrospective single-center study with a relatively small sample size, particularly after subgroup stratification, which may have limited statistical power. Second, follow-up was limited to 6 months, precluding assessment of long-term clinical and radiographic outcomes. Third, postoperative rotational alignment was evaluated using conventional radiographic measurements rather than CT-based three-dimensional analysis. Finally, WOMAC was the primary clinical outcome measure and may not adequately capture subtle patellofemoral dysfunction. Future prospective studies with larger cohorts, longer follow-up, and patellofemoral-specific outcome measures are warranted.

Conclusions

Femoral external rotational adjustment during robotic-assisted total knee arthroplasty was associated with improved lateral patellar tracking and did not increase the likelihood of soft tissue release or postoperative understuffing. Greater rotational adjustment was more frequently required in knees with severe preoperative varus deformity, whereas deformity severity rather than rotational adjustment independently predicted release requirement. Despite measurable radiographic improvements, short-term clinical outcomes were comparable among groups. These findings support the use of individualized rotational adjustment to optimize patellofemoral alignment without compromising soft tissue balance or anterior compartment morphology.

Declarations

Consent for publication

All authors approved the manuscript for publication, and written informed consent for publication was obtained from all participants.

Informed consent

Informed consent was obtained from the individual participant included in the study.

Ethical Approval

The study was approved by the Ethics Committee of China-Japan Friendship Hospital (2025-KY-392).

Competing interests

The authors declare that they have no conflict of interests.

Funding

This manuscript was supported by grants from Excellence & Innovation Initiative of China-Japan Friendship Hospital (NO. ZRZC2025-XY C01), National High Level Hospital Clinical Research Funding (2025-NHLHCRF-PY-02), National High Level Hospital Clinical Research Funding (2024-NHLHCRF-PYI-01), National Natural Science Foundation of China (52373273).

Author Contribution

Mengran Shen: Investigation Writing – original draft, Visualization, Writing –review & editing, Yuzhu Wu: Writing –review & editing, Hongxu Li: Data analysis, Qihan Ma: Data analysis Bailiang Wang: Supervision Funding acquisition, Resources, Jinhui Ma Conceptualization, Project administration Funding acquisition.

Data Availability

The datasets generated and/or analyzed during the current study are available from the corresponding author on reasonable request.

References

1. Ayati Firoozabadi M, Salkhori O, Razzaghof M, et al. Predicting Femoral Component Rotation in Mechanically Aligned Total Knee Arthroplasty: Can Preoperative Three-Joint Alignment Radiograph Help?[J]. archives bone joint Surg. 2025;13(12):831–8. 10.22038/ABJS.2025.83023.3781.
2. Swartz G, Abdo ZE, Bains SS, et al. Patellar Instability after Total Knee Arthroplasty[J]. J Knee Surg. 2025;38(13):656–61. 10.1055/a-2509-3388.
3. Ko DO, Lee S, Kim JH, et al. The Influence of Femoral Internal Rotation on Patellar Tracking in Total Knee Arthroplasty Using Gap Technique[J]. Clin Orthop Surg. 2021;13(3):352–7. 10.4055/cios20168.
4. Reddy H, Di Gangi C, DeGuzman G, et al. Patello-femoral Tracking Optimization in Robotic-Assisted Total Knee Arthroplasty[J]. J Arthroplast. 2026;S0883–05403. 10.1016/j.arth.2026.03.067.
5. Pujol O, Hinarejos P, Pons A et al. Coronal and rotational femoral anatomy in a Spanish cohort: Anatomical description and surgical implications for total knee arthroplasty[J]. Revista espanola de cirugia ortopedica y traumatologia, 2026:S1888–4415. 10.1016/j.recot.2026.02.006
6. Franceschini V, Nodzo SR, Gonzalez Della Valle A. Femoral Component Rotation in Total Knee Arthroplasty: A Comparison Between Transepicondylar Axis and Posterior Condylar Line Referencing[J]. J Arthroplast. 2016;31(12):2917–21. 10.1016/j.arth.2016.05.032.
7. Zhang J, Ndou WS, Ng N, et al. Robotic-arm assisted total knee arthroplasty is associated with improved accuracy and patient reported outcomes: a systematic review and meta-analysis[J]. Knee

surgery, sports traumatology, arthroscopy. official J ESSKA. 2022;30(8):2677–95. 10.1007/s00167-021-06464-4.

8. Kayani B, Konan S, Tahmassebi J et al. Robotic-arm assisted total knee arthroplasty is associated with improved early functional recovery and reduced time to hospital discharge compared with conventional jig-based total knee arthroplasty: a prospective cohort study[J]. The bone & joint journal, 2018,100-B(7):930–7. 10.1302/0301-620X.100B7.BJJ-2017-1449.R1
9. Maslaris A, Kenanidis E, Mylonakis N, et al. External femoral rotation of 2 degrees is associated with the lowest stuffing rates around the femur in functionally aligned TKA[J]. Knee surgery, sports traumatology, arthroscopy. official J ESSKA. 2025;33(8):2957–70. 10.1002/ksa.12662.
10. Shatrov J, Battelier C, Sappey-Marinier E, et al. Functional Alignment Philosophy in Total Knee Arthroplasty - Rationale and technique for the varus morphotype using a CT based robotic platform and individualized planning[J]. SICOT-J. 2022;8:11. 10.1051/sicotj/2022010.
11. Terashima T, Onodera T, Sawaguchi N, et al. External rotation of the femoral component decreases patellofemoral contact stress in total knee arthroplasty[J]. Knee surgery, sports traumatology, arthroscopy. official J ESSKA. 2015;23(11):3266–72. 10.1007/s00167-014-3103-5.
12. Liu H, Li H, Shen M, et al. Flexion gap discrepancy drives femoral rotational adjustment in robot-assisted TKA: a CPAK-Based phenotypic analysis[J]. BMC Musculoskelet Disord. 2025;26(1):1020. 10.1186/s12891-025-09253-z.
13. Shen M, Li H, Liu H, et al. The impact of soft tissue release on radiological and clinical outcomes in functional alignment robot-assisted total knee arthroplasty[J]. J Orthop Surg Res. 2025;20(1):940. 10.1186/s13018-025-06313-x.
14. Farey JE, Chew J, Wood JA, et al. Does Femoral Component Rotation Matter in Functionally Aligned Total Knee Arthroplasty? The Effect of Deviations From the Transepicondylar Axis on Patient-Reported Outcomes at 1 Year[J]. J Knee Surg. 2026;39(3):145–50. 10.1055/a-2693-0881.
15. Batailler C, Greiner S, Rekik H, et al. Intraoperative patellar tracking assessment during image-based robotic-assisted total knee arthroplasty: technical note and reliability study[J]. SICOT-J. 2024;10:44. 10.1051/sicotj/2024037.
16. O'Bryan E, Jones C, Joseph S. A Novel Robotic Technique for Mapping Patellofemoral Kinematics in Total Knee Arthroplasty[J]. Arthroplasty today. 2025;31:101610. 10.1016/j.artd.2024.101610.
17. Kafelov M, Farhat J, Servien E, et al. New measurement technique for restoration of the trochlear offset after image-based robotic-assisted total knee arthroplasty: a reliability study[J]. SICOT-J. 2023;9:29. 10.1051/sicotj/2023027.
18. Daines BK, Dennis DA. Gap balancing vs. measured resection technique in total knee arthroplasty[J]. Clin Orthop Surg. 2014;6(1):1–8. 10.4055/cios.2014.6.1.1.
19. Diquattro E, Andriollo L, Koutserimpas C, et al. Patellofemoral alignment safe zones in robotic-assisted total knee arthroplasty do not affect outcomes but do influence patellar resurfacing rates[J]. Knee surgery, sports traumatology, arthroscopy. official J ESSKA. 2026;34(1):153–63. 10.1002/ksa.12786.

20. Dlaska C, Ismailidis P, Doma K, et al. Femoral Component Rotation in Total Knee Arthroplasty Using a Tibia-First, Gap-Balancing, Functional Alignment Technique[J]. J Clin Med. 2022;11(22):6680. 10.3390/jcm11226680.
21. Gupton M, Johnson JE, Cummings GR, et al. Overstuffing the patellofemoral compartment in total knee arthroplasty: a systematic review[J]. EFORT open reviews. 2023;8(8):597–605. 10.1530/EOR-22-0107.
22. Kemp MA, Metcalfe AJ, Sayers A, et al. Does overstuffing of the patellofemoral joint in total knee arthroplasty have a significant effect on postoperative outcomes?[J]. Knee. 2018;25(5):874–81. 10.1016/j.knee.2018.05.007.
23. Pierson JL, Ritter MA, Keating EM, et al. The effect of stuffing the patellofemoral compartment on the outcome of total knee arthroplasty[J]. J Bone Joint Surg Am Vol. 2007;89(10):2195–203. 10.2106/JBJS.E.01223.

Figures

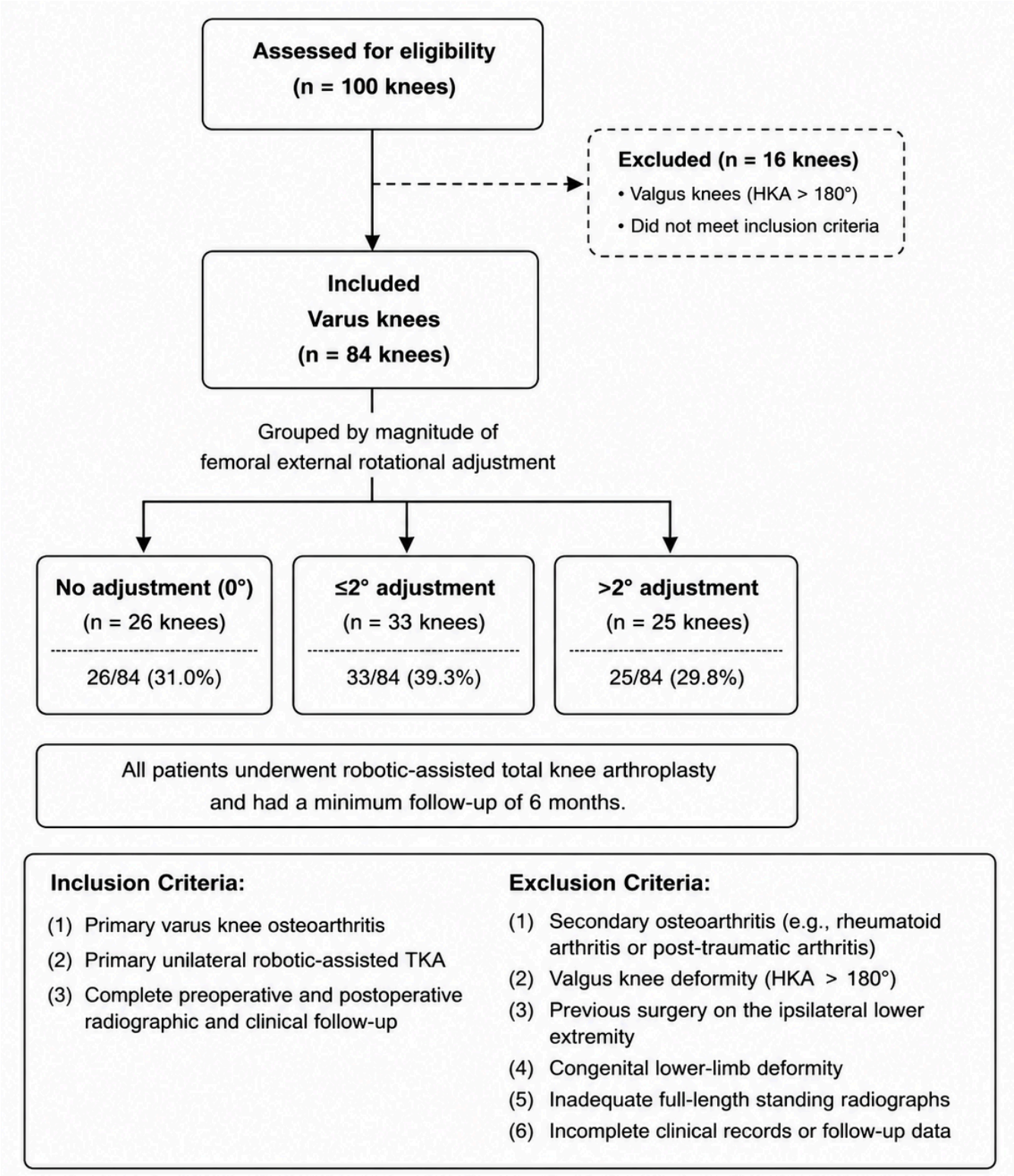

Figure 1

Flowchart of patient enrollment and study grouping.

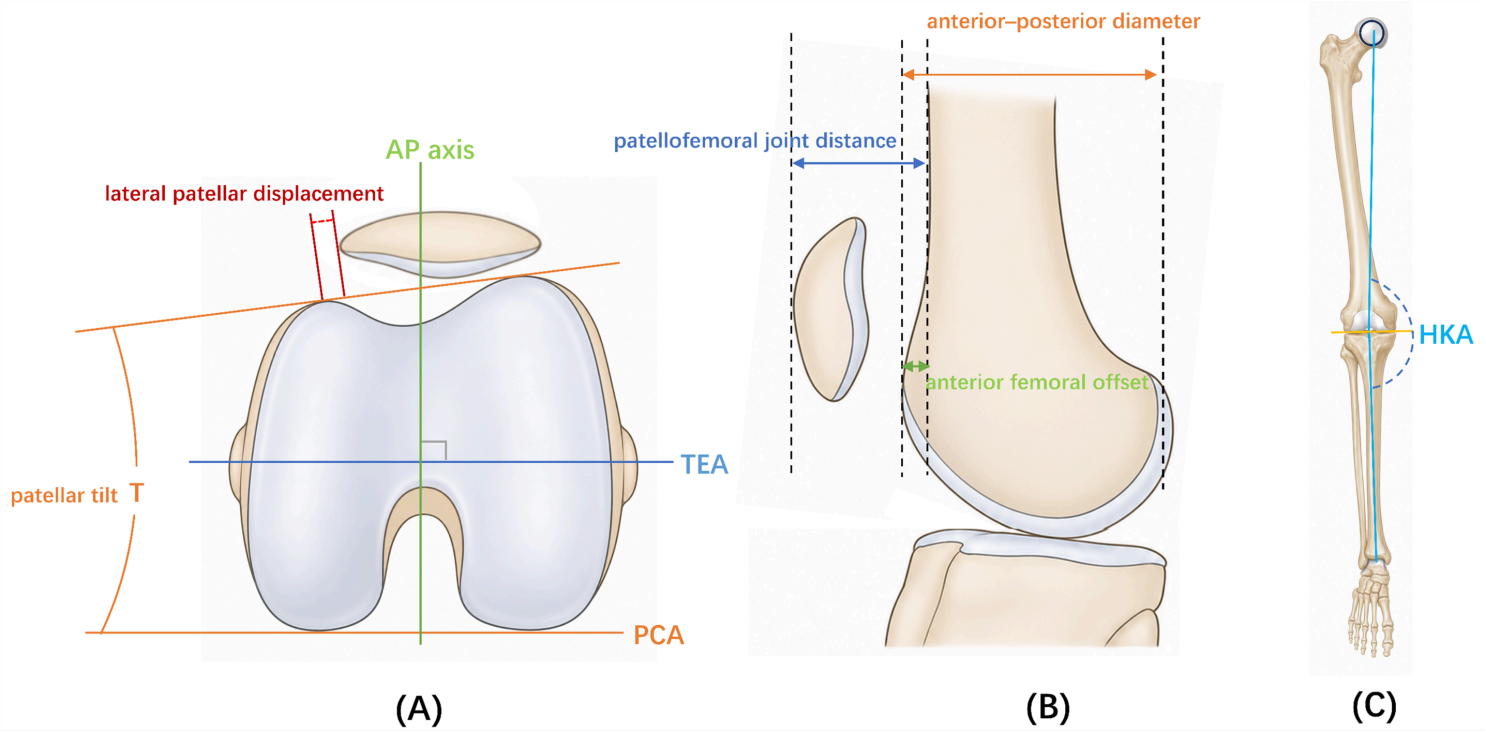

Figure 2

Schematic illustration of radiographic measurements.

(A) Axial view showing the measurement of posterior condylar angle (PCA), patellar tilt, and lateral patellar displacement. The posterior condylar angle (PCA) was defined as the angle between the posterior condylar axis (PCA) and the transepicondylar axis (TEA). Patellar tilt was defined as the angle between the transverse axis of the patella and the posterior condylar axis. Lateral patellar displacement was defined as the perpendicular distance from the median ridge of the patella to the anteroposterior (AP) axis of the femoral trochlea.

(B) Sagittal view showing the measurement of patellofemoral joint (PFJ) distance, anterior femoral offset (AFO), and anterior–posterior diameter (APD). PFJ distance was defined as the horizontal distance between the anterior cortex of the distal femur (or anterior flange after implantation) and the anterior surface of the patella. AFO was defined as the perpendicular distance from the anterior femoral cortex to the most anterior point of the femoral component (or native anterior cortex preoperatively). APD was defined as the maximum anteroposterior diameter of the distal femur.

(C) Coronal view showing the measurement of the hip–knee–ankle angle (HKA), defined as the angle formed by the mechanical axes of the femur and tibia.

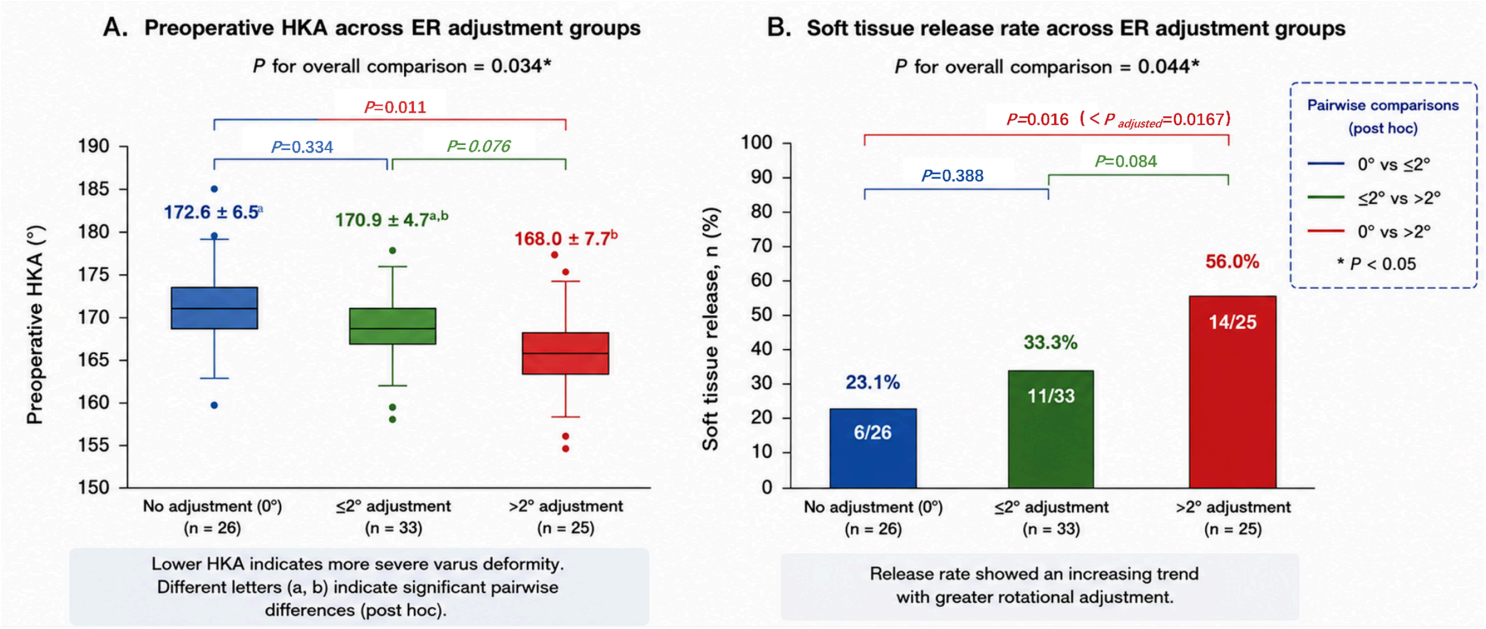

Figure 3

Association between femoral rotational adjustment, preoperative deformity severity, and soft tissue release. **(A)**Comparison of preoperative HKA among the three femoral rotational adjustment groups. Lower HKA values indicate more severe varus deformity. The box plots show the median, interquartile range, and minimum–maximum values. Different superscript letters (**a**, **b**) indicate significant pairwise differences after Bonferroni post hoc analysis. **(B)** Comparison of soft tissue release rates among the three femoral rotational adjustment groups. Bars represent the percentage of knees requiring intraoperative soft tissue release, with the number of released knees shown within each bar. Overall group comparisons were performed using the chi-square test, followed by Bonferroni-adjusted pairwise comparisons. A significantly higher release rate was observed in the >2° adjustment group compared with the no-adjustment group, whereas no significant differences were identified between adjacent groups.

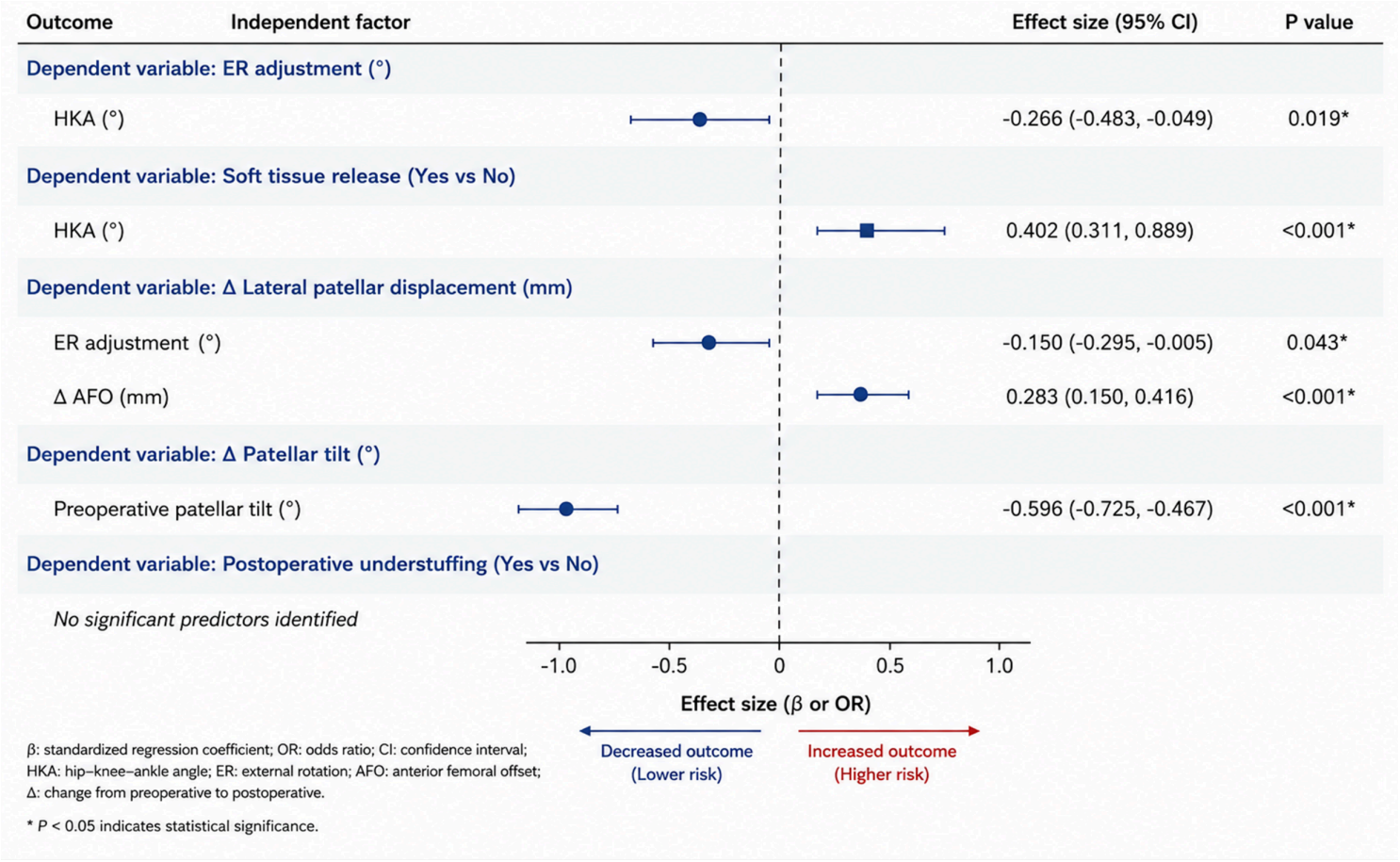

Figure 4

Forest plot of multivariable regression analyses. Each point represents the estimated effect size, and horizontal lines indicate the corresponding 95% confidence interval (CI). Standardized regression coefficients (β) are presented for linear regression models, whereas odds ratios (ORs) are presented for binary logistic regression models. The vertical dashed line represents the null effect (β = 0 for linear regression and OR = 1 for logistic regression). Negative β values indicate a reduction in the outcome variable, whereas ORs <1 indicate a lower likelihood of the outcome.