Research Square

Preprints are preliminary reports that have not undergone peer review. They should not be considered conclusive, used to inform clinical practice, or referenced by the media as validated information.

Unintentional Weight Loss Preceding Relapsing-Remitting Multiple Sclerosis: A Case Report and Review of Possible Mechanisms

Hamid Reza Mohammadi
Shahid Sadoughi University of Medical Sciences
Mohammad Javad Mohammadifard
Shahid Sadoughi University of Medical Sciences
Marzieh Abotorabi-Zarchi
marzie.ab@gmail.com

Shahid Sadoughi Hospital, Shahid Sadoughi Medical School, Shahid Sadoughi University of Medical Sciences

---

Case Report

Keywords: multiple sclerosis, relapsing-remitting multiple sclerosis, weight loss, neuroinflammation, hypothalamic dysfunction, rituximab, case report

Posted Date: October 18th, 2026

DOI: https://doi.org/10.21203/rs.3.rs-10501496/v1

License: This work is licensed under a Creative Commons Attribution 4.0 International License. Read Full License

Additional Declarations: No competing interests reported.

Abstract

Background

Unintentional weight loss is not a recognized presenting feature of multiple sclerosis (MS) and is more commonly associated with malignancy, chronic infection, endocrine disorders, gastrointestinal disease, or systemic inflammatory conditions. We report an unusual case in which marked involuntary weight loss preceded the diagnosis of relapsing-remitting multiple sclerosis (RRMS).

Case Presentation:

A 37-year-old man presented with acute gait impairment and right lower-extremity weakness. Retrospective history revealed gradual unintentional weight loss from approximately 97 kg to 68 kg over nearly two years despite preserved appetite and the absence of gastrointestinal, infectious, endocrine, or constitutional symptoms. Extensive investigations, including laboratory testing, infectious screening, tumor markers, upper gastrointestinal endoscopy, abdominal ultrasonography, and chest imaging, failed to identify an alternative cause. Neurological examination demonstrated right lower-extremity weakness, generalized hyperreflexia, bilateral pyramidal signs, and an Expanded Disability Status Scale (EDSS) score of 4.0. Brain and cervical spinal cord magnetic resonance imaging revealed multiple typical demyelinating lesions fulfilling the 2017 McDonald criteria for MS. The patient received intravenous methylprednisolone followed by rituximab (1000 mg every 6 months). During four years of follow-up, the EDSS score improved from 4.0 to 1.0, MRI studies remained stable, and body weight gradually returned to two years before the start of the disease.

Conclusion

This case describes marked, unexplained weight loss preceding the diagnosis of RRMS, which resolved after treatment initiation and disease stabilization. Although causality cannot be established, the temporal association suggests that clinically significant weight loss may represent an uncommon and underrecognized manifestation of active MS. Further studies are needed to clarify the frequency and mechanisms of weight changes in MS.

Introduction

Multiple sclerosis (MS) is a chronic inflammatory demyelinating disease of the central nervous system (CNS) and a leading cause of neurological disability in young adults. Its clinical manifestations include sensory disturbances, motor weakness, optic neuritis, and cerebellar dysfunction. In contrast, unexplained weight loss is not generally considered a presenting feature of MS and more often prompts evaluation for alternative diagnoses such as malignancy, chronic infection, systemic inflammatory conditions, and others.(1, 2).

The pathogenesis of MS involves complex interactions between adaptive and innate immune responses that contribute to demyelination and neuroaxonal injury. Some of these inflammatory pathways have also been implicated in systemic metabolic alterations and the regulation of body weight in chronic inflammatory disorders. In addition, emerging evidence suggests that neuroinflammatory processes may influence central mechanisms involved in appetite regulation, energy expenditure, and neuroendocrine function. However, the clinical significance of these mechanisms in patients with MS remains poorly understood.(2, 3).

Although weight changes may occur during the course of MS as a consequence of disability, treatment effects, or lifestyle factors, clinically significant involuntary weight loss preceding the onset of overt neurological manifestations has been reported only rarely. Consequently, marked unexplained weight loss is not generally regarded as a feature suggestive of underlying MS and often leads clinicians to investigate alternative systemic causes. (4).

We report the case of a 37-year-old man with active relapsing-remitting multiple sclerosis (RRMS) who experienced progressive unexplained weight loss, beginning nearly two years before the development of overt neurological symptoms. Body weight gradually returned to the patient's premorbid baseline. This case highlights an unusual presentation of MS and raises the possibility that substantial weight loss may represent an underrecognized manifestation of active neuroinflammatory disease in a subset of patients.

Case Presentation

A 37-year-old male industrial worker was referred to our neurology clinic in June 2022 because of acute worsening of gait impairment and right lower-extremity weakness resulting in significant ambulatory limitation. He had no history of smoking, alcohol consumption, or illicit drug use. His medical history was otherwise unremarkable, and there was no family history of multiple sclerosis (MS), autoimmune disease, malignancy, or neurological disorders.

A notable feature of the clinical history was progressive involuntary weight loss that preceded the diagnosis of MS. According to the patient, his habitual body weight had been approximately 97 kg for two years before symptom onset, despite preserved appetite and unchanged dietary habits. At the time of neurological evaluation, his weight had declined to 68 kg, representing a total loss of approximately 29 kg (30% of baseline body weight). Extensive investigations performed during this period failed to identify an underlying cause. The temporal relationship between progressive weight loss and the subsequent emergence of neurological manifestations represents the principal novel aspect of this case. A brief summary of the patient's clinical course is presented in Table 1.

The patient reported that approximately two years before presentation, he had intermittent discomfort and subjective heaviness in the lower extremities associated with mild gait difficulty. However, he did not recall any clearly defined neurological attack or persistent neurological deficit during this period, nor any prior medical documentation. A retrospective review of the clinical history suggested that the

progressive weight loss occurred during the same period as the subtle neurological symptoms. He denied reduced caloric intake, excessive physical activity, dysphagia, odynophagia, nausea, vomiting, diarrhea, abdominal pain, fever, night sweats, cough, respiratory symptoms, polyuria, polydipsia, heat intolerance, tremor, excessive sweating, or other constitutional complaints.

Physical examination demonstrated a body weight of 68 kg and a height of 170 cm, corresponding to a body mass index (BMI) of 23.5 kg/m². The patient was not cachectic, chronically ill-appearing, or malnourished. Vital signs were normal. General examination, including cardiovascular, respiratory, abdominal, dermatological, musculoskeletal, and peripheral vascular assessments, was unremarkable. No clinically apparent muscle wasting or sarcopenia was observed.

Neurological examination revealed normal mental status and intact cranial nerve function. Motor examination demonstrated Medical Research Council grade 3/5 weakness in the right lower extremity. Generalized hyperreflexia was present together with bilateral Hoffmann and Babinski signs. Gait examination demonstrated a hemiparetic pattern. Sensory and left-sided cerebellar examinations were otherwise unremarkable. The Expanded Disability Status Scale (EDSS) score at presentation was 4.0.

Laboratory investigations included complete blood count, fasting blood glucose, erythrocyte sedimentation rate, C-reactive protein, serum electrolytes, renal function tests, liver function tests, lactate dehydrogenase, thyroid-stimulating hormone, free thyroxine, urinalysis, and antinuclear antibody testing, all of which were within normal limits. Screening for HIV, hepatitis B virus, hepatitis C virus, latent tuberculosis, and other chronic infections was negative.

Additional metabolic investigations were unrevealing. Glycated hemoglobin (HbA1c) was 5.3% (reference range 4.0–5.6%). Serum albumin was 4.4 g/dL (reference range 3.5–5.0 g/dL).

Because of the substantial unexplained weight loss, extensive investigations had been performed before neurological referral. Evaluation for occult malignancy was guided by the patient's age, sex, and clinical presentation. It included serum alpha-fetoprotein (AFP) 2.8 ng/mL (normal < 10 ng/mL), carcinoembryonic antigen (CEA) 1.6 ng/mL (normal < 5 ng/mL), carbohydrate antigen 19 – 9 (CA19-9) 12 U/mL (normal < 37 U/mL), prostate-specific antigen (PSA) 0.8 ng/mL (normal < 4 ng/mL), and beta-human chorionic gonadotropin (β-hCG) < 2 mIU/mL, all of which were within normal limits. Abdominal and pelvic ultrasonography revealed no abnormalities, and upper gastrointestinal endoscopy was normal. Chest radiography and computed tomography of the thorax demonstrated no evidence of pulmonary malignancy, granulomatous disease, or other clinically significant abnormalities. No evidence of malignancy, chronic infection, endocrine disease, gastrointestinal pathology, or systemic inflammatory disease was identified.

Adrenal insufficiency was considered clinically unlikely because the patient denied anorexia, fatigue, orthostatic symptoms, hyperpigmentation, gastrointestinal complaints, or other manifestations suggestive of adrenal failure. Serum electrolytes were normal. Consequently, serum cortisol and adrenocorticotropic hormone measurements were not obtained.

MRI Findings

Brain MRI demonstrated multiple T2/FLAIR hyperintense lesions involving characteristic locations for multiple sclerosis, including the periventricular white matter, corpus callosum (Dawson's fingers), and infratentorial regions. Non-contrast T1-weighted sequences demonstrated multiple hypointense lesions ("black holes"), suggestive of chronic tissue injury. Cervical spinal cord MRI revealed two short-segment T2-hyperintense lesions consistent with demyelination (Fig. 1).

The involvement of the periventricular, callosal, infratentorial, and spinal cord regions fulfilled dissemination in space according to the 2017 McDonald criteria. In addition, post-contrast T1-weighted imaging demonstrated two gadolinium-enhancing lesions, while several other lesions were non-enhancing, thereby fulfilling dissemination in time.

Because the patient presented with a typical clinical syndrome and characteristic MRI findings that fulfilled both dissemination in space and dissemination in time according to the 2017 McDonald criteria, the diagnosis of multiple sclerosis could be established on clinical and radiological grounds. Cerebrospinal fluid examination was therefore not considered necessary, as there were no atypical clinical or radiological features suggesting an alternative diagnosis, central nervous system infection, or another inflammatory disorder that would require additional diagnostic evaluation.

Based on the characteristic clinical presentation, typical MRI findings, fulfillment of the 2017 McDonald criteria, and exclusion of alternative diagnoses, a diagnosis of relapsing-remitting multiple sclerosis was established.

Serial follow-up brain MRI studies demonstrated radiological stability, with no new lesions, no lesion enlargement, and no gadolinium-enhancing lesions. FLAIR sequences showed a reduction in lesion size at several locations compared with baseline imaging. These findings were consistent with sustained suppression of inflammatory disease activity during treatment (Fig. 2).

Therapeutic Intervention

Therapeutic Intervention
The patient received intravenous methylprednisolone 1 g daily for five consecutive days. Marked clinical improvement was observed following corticosteroid treatment. Given the patient's male sex, prominent motor disability, cervical spinal cord involvement, and high lesion burden on MRI, initiation of a high-efficacy disease-modifying therapy was recommended.

Ocrelizumab and natalizumab were not financially accessible because of insurance limitations. Therefore, rituximab was selected in accordance with the regional guideline.(5) and administered at a dose of 1000 mg intravenously every six months.

Before treatment initiation, screening for HIV, hepatitis B, hepatitis C, and latent tuberculosis was negative. Varicella-zoster virus IgG was positive, indicating prior immunity. Baseline complete blood count, liver function tests, and serum immunoglobulin G levels were within normal limits. Standard premedication was administered before each infusion. No infusion-related adverse events occurred during treatment.

Follow-Up and Outcomes

The patient demonstrated substantial neurological recovery following treatment initiation. Serial neurological examinations and follow-up MRI studies showed sustained clinical and radiological stability without relapses, disability progression, new lesions, enlarging lesions, or evidence of ongoing inflammatory activity.

A parallel improvement in body weight was observed during follow-up. Body weight increased from 68 kg at diagnosis to 85 kg after six months and reached 97 kg after 12 months. According to the patient, this corresponded closely to his habitual premorbid weight before the onset of unexplained weight loss, suggesting restoration toward baseline body weight rather than excessive treatment-related weight gain.

No corticosteroid exposure occurred beyond the initial 5-day methylprednisolone course, and the patient denied the use of appetite stimulants, anabolic agents, weight-gain supplements, or intentional dietary measures aimed at increasing body weight. Vitamin D supplementation (50,000 IU every two weeks) was the only concomitant medication.

After regaining his baseline weight, the patient elected to pursue weight reduction through dietary counseling, increased physical activity, and regular exercise. Body weight subsequently decreased gradually to approximately 80 kg and remained stable between 79 and 81 kg throughout subsequent follow-up. Therefore, the later reduction in body weight was considered a deliberate lifestyle-related change rather than a recurrence of the unexplained weight loss that preceded MS diagnosis.

At the most recent neurological assessment in May 2026, cranial nerve, motor, sensory, cerebellar, and gait examinations were normal. Generalized hyperreflexia and bilateral Babinski responses persisted as residual pyramidal signs. The EDSS score improved from 4.0 at diagnosis to 1.0. Complete blood count, liver function tests, and annual serum immunoglobulin G measurements remained within normal limits throughout follow-up. No serious infections, hypogammaglobulinemia, infusion-related complications, relapses, disability progression, or emergence of an alternative diagnosis capable of explaining the preceding profound weight loss were observed during approximately four years of follow-up.

Notably, the patient's profound unexplained weight loss began approximately two years before diagnosis and resolved following treatment initiation and sustained suppression of disease activity, without identification of any alternative explanatory condition during long-term follow-up.

Table 1
Clinical Timeline

Date	Clinical Event	Weight
~ 1400	Beginning of gradual, unexplained weight loss	97 kg
~ 1400–1401	Mild intermittent gait difficulty and paresthesia	Progressive decline
07/03/1401	Definite neurological deterioration	68 kg
21/03/1401	Neurology clinic evaluation	68 kg
22/03/1401	IV methylprednisolone 1 g/day × 5 days	68 kg
29/03/1401	First rituximab 1000 mg infusion	68 kg
30/09/1401	Second rituximab infusion	85 kg
30/03/1402	Third rituximab infusion	97 kg
31/06/1402	Lifestyle modification initiated	90 kg
30/03/1403	Fifth rituximab infusion	85 kg
30/06/1403	Sixth rituximab infusion	81 kg
1403–1405	Continued rituximab every 6 months	79–81 kg
10/03/1405	Most recent follow-up	80–81 kg

Discussion

Unintentional weight loss is not traditionally considered a clinical feature of multiple sclerosis (MS) and typically prompts investigation for malignancy, chronic infection, endocrine disorders, gastrointestinal disease, or systemic inflammatory conditions. In the present case, profound involuntary weight loss of approximately 29 kg (30% of baseline body weight) began nearly two years before the diagnosis of relapsing-remitting MS and remained unexplained despite extensive evaluation. Moreover, body weight gradually returned to the patient's premorbid baseline following treatment initiation and long-term suppression of disease activity, without emergence of an alternative diagnosis during approximately four years of follow-up. The temporal association between substantial weight loss, subsequent diagnosis of active MS, and later weight recovery represents the principal novel observation of this report.

The biological mechanisms underlying this observation remain uncertain. One potential explanation involves chronic inflammatory cachexia. Although conventional systemic inflammatory markers such as erythrocyte sedimentation rate and C-reactive protein are often normal in MS, neuroinflammatory activity is characterized by activation of both innate and adaptive immune pathways and increased production of pro-inflammatory cytokines, including tumor necrosis factor-alpha (TNF-α), interleukin-1 beta (IL-1β), and interleukin-6 (IL-6). These cytokines have established roles in appetite regulation, skeletal muscle catabolism, and energy expenditure, and are recognized mediators of cachexia in several chronic

inflammatory disorders. Experimental and clinical studies have demonstrated that TNF-α promotes proteolysis and muscle wasting, whereas IL-1β and IL-6 contribute to anorexigenic signaling and hypermetabolic states.(6). Importantly, clinically significant weight loss may occur despite relatively preserved caloric intake, suggesting that increased catabolism and altered metabolic efficiency may contribute to negative energy balance. Although cytokine levels were not measured in the present patient, and no validated inflammatory biomarker is routinely used for diagnosis or monitoring of MS, persistent neuroinflammatory activity preceding diagnosis may theoretically have contributed to the observed weight loss.(7–9).

A second and potentially more compelling hypothesis involves hypothalamic dysfunction. The hypothalamus plays a central role in appetite regulation, satiety signaling, energy expenditure, and neuroendocrine homeostasis. Although hypothalamic lesions are not among the most common MRI findings in MS, and no visible hypothalamic lesion was identified in our patient, the absence of overt structural abnormalities does not exclude functional involvement. The MRI studies were performed using a 1.5-T scanner with conventional two-dimensional sequences, which have limited sensitivity for detecting small hypothalamic lesions compared with modern three-dimensional and 3T OR 7 T imaging techniques. Furthermore, accumulating evidence indicates that functional abnormalities may occur within normal-appearing brain tissue in MS, including deep gray matter structures that appear structurally intact on conventional MRI. Previous studies have also demonstrated abnormalities of hypothalamic-pituitary-adrenal axis regulation and neuroendocrine function in patients with MS. Consequently, we hypothesize that subclinical hypothalamic dysfunction may have contributed to altered energy homeostasis during the prolonged period of active disease preceding diagnosis. The subsequent normalization of body weight following disease control may indirectly support this possibility. However, this interpretation remains speculative because dedicated hypothalamic imaging, functional MRI, autonomic testing, and endocrine dynamic studies were not available in this case.(9, 10).

Another possible explanation is increased energy expenditure associated with chronic neurological dysfunction. Retrospective history revealed intermittent gait disturbance and lower-extremity symptoms for nearly two years before diagnosis, suggesting that inflammatory disease activity may have been present well before the clinically recognized relapse. Although objective metabolic measurements were not performed, prolonged subclinical neurological dysfunction may have contributed to a chronic negative energy balance and progressive weight loss.(1, 11).

An additional noteworthy observation was the temporal association between treatment initiation, neurological stabilization, and recovery of body weight. Weight restoration occurred after a short course of intravenous methylprednisolone, initiation of rituximab therapy, and subsequent suppression of inflammatory disease activity. The relative contribution of these factors cannot be determined. However, prolonged corticosteroid exposure was absent, and weight recovery persisted long after the expected duration of steroid-related metabolic effects. Although this observation does not establish causality, it raises the possibility that control of neuroinflammatory activity may have contributed to the normalization of body-weight regulation.(12).

The principal strength of this report is the extensive exclusion of alternative causes of weight loss, together with prolonged follow-up demonstrating sustained clinical and radiological stability without emergence of another explanatory diagnosis. Several limitations should nevertheless be acknowledged. First, the history of weight loss was obtained retrospectively. Second, cytokine measurements, metabolic studies, autonomic testing, and advanced neuroimaging techniques were unavailable. Third, formal evaluation of adrenal function, including cortisol and adrenocorticotropic hormone measurements, was not performed, although adrenal insufficiency was considered clinically unlikely. Finally, cerebrospinal fluid examination was not obtained because the diagnosis was established on clinical and radiological grounds according to the 2017 McDonald criteria.

Conclusion

This case describes marked unexplained involuntary weight loss of approximately 29 kg, beginning nearly two years before the diagnosis of relapsing-remitting multiple sclerosis and resolving after treatment initiation and sustained disease stabilization. Extensive investigations excluded malignant, infectious, endocrine, gastrointestinal, and other systemic causes of weight loss. Although a causal relationship cannot be established from a single case, the temporal association between active MS, profound weight loss, and subsequent recovery of body weight raises the possibility that clinically significant weight loss may represent an uncommon and underrecognized manifestation of neuroinflammatory disease in a subset of patients with MS. Clinicians should remain aware of this potential association when evaluating patients with otherwise unexplained weight loss who later develop neurological symptoms suggestive of demyelinating disease. Further studies are needed to determine the frequency, clinical significance, and underlying biological mechanisms of weight changes in MS.

Declarations

Ethics approval and consent to participate:

This case report was conducted in accordance with the ethical standards of the Shahid Sadoughi University of Medical Sciences and with the 1964 Helsinki Declaration and its later amendments. Written informed consent was obtained from the patient for participation in this study. Ethical approval Code: IR.SSU.MEDICINE.REC.1405.135

Consent for publication:

Written informed consent was obtained from the patient for publication of this case report and any accompanying images. A copy of the written consent is available for review by the Editor-in-Chief of this journal.

Competing interests:

The authors declare that they have no competing interests.

Mohammad Javad Mohammadifard

Participated in clinical management, data collection, and manuscript revision.

Marzie Abutorabi-Zarchi

Conceptualized the case report, performed critical revision of the manuscript, and is the corresponding author.

Funding:

Not applicable

Author Contribution

Authors' contributions:Hamid Reza Mohammadi: Participated in clinical management, data collection, and manuscript revision.Mohammad Javad Mohammadifard: Participated in clinical management, data collection, and manuscript revision.Marzie Abutorabi-Zarchi: Conceptualized the case report, performed critical revision of the manuscript, and is the corresponding author.All authors read and approved the final manuscript.

Acknowledgement

The authors would like to acknowledge the staff of the Department of Internal Medicine, Shahid Sadoughi University of Medical Sciences, for their assistance in patient care and support during the preparation of this report. Additionally, the authors acknowledge the use of ChatGPT (OpenAI) for assistance with paraphrasing and grammar checking of the manuscript.

Data Availability:

The data supporting the findings of this case report are available from the corresponding author upon reasonable request. All relevant data are included within the article.

References

1. Hardiman O, van den Berg LH. The Beginning of Genomic Therapies for ALS. N Engl J Med. 2020;383(2):180–1.
2. Kantorová E, Poláček H, Bittšanský M, Baranovičová E, Hnilicová P, Čierny D, et al. Hypothalamic damage in multiple sclerosis correlates with disease activity, disability, depression, and fatigue.

Neurol Res. 2017;39(4):323–30.

3. Delaney C, Wright RH, Tang JR, Woods C, Villegas L, Sherlock L, et al. Lack of EC-SOD worsens alveolar and vascular development in a neonatal mouse model of bleomycin-induced bronchopulmonary dysplasia and pulmonary hypertension. Pediatr Res. 2015;78(6):634–40.
4. Cardoso D, Särkinen T, Alexander S, Amorim AM, Bittrich V, Celis M, et al. Amazon plant diversity revealed by a taxonomically verified species list. Proc Natl Acad Sci U S A. 2017;114(40):10695–700.
5. Yamout B, Sahraian M, Bohlega S, Al-Jumah M, Goueider R, Dahdaleh M, et al. Consensus recommendations for the diagnosis and treatment of multiple sclerosis: 2019 revisions to the MENACTRIMS guidelines. Mult Scler Relat Disord. 2020;37:101459.
6. Banks WA. The blood-brain barrier in psychoneuroimmunology. Neurol Clin. 2006;24(3):413–9.
7. Argilés JM, Busquets S, Stemmler B, López-Soriano FJ. Cancer cachexia: understanding the molecular basis. Nat Rev Cancer. 2014;14(11):754–62.
8. Glass CK, Olefsky JM. Inflammation and lipid signaling in the etiology of insulin resistance. Cell Metab. 2012;15(5):635–45.
9. Huitinga I, Erkut ZA, van Beurden D, Swaab DF. The hypothalamo-pituitary-adrenal axis in multiple sclerosis. Ann N Y Acad Sci. 2003;992:118–28.
10. Brown DG, Round JL. Friends in Low Places: Intestinal Commensals Limit Colitis through Molecular Mimicry. Cell. 2017;171(3):503–5.
11. Pihl M, Arvidsson A, Skepö M, Nilsson M, Givskov M, Tolker-Nielsen T, et al. Biofilm formation by Staphylococcus epidermidis on peritoneal dialysis catheters and the effects of extracellular products from Pseudomonas aeruginosa. Pathog Dis. 2013;67(3):192–8.
12. Inoue A, Ohnishi T, Kohno S, Harada H, Nishikawa M, Ozaki S, et al. Utility of three-dimensional computed tomography for anatomical assistance in endoscopic endonasal transsphenoidal surgery. Neurosurg Rev. 2015;38(3):559–65.

Figures

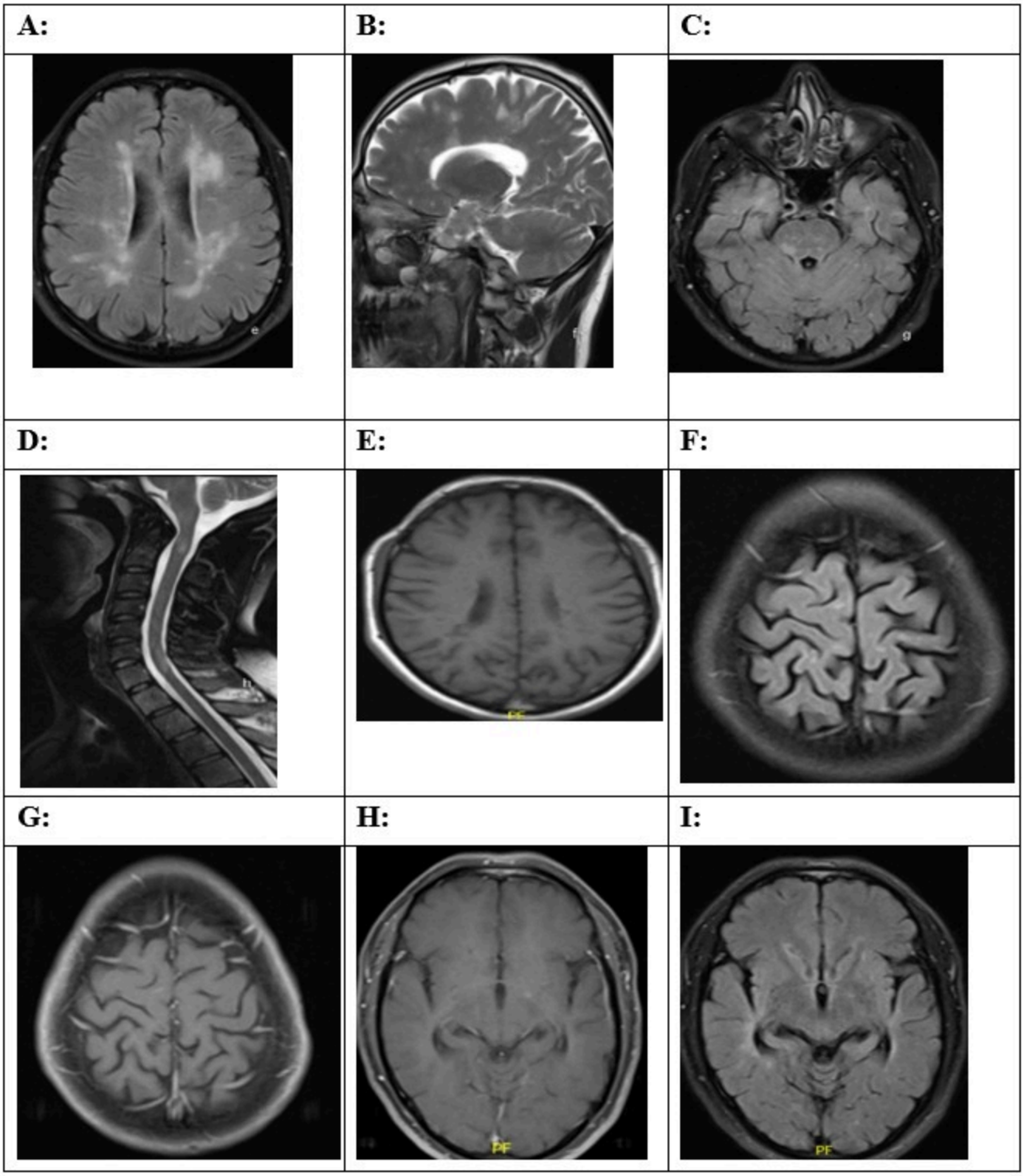

Figure 1

Baseline brain and cervical spinal cord MRI (2021)

Note: FLAIR (axial) and T2 (sagittal) brain MRI sequences show multiple lesions in the periventricular and callosal (Dawson's finger sign) (e&f) and infratentorial (g). Axial T2 sequences of Cervical cord MRI show two short-segment lesions (h). T1 axial sequence brain MRI without contrast shows multiple black

hole lesions (j). Brain T1 with contrast MRI shows two lesions that had enhancement with gadolinium (i&k) along with their corresponding FLAIR T2

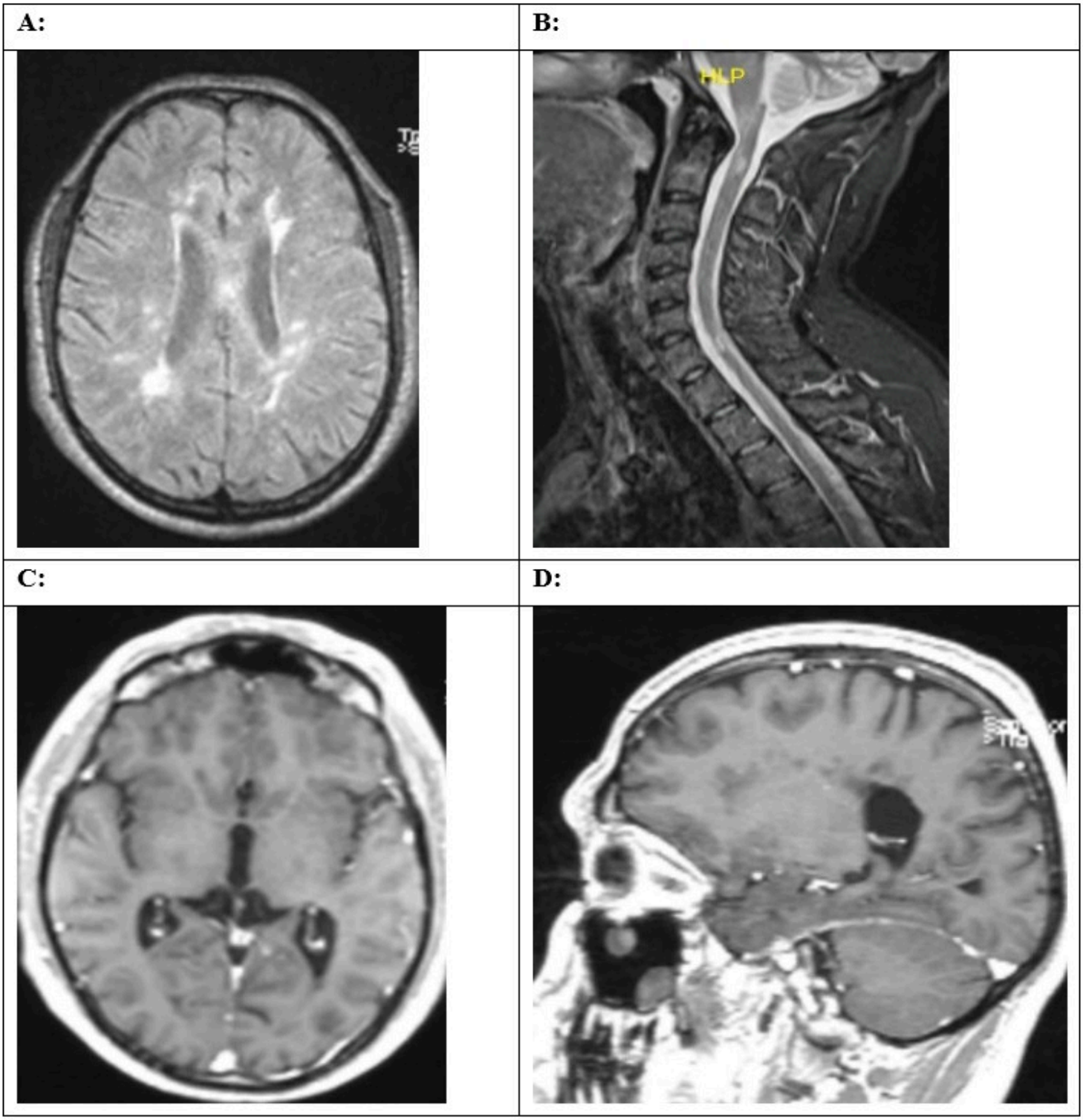

Figure 2

Follow-up brain and spinal cord MRI (2026)

Note: Flair axial sequence of brain MRI and T2 sagittal sequence of cervical MRI show no increase in size and volume of lesions, and the size of lesions decreases in some locations(a&b). T1 (axial and sagittal) sequence brain MRI without contrast doesn't show any enhancing lesions (c&d). (2026)