Research Square

Preprints are preliminary reports that have not undergone peer review.
They should not be considered conclusive, used to inform clinical practice,
or referenced by the media as validated information.

Bardet–Biedl Syndrome Presenting with Pelviureteric Junction Obstruction and a Contralateral Renal Cortical Cyst: A Rare Renal Phenotype Diagnosed Clinically in a Resource-Limited Setting

Iftekhar Ahmed Sakib
Shaheed Suhrawardy Medical College
Bandhan Chandra Mondal
bandhanm93@gmail.com
Manikganj Medical College
Atika Tabassum Fariha
Manikganj Medical College

Case Report

Keywords: Bardet–Biedl syndrome, Pelviureteric junction obstruction, Retinitis pigmentosa, Resource-limited setting, Case Report

Posted Date: November 26th, 2026

DOI: https://doi.org/10.21203/rs.3.rs-10501083/v1

License: This work is licensed under a Creative Commons Attribution 4.0 International License.
Read Full License

Additional Declarations: No competing interests reported.

Abstract

Background

Bardet–Biedl syndrome (BBS) is a rare autosomal recessive ciliopathy characterized by rod–cone dystrophy, postaxial polydactyly, obesity, learning disability, renal anomalies, and genital abnormalities. Renal disease is the leading cause of long-term morbidity and mortality, although pelviureteric junction (PUJ) obstruction is rarely described as part of the renal phenotype. We report a young woman with previously undiagnosed BBS who presented with PUJ obstruction and a contralateral renal cortical cyst in a resource-limited setting.

Case Presentation

A 22-year-old Bangladeshi woman presented with a two-month history of severe right-sided abdominal pain (in the right lumbar region) and recurrent vomiting. Clinical examination revealed truncal obesity, bilateral postaxial polydactyly with childhood excision scars on both hands, brachydactyly, a high-arched palate, mild hirsutism, and severe visual impairment. History disclosed childhood-onset obesity, developmental delay, progressive nyctalopia, and oligomenorrhoea. Laboratory evaluation demonstrated elevated serum creatinine (2.27 mg/dL). Ultrasonography showed right PUJ obstruction with mild pelvicalyceal dilatation and a solitary cortical cyst in the left kidney. Dilated fundoscopy confirmed bilateral rod–cone dystrophy. The patient fulfilled five primary and four secondary modified Beales criteria, establishing a definitive clinical diagnosis of BBS despite the unavailability of molecular testing. She received conservative management and was referred for definitive urological intervention and long-term nephrological follow-up.

Conclusions

This case highlights an uncommon renal presentation of BBS and underscores the diagnostic value of careful clinical assessment where genetic testing is unavailable. Early recognition of potentially correctable urinary tract obstruction in patients with BBS may help preserve renal function and improve long-term outcomes.

Key clinical message

Bardet–Biedl syndrome should be suspected in any young patient with postaxial polydactyly, early visual loss and a structural renal anomaly such as pelviureteric junction obstruction. Diagnosis using standardised clinical criteria is achievable without genetic testing and enables timely nephroprotective and urological intervention that may delay progression to kidney failure.

Background

Bardet–Biedl syndrome is a rare autosomal recessive, pleiotropic disorder belonging to the family of human ciliopathies. Its pathogenesis lies in structural or functional failure of the non-motile primary cilium, an organelle that coordinates a wide range of signal transduction pathways in almost every cell type [1]. Reported prevalence is approximately 1 in 140,000 to 1 in 160,000 live births in European and North American populations but is substantially higher in geographically or culturally isolated communities in which consanguineous union is frequent, such as the Bedouin of Kuwait (1 in 13,500) and the population of Newfoundland (1 in 17,500) [2, 3, 4].

The syndrome shows striking inter- and intra-familial phenotypic variability. Its cardinal features are rod–cone dystrophy, postaxial polydactyly, obesity, learning disability, renal anomalies and hypogonadism in males or genital abnormalities in females [5]. Of these, renal involvement is the principal determinant of long-term outcome and an important cause of premature death [6]. The structural renal lesions described in BBS include fetal lobulation, calyceal clubbing and cysts, renal dysplasia, cortical cysts and tubular ectasia, together with a characteristic defect of urinary concentration [7].

Early recognition remains difficult, particularly in rural low-resource settings where molecular testing is unavailable and where the individual childhood manifestations — an extra digit removed in infancy, poor progress at school, difficulty seeing at dusk — are managed in isolation and never assembled into a unifying diagnosis. Affected individuals therefore frequently present for the first time in adult life, with established organ damage or an acute complication.

We report a 22-year-old woman from rural Bangladesh who presented with acute pain in the right lumbar region of the abdomen arising from pelviureteric junction (PUJ) obstruction, with a contralateral upper-pole renal cortical cyst, on a background of previously undiagnosed BBS. The case illustrates the diagnostic sufficiency of standardised clinical criteria, the importance of screening for structural urinary tract malformation in the ciliopathies, and the practical constraints of care in a resource-limited health system. The report is presented in accordance with the CARE (CAse REport) guidelines [8, 9].

Case Presentation

Patient information and presenting complaint

A 22-year-old female from a rural district of Bangladesh presented to the outpatient department of a tertiary care hospital with a two-month history of severe right-sided abdominal pain. The pain had begun suddenly, was colicky and constant, and was localised to the right lumbar region of the abdomen without radiation. It was aggravated by ordinary physical movement and had not responded to self-administered oral paracetamol. It was accompanied by recurrent episodes of non-bilious, non-projectile vomiting.

She was born at term by uncomplicated vaginal delivery to non-consanguineous parents, following a pregnancy that had not been monitored. There was no family history of visual impairment, congenital

structural anomaly, early-onset renal disease or sudden unexplained death, and no sibling was similarly affected.

Developmental, ophthalmic and systemic history

Retrospective history disclosed progressive truncal obesity beginning at 4 years of age. Global developmental delay had been evident in early childhood: she walked independently only after 24 months, used single words after 24 months, and achieved phrase speech only after 4 years. Learning disability was apparent as persistently poor scholastic performance and difficulty executing complex activities of daily living.

Ophthalmic symptoms began at 5 years of age with progressive nyctalopia, followed by gradual constriction of the peripheral visual fields, which severely impaired independent navigation in low light. She had been born with postaxial hexadactyly affecting all four limbs; the supernumerary ulnar digits of both hands were surgically excised at 10 years of age, while those of the feet were left in situ. She also reported a two-year history of oligomenorrhoea with irregular, prolonged cycles. The chronological sequence of events is summarised in Table 1.

Table 1
Chronological timeline of clinical events.

Age / period	Clinical event or milestone
Birth	Born at term to non-consanguineous parents after an unmonitored pregnancy. Congenital postaxial hexadactyly involving all four limbs.
12–24 months	Delayed gross motor and early language milestones; independent walking and first single words achieved only after 24 months.
4 years	Onset of progressive truncal obesity; phrase speech achieved only after this age.
5 years	Onset of nyctalopia, followed by progressive constriction of the peripheral visual fields.
School age	Persistently poor scholastic performance; difficulty with complex activities of daily living.
10 years	Surgical excision of the supernumerary ulnar digits of both hands; pedal supernumerary digits retained.
20 years	Onset of oligomenorrhoea with irregular, prolonged menstrual cycles.
2 months before admission	Sudden onset of severe, constant, colicky pain in the right lumbar region of the abdomen with recurrent non-bilious vomiting; no relief from oral paracetamol.
Admission (day 0)	Clinical examination, laboratory testing (serum creatinine 2.27 mg/dL), abdominal ultrasonography (right PUJ obstruction with mild pelvicalyceal dilatation; left upper-pole cortical cyst) and dilated fundoscopy (bilateral rod–cone dystrophy). Definitive clinical diagnosis of Bardet–Biedl syndrome established using the modified Beales criteria.
During admission	Conservative management with fluid and sodium restriction, analgesia, antispasmodics, antiemetics and antihypertensive therapy; progressive resolution of pain and vomiting.
At discharge	Referral to the departments of nephrology and urology for definitive relief of the obstruction and long-term renal surveillance.

Clinical findings

On examination the patient was conscious and oriented but irritable and visibly distressed by pain. She had marked central (truncal) adiposity (Fig. 1A), with a height of 157.5 cm, a weight of 76 kg and a body mass index of 30.6 kg/m². Blood pressure was 135/90 mmHg, pulse rate 82 beats per minute and regular, and temperature 98.6°F (37.0°C). Surgical scars were present along the ulnar border of both hands (Fig. 1B, 1C), and both feet showed six fully formed, functional digits with associated brachydactyly (Fig. 1D). Intraoral examination revealed a prominent high-arched palatal vault (Fig. 2A), and mild terminal-hair hirsutism was present over the chin and jawline (Fig. 2B). Visual acuity was reduced to counting fingers at one metre in both eyes. The abdomen was soft and non-distended, with marked tenderness on deep palpation of the right lumbar region and distinct right costovertebral angle

tenderness; neither kidney was palpable and no mass or bruit was detected. Neurological examination showed no spasticity, ataxia or incoordination. The complete examination findings are set out in Table 2.

Table 2
Anthropometric, vital sign and systemic examination findings at presentation.

Parameter or system	Finding	Interpretation
General appearance	Conscious, oriented, irritable and distressed by pain	—
Height	157.5 cm	—
Weight	76 kg	—
Body mass index (BMI)	30.6 kg/m²	Obesity (WHO class I); well above the Asian-specific cut-off of ≥ 27.5 kg/m²
Fat distribution	Predominantly central / truncal	Characteristic of syndromic obesity
Blood pressure	135/90 mmHg	Elevated
Pulse	82 beats/min, regular, normal volume	Normal
Temperature	98.6°F (37.0°C)	Normal
Visual acuity	Counting fingers at 1 m, both eyes	Severe bilateral visual impairment
Craniofacial	High-arched palatal vault; mild terminal-hair hirsutism of chin and jawline	Secondary BBS feature; hirsutism
Upper limbs	Surgical scars along the ulnar border of both hands	Prior excision of postaxial supernumerary digits
Lower limbs	Six fully formed functional digits on each foot, with brachydactyly	Bilateral postaxial hexadactyly
Abdomen	Soft, non-distended; deep tenderness in the right lumbar region; right costovertebral angle tenderness; no organomegaly, mass or bruit	Consistent with right upper urinary tract obstruction
Endocrine and gynaecological	Secondary sexual characteristics appropriate for age; two-year history of oligomenorrhoea	Menstrual irregularity
Neurological	No spasticity, ataxia or incoordination	Argues against the Laurence–Moon phenotype

Diagnostic assessment

Laboratory investigation demonstrated significantly impaired renal function and a mild anaemia **(**Table 3**).** Serum creatinine was 2.27 mg/dL. Although the laboratory did not report an estimated glomerular filtration rate (eGFR), retrospective application of the 2021 CKD-EPI creatinine equation to this value gives an eGFR of approximately 30 mL/min/1.73 m², corresponding to chronic kidney disease (CKD) stage G3b. This estimate must be interpreted with caution: it derives from a single creatinine measurement obtained during an episode of acute upper tract obstruction, and eGFR equations are not validated under such conditions, so it cannot distinguish acute kidney injury superimposed on chronic disease from stable CKD.

Haemoglobin was 10.6 g/dL with a normal mean corpuscular volume (85.2 fL) but reduced mean corpuscular haemoglobin (26.2 pg) and mean corpuscular haemoglobin concentration (30.7 g/dL), indicating a mild normocytic hypochromic anaemia rather than the purely normochromic pattern typical of uncomplicated renal anaemia; coexistent iron deficiency is therefore likely, although iron studies could not be obtained. Urinalysis showed clear, straw-coloured, acidic urine with no albuminuria, glycosuria or haematuria, and only 2–3 pus cells per high-power field, a finding within normal limits and not indicative of urinary tract infection.

Table 3
Baseline laboratory investigations with laboratory reference intervals and interpretation.

Investigation	Result	Reference interval	Interpretation
Renal function			
Serum creatinine	2.27 mg/dL	0.5–1.2 (female)	Markedly elevated
eGFR (CKD-EPI 2021, calculated)	≈ 30 mL/min/1.73 m²	≥ 90	CKD stage G3b (see caveat in text)
Complete blood count			
Haemoglobin	10.6 g/dL	12.0–16.0 (female)	Low
Haematocrit	34.5%	37.0–47.0	Low
Total red cell count	4.05 × 10⁶/µL	3.5–5.5	Normal
Mean corpuscular volume (MCV)	85.2 fL	76.0–96.0	Normal (normocytic)
Mean corpuscular haemoglobin (MCH)	26.2 pg	27.0–32.0	Low (hypochromic)
Mean corpuscular Hb concentration (MCHC)	30.7 g/dL	32.0–36.0	Low (hypochromic)
Red cell distribution width (CV)	13.3%	12.8 ± 1.2	Normal
Total leucocyte count	6,770 /mm³	4,000–11,000	Normal
Neutrophils	58%	40–75	Normal
Lymphocytes	33%	20–40	Normal
Monocytes	3%	2–8	Normal
Eosinophils	6%	0–4	Mildly raised
Basophils	0%	0–1	Normal
Platelet count	275 × 10³/mm³	150–450	Normal
Urine routine and microscopic examination			
Colour / appearance	Straw / clear	Straw / clear	Normal
Reaction	Acidic	Acidic	Normal
Albumin	Nil	Nil	No proteinuria
Sugar	Nil	Nil	No glycosuria

Investigation	Result	Reference interval	Interpretation
Renal function			
Pus cells	2–3 /HPF	≤ 5 /HPF	Within normal limits
Epithelial cells	2–4 /HPF	≤ 5 /HPF	Within normal limits
Red blood cells	Not found	Not found	No haematuria
Casts and crystals	Not found	Not found	No active sediment

Blood urea, serum electrolytes, fasting plasma glucose, glycated haemoglobin, lipid profile and iron studies could not be performed because of resource constraints. The eGFR was not reported by the laboratory and has been calculated retrospectively by the authors from the measured creatinine.

Imaging and ophthalmological assessment

Abdominal ultrasonography demonstrated right-sided PUJ obstruction with a mildly dilated pelvicalyceal system, together with a solitary cortical cyst at the upper pole of the left kidney. The liver was of normal echotexture with a span of 12.4 cm, the gallbladder was normal, and the urinary bladder appeared normal on both greyscale and colour Doppler interrogation **(**Fig. 3**).** Dilated fundoscopy confirmed classical bilateral rod–cone dystrophy, with waxy optic disc pallor, marked attenuation of the retinal vessels, macular atrophy and diffuse mid-peripheral pigmentary change including bone-spicule deposits **(**Fig. 4**).** Radionuclide renography (DTPA or MAG3) and computed tomography urography could not be undertaken because of financial and infrastructural constraints. The imaging and ophthalmological findings are summarised in Table 4.

Table 4
Imaging and ophthalmological findings.

Modality / region	Finding	Clinical significance
Ultrasonography — right kidney	Pelviureteric junction obstruction with a mildly dilated pelvicalyceal system	Structural obstruction of the upper urinary tract
Ultrasonography — left kidney	Solitary cortical cyst at the upper pole	Cystic lesion consistent with a ciliopathy phenotype
Ultrasonography — liver	Normal echotexture; span 12.4 cm	No evidence of hepatic fibrosis
Ultrasonography — gallbladder	Normal wall and lumen; no calculi	Normal
Ultrasonography — urinary bladder	Normal wall and lumen on greyscale and colour Doppler imaging	No lower urinary tract abnormality
Dilated fundoscopy	Bilateral waxy optic disc pallor, marked retinal vessel attenuation, macular atrophy and diffuse mid-peripheral pigmentary change with bone-spicule deposits	Confirms rod–cone dystrophy (retinitis pigmentosa) — a primary diagnostic criterion
Visual acuity	Counting fingers at 1 m, both eyes	Severe bilateral visual impairment

DTPA, diethylenetriamine pentaacetic acid; MAG3, mercaptoacetyltriglycine. Diuretic radionuclide renography, computed tomography urography, echocardiography and audiometry were not available in this setting.

All other laboratory investigations of the patient are shown in Fig. 5.

Diagnosis

A definitive clinical diagnosis of Bardet–Biedl syndrome was established using the modified Beales criteria, which require either four primary features, or three primary features together with two secondary features [5]. As detailed in Table 5, the patient fulfilled five of the six primary features — rod–cone dystrophy, postaxial polydactyly, obesity, learning disability and renal anomaly — together with four secondary features. The threshold for a secure clinical diagnosis was therefore comfortably exceeded without recourse to molecular testing. The sixth primary feature, genital abnormality in the female, could not be formally evaluated: oligomenorrhoea was present, but pelvic imaging and a hormonal profile were not obtainable, and this feature has conservatively been recorded as not assessed rather than counted towards the diagnosis.

Table 5
Assessment of the patient against the modified Beales diagnostic criteria for Bardet–Biedl syndrome [5].

Category	Diagnostic feature	Status	Findings in this patient
Primary features (5 of 6 present)			
Primary	Rod–cone dystrophy	Present	Childhood-onset nyctalopia; classical retinitis pigmentosa on dilated fundoscopy
Primary	Polydactyly	Present	Postaxial hexadactyly of both feet; ulnar scars from childhood excision of supernumerary hand digits
Primary	Obesity	Present	Progressive truncal obesity from 4 years of age; body mass index 30.6 kg/m²
Primary	Learning disabilities	Present	Global developmental delay; persistently poor scholastic performance
Primary	Renal anomalies	Present	Right pelviureteric junction obstruction with pelvicalyceal dilatation; left upper-pole cortical cyst; serum creatinine 2.27 mg/dL
Primary	Hypogonadism (male) / genital abnormalities (female)	Not assessed	Oligomenorrhoea present, but pelvic imaging and hormonal profile unavailable; not counted
Secondary features (4 present)			
Secondary	Speech disorder or delay	Present	Phrase speech achieved only after 4 years of age
Secondary	Strabismus, cataract or astigmatism	Not documented	Not formally assessed
Secondary	Brachydactyly or syndactyly	Present	Brachydactyly of both feet
Secondary	Developmental delay	Present	Independent walking achieved only after 24 months
Secondary	Polyuria or polydipsia (nephrogenic diabetes insipidus)	Not reported	No history volunteered; urinary concentrating capacity not tested
Secondary	Ataxia, poor coordination or imbalance	Absent	Normal on neurological examination
Secondary	Mild spasticity, especially of the lower limbs	Absent	Normal tone throughout
Secondary	Diabetes mellitus	Not assessed	Fasting glucose and glycated haemoglobin unavailable

Category	Diagnostic feature	Status	Findings in this patient
Primary features (5 of 6 present)			
Secondary	Dental crowding, hypodontia, small dental roots or high-arched palate	Present	Prominent high-arched palatal vault on intraoral examination
Secondary	Left ventricular hypertrophy or congenital heart disease	Not assessed	Echocardiography unavailable
Secondary	Hepatic fibrosis	Absent	Normal hepatic echotexture; span 12.4 cm on ultrasonography

A clinical diagnosis requires four primary features, or three primary features plus two secondary features [5]. *This patient fulfilled five primary and four secondary features.*

Therapeutic intervention

The patient was admitted and managed conservatively while awaiting specialist urological assessment. Treatment comprised sodium and fluid restriction, parenteral antispasmodic and antiemetic therapy, stepwise analgesia, antihypertensive therapy, and calcium and vitamin D supplementation for chronic kidney disease–mineral and bone disorder. Non-steroidal anti-inflammatory drugs were deliberately avoided in view of the renal impairment and obstruction. The full regimen is set out in Table 6.

Table 6
Therapeutic interventions administered during the inpatient episode.

Category	Agent	Route	Indication
Dietary and fluid	Sodium restriction; controlled fluid intake	Oral	Renal impairment and elevated blood pressure
Antispasmodic	Tiemonium methylsulfate	Intravenous	Renal colic
Analgesic	Paracetamol	Oral	Baseline analgesia
Analgesic	Tramadol hydrochloride	Oral	Breakthrough pain
Gastroprotective	Pantoprazole	Intravenous	Gastric mucosal protection
Antiemetic	Ondansetron	Intravenous	Control of vomiting
Antihypertensive	Amlodipine with olmesartan	Oral	Elevated blood pressure
Antihypertensive	Bisoprolol	Oral	Elevated blood pressure
Bone and mineral	Calcium citrate with calcitriol	Oral	Chronic kidney disease–mineral and bone disorder
Anxiolytic	Alprazolam 0.5 mg	Oral	Anxiety and sleep disturbance
Neuromodulator	Duloxetine hydrochloride	Oral	Adjunctive pain control
Muscle relaxant	Tolperisone hydrochloride	Oral	Adjunctive symptom control
Laxative	Lactulose	Oral	Constipation

Non-steroidal anti-inflammatory drugs were avoided because of renal impairment and obstructive uropathy. Several agents in this regimen are renally cleared, and dose review against the estimated glomerular filtration rate, together with reassessment of renin–angiotensin system blockade in the setting of acute obstruction, is advisable in comparable patients.

Follow-up and outcomes

Pain and vomiting settled progressively with conservative therapy and the patient remained haemodynamically stable throughout. Once acute symptoms had been controlled she was formally referred to the departments of nephrology and urology for multidisciplinary assessment, definitive relief of the obstruction — anticipated to involve retrograde pyelography with double-J stent insertion or pyeloplasty — and long-term monitoring of renal function. She was counselled about the syndromic nature of her illness, the implications for her vision and kidneys, and the need for lifelong follow-up. Genetic counselling and molecular confirmation were recommended but were not accessible locally. Longer-term follow-up data are not yet available at the time of writing.

Patient perspective

The patient and her family described considerable distress arising from her long-standing and progressive loss of vision and from the sudden severity of her abdominal pain. They also expressed relief at finally receiving a single unifying explanation after years of fragmented and uncoordinated consultations, and committed to pursuing the recommended urological and nephrological follow-up.

Discussion

Pathophysiology

Bardet–Biedl syndrome is the archetypal ciliopathy, arising from biallelic variants in genes encoding proteins essential to the assembly, maintenance and function of the primary cilium and its basal body. At least 28 causative or implicated genes have now been described, and clinical genetic testing identifies a causative genotype in approximately four out of five patients [10]. Eight of the corresponding proteins assemble into an octameric complex, the BBSome, which governs trafficking of membrane proteins into and out of the cilium and thereby regulates Hedgehog, Wnt and other signalling pathways [10, 11].

The pleiotropy of the syndrome follows directly from the ubiquity of the organelle. Disruption of ciliary transport in photoreceptor connecting cilia causes progressive apoptotic degeneration of rods and then cones, producing the rod–cone dystrophy seen in this patient. Defective ciliary signalling in hypothalamic neurons drives hyperphagia and early-onset central obesity. In the kidney, impaired ciliary function in tubular epithelium underlies developmental dysplasia, cyst formation, interstitial fibrosis and a characteristic defect of urinary concentration [12].

Renal and urinary tract involvement

Renal disease is the single most important determinant of long-term prognosis in BBS [6]. In the original population survey by Beales and colleagues, a renal malformation was demonstrated in 46% of the 57 patients who underwent imaging [5], while in a French national cohort renal abnormalities — impaired function or evidence of chronic interstitial nephropathy of dysplastic type — were present in 82% of 33 patients [13]. Data from the United Kingdom national BBS clinics show that chronic kidney disease affects 31% of children and 42% of adults, with stage 4–5 disease in 6% and 8% respectively [14]. Reported frequencies are summarised in Table 7.

Table 7
Renal and urinary tract manifestations reported in Bardet–Biedl syndrome.

Manifestation	Reported frequency	Source
Structural renal malformation on imaging	46% of 57 imaged patients	Beales et al., 1999 [5]
Renal abnormality (structural and/or functional)	82% of a 33-patient national cohort	Imhoff et al., 2011 [13]
Chronic kidney disease, children	31%	Forsythe et al., 2017 [14]
Chronic kidney disease, adults	42%	Forsythe et al., 2017 [14]
Chronic kidney disease stage 4–5, children	6%	Forsythe et al., 2017 [14]
Chronic kidney disease stage 4–5, adults	8%	Forsythe et al., 2017 [14]
Calyceal clubbing and cysts, fetal lobulation, renal dysplasia, cortical cysts	Characteristic morphological pattern	Tieder et al., 1982 [15]; Harnett et al., 1988 [16]; Putoux et al., 2012 [7]
Defect of urinary concentration	Common; reflects loss of ciliary function in the collecting duct	Marion et al., 2011 [12]
Renal impairment as a major contributor to premature death	Principal cause of syndrome-related mortality	O'Dea et al., 1996 [6]
Discrete pelviureteric junction obstruction	Rarely reported; no dedicated case series identified	Present report

Frequencies are drawn from the cited cohorts and are not directly comparable, because the proportion of patients undergoing imaging and the definitions applied differ between studies.

The present case is notable for the simultaneous presence of a discrete congenital obstruction of the upper urinary tract at the pelviureteric junction and a contralateral upper-pole cortical cyst. Whereas cortical cysts, dysplasia and calyceal abnormality are firmly established components of the BBS renal phenotype [7, 15, 16], discrete PUJ obstruction is scarcely represented in the literature; a search of the indexed literature did not identify a dedicated case report or series in which PUJ obstruction was the principal renal lesion in BBS. We therefore regard this as a rare and probably under-recognised manifestation rather than a previously unreported one, and we would caution against a stronger claim in the absence of a formal systematic review.

The clinical importance of the combination lies in its arithmetic. An obstructive lesion is potentially correctable, whereas ciliopathic parenchymal disease is not; superimposing the former on the latter places functional nephron mass under compound threat, and delay in relieving the obstruction risks converting recoverable loss into permanent loss. This patient, at 22 years of age, already had an

estimated glomerular filtration rate of approximately 30 mL/min/1.73 m². The case therefore argues for renal ultrasonography in every patient presenting with postaxial polydactyly or early-onset rod–cone dystrophy, and for a low threshold for imaging whenever a patient with an established ciliopathy develops loin pain.

Differential diagnosis

Several pleiotropic syndromes share features with BBS, and the distinction rests on a small number of discriminating findings (Table 8). Alström syndrome shares obesity, retinal dystrophy and renal impairment but is characterised by sensorineural hearing loss, severely insulin-resistant diabetes and dilated cardiomyopathy, and polydactyly is absent [17]; the prominent hexadactyly in our patient excludes it. Laurence–Moon syndrome, historically grouped with BBS, is distinguished by progressive spastic paraplegia and distal weakness in the absence of polydactyly [18]; our patient had normal tone and six digits on each foot. Prader–Willi syndrome features early-onset obesity, hyperphagia, hypotonia and learning disability but lacks both retinitis pigmentosa and polydactyly [19]. McKusick–Kaufman syndrome, which is allelic with BBS6, produces postaxial polydactyly and genital anomaly but neither retinal dystrophy nor obesity [2].

Table 8
Differential diagnosis of Bardet–Biedl syndrome in a young adult with obesity, visual loss and renal disease.

Condition	Overlapping features	Discriminating features	Basis for exclusion here
Bardet–Biedl syndrome	—	Rod–cone dystrophy, postaxial polydactyly, obesity, learning disability, renal anomaly	Diagnosis established (Table 5) [5]
Alström syndrome	Obesity, retinal dystrophy, renal impairment	Sensorineural hearing loss, insulin-resistant diabetes, dilated cardiomyopathy; polydactyly absent	Bilateral postaxial hexadactyly present [17]
Laurence–Moon syndrome	Retinitis pigmentosa, obesity, learning disability, hypogonadism	Progressive spastic paraplegia and distal weakness; polydactyly absent	Polydactyly present; normal tone and no spasticity [18]
Prader–Willi syndrome	Early-onset obesity, hyperphagia, learning disability, hypogonadism	Neonatal hypotonia and feeding difficulty, short stature, characteristic facies; no retinopathy or polydactyly	Rod–cone dystrophy and polydactyly both present [19]
McKusick–Kaufman syndrome	Postaxial polydactyly, genital anomaly	Hydrometrocolpos, congenital heart disease; no retinal dystrophy or obesity	Rod–cone dystrophy and obesity both present [2]

Diagnosis and management where genetic testing is unavailable

In well-resourced settings the diagnosis is usually confirmed by targeted panel or whole exome sequencing, and a recent inter-European Reference Network consensus statement has proposed revised diagnostic criteria that incorporate molecular findings alongside clinical features [20]. Neither sequencing nor formal genetic counselling was accessible to this patient. Laboratory constraints additionally precluded measurement of blood urea, electrolytes, fasting glucose and iron indices, and nuclear medicine imaging was unavailable.

This case demonstrates that the modified Beales criteria remain a robust and entirely sufficient instrument in such circumstances. The diagnosis rested on findings obtainable at the bedside and with basic ultrasonography: careful inspection of the hands for postaxial scars, of the feet for supernumerary digits and brachydactyly, and of the palate; a developmental and ophthalmic history taken from the family; and dilated fundoscopy. Each of these is available in almost any district hospital, and it is the failure to assemble them rather than the absence of technology that most often delays diagnosis.

Recognition also carries therapeutic consequences. Setmelanotide, a melanocortin-4 receptor agonist, has been shown in a phase 3 randomised trial to reduce body weight and hunger in patients with BBS and is now licensed for this indication in several jurisdictions [21]; access in low-income settings remains limited, but a syndromic diagnosis is the prerequisite for any future consideration of such therapy. A pragmatic surveillance schedule for this patient, adapted from published consensus recommendations to what is realistically achievable locally, is proposed in Table 9.

Table 9
Proposed pragmatic multidisciplinary surveillance schedule for this patient, adapted for a resource-limited setting.

Domain	Assessment	Suggested interval	Rationale
Renal function	Serum creatinine with calculated eGFR, urinalysis, blood pressure	Every 3–6 months	Chronic kidney disease affects 42% of adults with BBS [14]
Renal imaging	Ultrasonography of both kidneys	Every 6–12 months, and promptly if loin pain recurs	Detection of progressive obstruction or cyst growth [5]
Urology	Definitive assessment and relief of the pelviureteric junction obstruction; diuretic renography where available	At diagnosis, then as clinically indicated	Preservation of functional nephron mass
Metabolic	Weight and body mass index, fasting glucose, glycated haemoglobin, lipid profile	Annually	Obesity and diabetes risk [20]
Ophthalmology	Visual acuity and fields; low-vision rehabilitation and mobility support	Annually	Progressive rod–cone dystrophy [2]
Cardiac	Echocardiography	At diagnosis, then as indicated	Left ventricular hypertrophy and congenital heart disease are recognised secondary features [5]
Reproductive and endocrine	Menstrual history, pelvic ultrasonography, hormonal profile	At diagnosis, then annually	Genital abnormality in females is a primary criterion and was not assessed [5]
Audiology	Pure tone audiometry	At diagnosis	Assists in distinguishing BBS from Alström syndrome [17]
Genetics	Targeted panel or whole exome sequencing with genetic counselling, when accessible	Once	Diagnostic confirmation and family counselling [20]
Developmental and psychosocial	Educational support, vocational planning, family counselling	Ongoing	Learning disability and progressive visual impairment

This schedule is proposed by the authors, informed by published consensus recommendations [20] *and cohort data* [14], *and adapted to locally available investigations; it does not constitute a formal guideline.*

Limitations

Several limitations should be acknowledged. First, the diagnosis is clinical: molecular confirmation was not obtainable, and although the modified Beales criteria were comfortably met, the causative genotype remains unknown. Second, the diagnosis of PUJ obstruction rests on ultrasonography and the formal radiological report alone; diuretic renography, which would have quantified the degree of obstruction and the differential function of each kidney, and computed tomography urography were unavailable. Third, static archival images of the left kidney were not retained, so the contralateral cortical cyst is documented in the radiology report but is not shown in Fig. 3. Fourth, renal function is characterised by a single creatinine measurement taken during an acute obstructive episode, so the relative contributions of acute kidney injury and pre-existing chronic disease cannot be separated, and the calculated eGFR should be regarded as indicative only. Fifth, several investigations relevant to the diagnostic criteria — echocardiography, audiometry, hormonal profiling and pelvic imaging — could not be performed, so the true phenotypic burden may be underestimated. Finally, longer-term follow-up after urological referral was not available at the time of writing, and the functional outcome of the affected kidney is therefore unknown.

Conclusions

Bardet–Biedl syndrome is a multisystem ciliopathy that requires a high index of suspicion and is readily missed when its component features are managed in isolation. This case illustrates that a young adult presenting with unexplained renal pain, a structural urological anomaly or an elevated serum creatinine should be evaluated for an underlying ciliopathy whenever postaxial polydactyly, truncal obesity or progressive visual loss coexist. It also draws attention to pelviureteric junction obstruction as a rare and probably under-recognised renal manifestation of the syndrome — one that is potentially correctable, and whose coexistence with intrinsic ciliopathic parenchymal disease places nephron mass under compound threat. Where molecular testing is unavailable, standardised clinical criteria applied through careful bedside examination and basic ultrasonography remain entirely sufficient to secure the diagnosis and to trigger timely nephroprotective, urological and multidisciplinary care.

Abbreviations

BBS
Bardet–Biedl syndrome
BMI
Body mass index
CARE
CAse REport (reporting guideline)
CKD
Chronic kidney disease
CKD-EPI
Chronic Kidney Disease Epidemiology Collaboration
CV

Coefficient of variation

DTPA

Diethylenetriamine pentaacetic acid

eGFR

Estimated glomerular filtration rate

GB

Gallbladder

Hb

Haemoglobin

HPF

High-power field

MAG3

Mercaptoacetyltriglycine

MCH

Mean corpuscular haemoglobin

MCHC

Mean corpuscular haemoglobin concentration

MCV

Mean corpuscular volume

OD

Oculus dexter (right eye)

OS

Oculus sinister (left eye)

PUJ

Pelviureteric junction

RK

Right kidney

UB

Urinary bladder

WHO

World Health Organization

Declarations

Ethics and Consent to Participate

This case report was conducted in accordance with the ethical principles outlined in the **Declaration of Helsinki (as revised in 2013)** for research involving human participants. The patient's privacy, dignity, and confidentiality were protected throughout the preparation and publication of this report. The authors confirm that the publication of this case report was performed in accordance with internationally

accepted ethical standards for medical publishing and the recommendations for publication of individual case reports.

This manuscript describes a single patient case report and does not constitute human subjects research requiring formal ethical review under the institutional policies of Manikganj Medical College and Hospital, Manikganj, Bangladesh. Accordingly, the case report was exempt from Institutional Review Board (IRB) review and formal ethics approval, as publication of an individual clinical case does not require prior IRB approval under the institution's policy. Therefore, no ethics approval number was issued.

Consent for publication

Written informed consent for publication of this case report and of all accompanying clinical information and images was obtained from the patient, and additionally from her next of kin in view of her documented learning disability. All figures have been de-identified. A copy of the signed consent form is available for review by the Editor-in-Chief of this journal on request.

CARE Guidelines Statement

This case report was prepared and reported in accordance with the CARE (CAse REport) guidelines to ensure completeness, transparency, and accuracy in the reporting of clinical information.

Availability of Data and Materials

The data that support the findings of this study are available from the corresponding author upon reasonable request. The data are not publicly available due to privacy and ethical restrictions related to patient confidentiality.

Competing Interest

The authors declare that they have no competing interests, as defined by BMC, nor any financial or non-financial interests that could be perceived as having influenced the findings, interpretation, or discussion presented in this manuscript.

Funding Statement

The authors declare that no specific funding was obtained for this work.

Author’s Contribution (CRediT Taxonomy):

Dr. Iftekhar Ahmed Sakib:

1.Conceptualization

2.Data Curation

3.Formal Analysis

4.Investigation

5.Methodology

6.Project Administration

7.Resources

8.Software

9.Supervision

10.Validation

11.Visualization

12.Writing – Review & Editing

Bandhan Chandra Mondal :

1.Conceptualization

2.Data Curation

3.Formal Analysis

4.Investigation

5.Methodology

6.Project Administration

7.Resources

8.Software

9.Supervision

10.Validation

11.Writing – Original Draft

Atika Tabassum Fariha:

1.Conceptualization

2.Data Curation

3.Formal Analysis

4.Investigation

5.Methodology

6.Project Administration

7.Resources

8.Validation

9.Visualization

10.Writing – Original Draft

Acknowledgements

The authors express their sincere gratitude to Dr. B U M Wahid Ahmed, FCPS (Medicine), Associate Professor, Department of Medicine, Manikganj Medical College, Manikganj, for his invaluable guidance, expert clinical oversight, and constant support throughout the management of this patient and the preparation of this manuscript. We also thank the clinical and nursing staff of the female medicine ward and the Department of Medicine, Manikganj Medical College. Above all, we thank the patient and her family for granting permission to share her history.

References

1. Hildebrandt F, Benzing T, Katsanis N. Ciliopathies. N Engl J Med. 2011;364(16):1533–43. doi:10.1056/NEJMra1010172.
2. Forsythe E, Beales PL. Bardet–Biedl syndrome. Eur J Hum Genet. 2013;21(1):8–13. doi:10.1038/ejhg.2012.115.
3. Farag TI, Teebi AS. High incidence of Bardet Biedl syndrome among the Bedouin. Clin Genet. 1989;36(6):463–4. doi:10.1111/j.1399-0004.1989.tb03378.x.
4. Moore SJ, Green JS, Fan Y, Bhogal AK, Dicks E, Fernandez BA, et al. Clinical and genetic epidemiology of Bardet–Biedl syndrome in Newfoundland: a 22-year prospective, population-based,

cohort study. Am J Med Genet A. 2005;132A(4):352–60. doi:10.1002/ajmg.a.30406.

5. Beales PL, Elcioglu N, Woolf AS, Parker D, Flinter FA. New criteria for improved diagnosis of Bardet–Biedl syndrome: results of a population survey. J Med Genet. 1999;36(6):437–46. doi:10.1136/jmg.36.6.437.
6. O'Dea D, Parfrey PS, Harnett JD, Hefferton D, Cramer BC, Green J. The importance of renal impairment in the natural history of Bardet–Biedl syndrome. Am J Kidney Dis. 1996;27(6):776–83. doi:10.1016/S0272-6386(96)90513-2.
7. Putoux A, Attié-Bitach T, Martinovic J, Gubler MC. Phenotypic variability of Bardet–Biedl syndrome: focusing on the kidney. Pediatr Nephrol. 2012;27(1):7–15. doi:10.1007/s00467-010-1751-3.
8. Gagnier JJ, Kienle G, Altman DG, Moher D, Sox H, Riley D; CARE Group. The CARE guidelines: consensus-based clinical case reporting guideline development. J Med Case Rep. 2013;7:223. doi:10.1186/1752-1947-7-223.
9. Riley DS, Barber MS, Kienle GS, Aronson JK, von Schoen-Angerer T, Tugwell P, et al. CARE guidelines for case reports: explanation and elaboration document. J Clin Epidemiol. 2017;89:218–35. doi:10.1016/j.jclinepi.2017.04.026.
10. Tomlinson JW. Bardet–Biedl syndrome: a focus on genetics, mechanisms and metabolic dysfunction. Diabetes Obes Metab. 2024;26(Suppl 2):13–24. doi:10.1111/dom.15480.
11. Nachury MV, Loktev AV, Zhang Q, Westlake CJ, Peränen J, Merdes A, et al. A core complex of BBS proteins cooperates with the GTPase Rab8 to promote ciliary membrane biogenesis. Cell. 2007;129(6):1201–13. doi:10.1016/j.cell.2007.03.053.
12. Marion V, Schlicht D, Mockel A, Caillard S, Imhoff O, Stoetzel C, et al. Bardet–Biedl syndrome highlights the major role of the primary cilium in efficient water reabsorption. Kidney Int. 2011;79(9):1013–25. doi:10.1038/ki.2010.538.
13. Imhoff O, Marion V, Stoetzel C, Durand M, Holder M, Sigaudy S, et al. Bardet–Biedl syndrome: a study of the renal and cardiovascular phenotypes in a French cohort. Clin J Am Soc Nephrol. 2011;6(1):22–9. doi:10.2215/CJN.03320410.
14. Forsythe E, Sparks K, Best S, Borrows S, Hoskins B, Sabir A, et al. Risk factors for severe renal disease in Bardet–Biedl syndrome. J Am Soc Nephrol. 2017;28(3):963–70. doi:10.1681/ASN.2015091029.
15. Tieder M, Levy M, Gubler MC, Gagnadoux MF, Broyer M. Renal abnormalities in the Bardet–Biedl syndrome. Int J Pediatr Nephrol. 1982;3(3):199–203.
16. Harnett JD, Green JS, Cramer BC, Johnson G, Chafe L, McManamon P, et al. The spectrum of renal disease in Laurence–Moon–Biedl syndrome. N Engl J Med. 1988;319(10):615–8. doi:10.1056/NEJM198809083191005.
17. Marshall JD, Maffei P, Collin GB, Naggert JK. Alström syndrome: genetics and clinical overview. Curr Genomics. 2011;12(3):225–35. doi:10.2174/138920211795677912.
18. Green JS, Parfrey PS, Harnett JD, Farid NR, Cramer BC, Johnson G, et al. The cardinal manifestations of Bardet–Biedl syndrome, a form of Laurence–Moon–Biedl syndrome. N Engl J Med.

1989;321(15):1002–9. doi:10.1056/NEJM198910123211503.
19. Angulo MA, Butler MG, Cataletto ME. Prader–Willi syndrome: a review of clinical, genetic, and endocrine findings. J Endocrinol Invest. 2015;38(12):1249–63. doi:10.1007/s40618-015-0312-9.
20. Dollfus H, Lilien MR, Maffei P, Verloes A, Muller J, Bacci GM, et al. Bardet–Biedl syndrome improved diagnosis criteria and management: inter European Reference Networks consensus statement and recommendations. Eur J Hum Genet. 2024;32(11):1347–60. doi:10.1038/s41431-024-01634-7.
21. Haqq AM, Chung WK, Dollfus H, Haws RM, Martos-Moreno GÁ, Poitou C, et al. Efficacy and safety of setmelanotide, a melanocortin–4 receptor agonist, in patients with Bardet–Biedl syndrome and Alström syndrome: a multicentre, randomised, double-blind, placebo-controlled, phase 3 trial with an open-label period. Lancet Diabetes Endocrinol. 2022;10(12):859–68. doi: 10.1016/S2213-8587(22)00277-7.

Figures



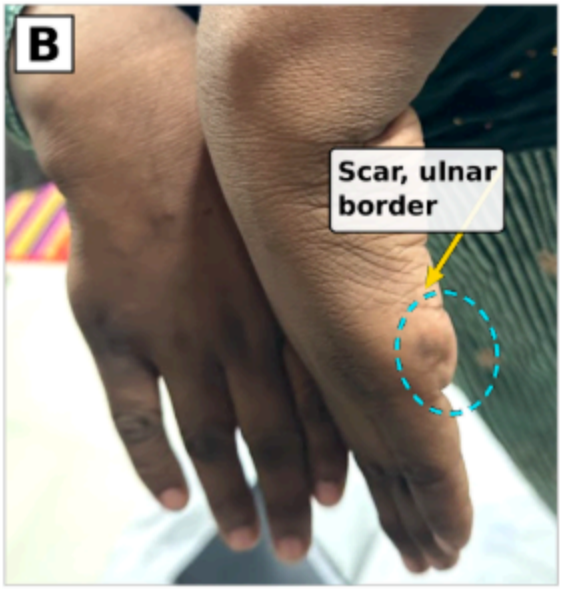

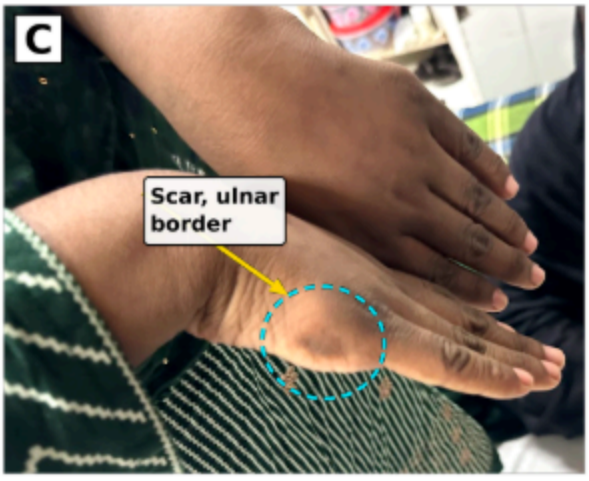



Figure 1

Somatic and musculoskeletal features of Bardet–Biedl syndrome. (A) Standing frontal photograph demonstrating marked central (truncal) adiposity (dashed outline); body mass index 30.6 kg/m². The head and background have been cropped to preserve anonymity. **(B, C)** Right and left hands, showing post-surgical scars along the ulnar (postaxial) border (dashed ellipses, arrows) following excision of supernumerary digits at 10 years of age. **(D)**Dorsal view of both feet showing six fully formed, functional digits bilaterally (arrows indicate the supernumerary postaxial digits) with associated brachydactyly (dashed box). All panels were acquired under standard ward lighting; contrast and sharpness have been adjusted uniformly, and no diagnostic content has been altered.

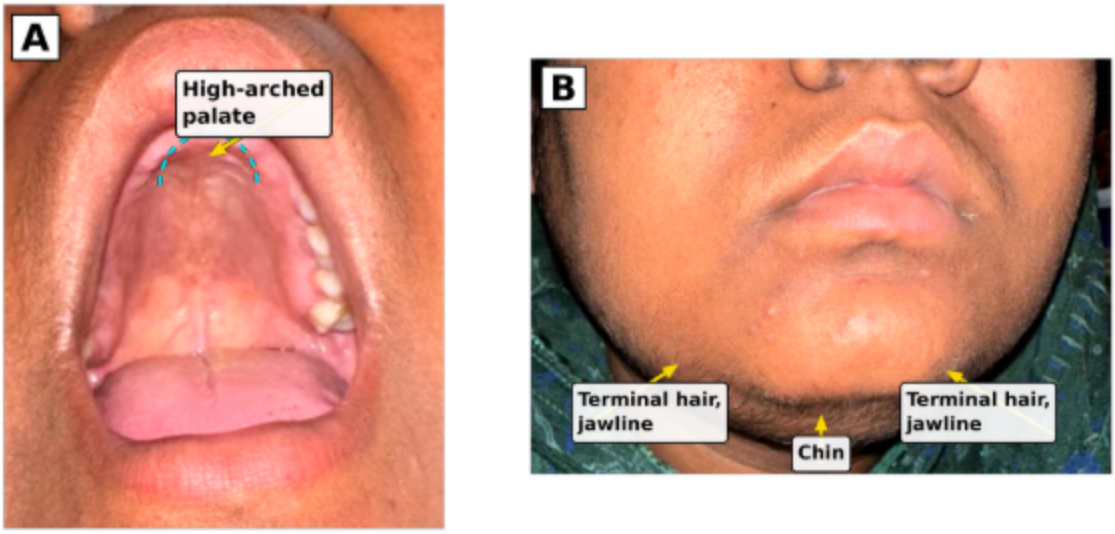

Figure 2

Craniofacial features. (A) Intraoral photograph demonstrating a prominent high-arched palatal vault (dashed arc, arrow), an established secondary diagnostic feature of Bardet–Biedl syndrome. **(B)** Close-up photograph of the lower face showing mild terminal-hair hirsutism over the chin and jawline (arrows), consistent with the reported two-year history of oligomenorrhoea. The image is cropped below the level of the eyes so that the patient is not identifiable.

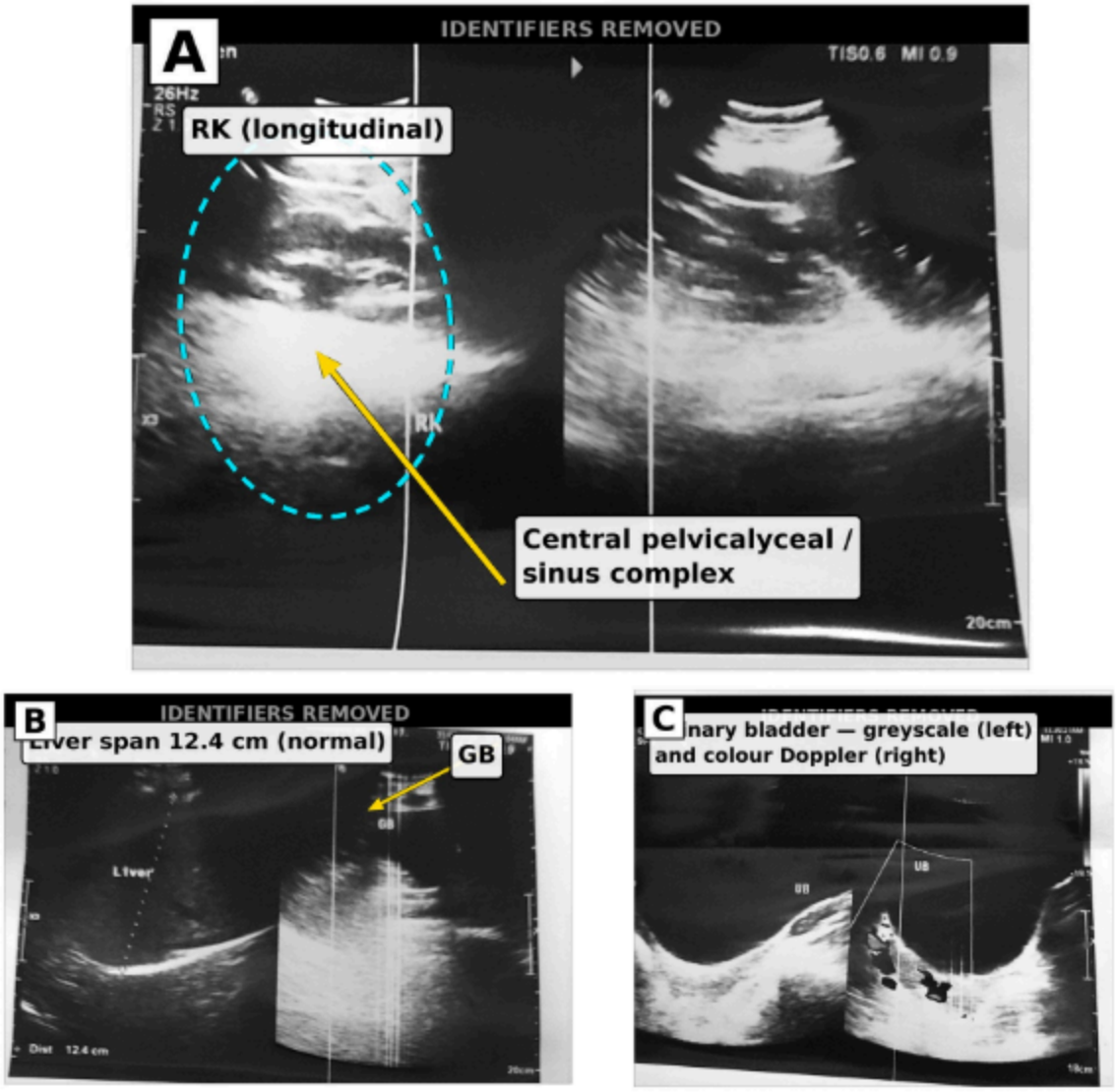

Figure 3

Abdominal and renal ultrasonography. (A) Longitudinal greyscale image of the right kidney (RK; dashed outline) with the arrow indicating the central pelvicalyceal and sinus complex, reported as mildly dilated in association with pelviureteric junction obstruction. **(B)** Transverse image of the liver, of normal echotexture with a span of 12.4 cm, and the gallbladder (GB, arrow), which is normal. **(C)** Pelvic imaging of the urinary bladder (UB) in greyscale (left) and colour Doppler (right) modes, showing a normal wall and lumen. All burned-in patient demographic overlays have been permanently masked. Images are photographs of archived thermal prints; contrast has been normalised to improve legibility.

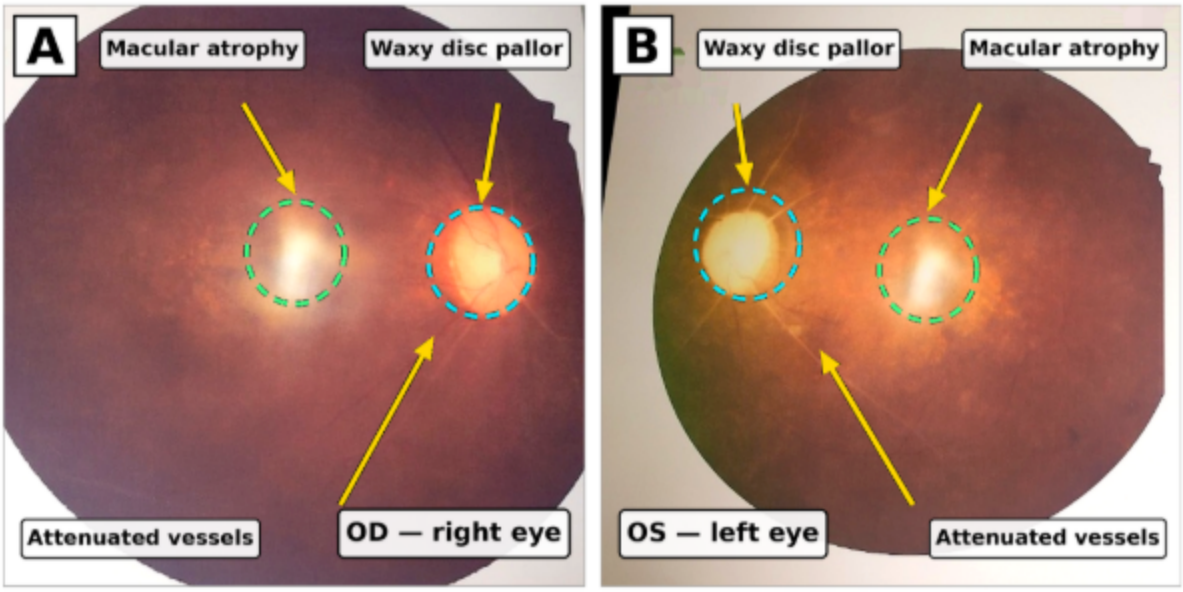

Figure 4

Colour fundus photographs demonstrating bilateral rod–cone dystrophy. (A) Right eye (OD) and **(B)** left eye (OS). Both fundi show waxy pallor of the optic disc (dashed ellipse), marked attenuation of the retinal vessels, and diffuse pigmentary retinopathy with macular atrophy and pigmentary change (arrows). The findings are those of established retinitis pigmentosa. The photographs capture the posterior pole; the classical mid-peripheral bone-spicule pigmentation described on dilated fundoscopy lies largely outside this field of view. Patient identifiers and acquisition timestamps have been removed.

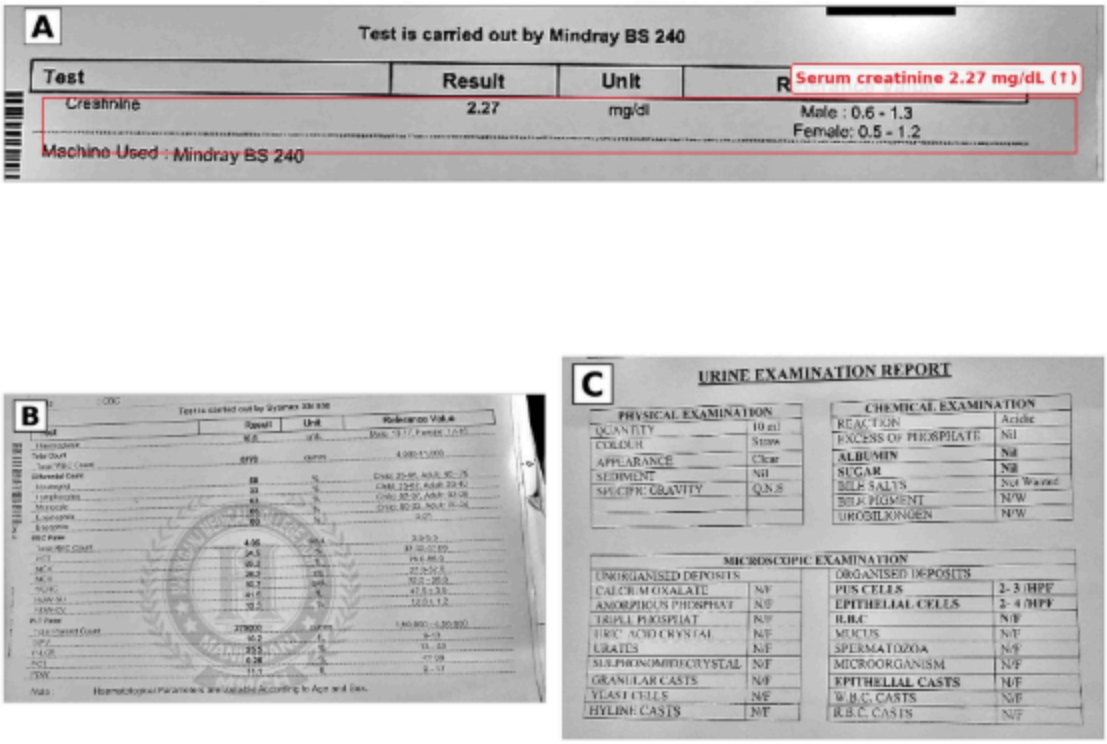

Figure 5

De-identified laboratory source documents. (A) Serum biochemistry report showing a creatinine concentration of 2.27 mg/dL against a female reference interval of 0.5–1.2 mg/dL (red box). **(B)** Complete blood count report demonstrating a haemoglobin of 10.6 g/dL with reduced mean corpuscular haemoglobin and mean corpuscular haemoglobin concentration, and normal leucocyte and platelet counts. **(C)** Urine routine and microscopic examination report showing clear, straw-coloured, acidic urine without albuminuria, glycosuria or haematuria. All panels have been cropped and masked to remove the patient's name, hospital and laboratory identification numbers, dates and the names of reporting staff. The corresponding numerical values are tabulated in **Table 3**.

Supplementary Files

This is a list of supplementary files associated with this preprint. Click to download.

- SupplementaryMaterials.docx