Research Square

Preprints are preliminary reports that have not undergone peer review.
They should not be considered conclusive, used to inform clinical practice,
or referenced by the media as validated information.

First clinico-pathological investigation of nasal adenocarcinoma in sheep of semi-arid Rajasthan

Ganesh Gangaram Sonawane
Central Sheep and Wool Research Institute
Jegaveera Pandian Sankariah
Central Sheep and Wool Research Institute
Sita Ram Sharma
Central Sheep and Wool Research Institute
Dushyant Kumar Sharma
dr.dushsharma@gmail.com
Central Sheep and Wool Research Institute
Jyoti Kumar
Central Sheep and Wool Research Institute
Chander Prakash Swarnkar
Central Sheep and Wool Research Institute

Research Article

Keywords: Nasal adenocarcinoma, Clinico-pathological, Sheep, Rajasthan

Posted Date: August 19th, 2026

DOI: https://doi.org/10.21203/rs.3.rs-10498547/v1

License: This work is licensed under a Creative Commons Attribution 4.0 International License.
Read Full License

Additional Declarations: No competing interests reported.

Abstract

Respiratory tumours are rarely reported in small ruminants, among these, the retroviral tumours such as ovine pulmonary adenocarcinoma (OPA) and enzootic nasal adenocarcinoma (ENA) have been documented in most of the sheep and goat-rearing countries. This study presents the epidemiological, clinical and pathological observations of natural outbreaks of nasal carcinoma, resembling enzootic nasal adenocarcinoma (ENA) in sheep flocks of semi-arid Rajasthan. The Nasal fluid smears were air-dried, stained using a modified May–Grünwald–Giemsa staining for presence of tumour cells. Haematology was done clinically affected sheep. Gross and histopathology of various organs was done from the dead animals affected with nasal tumours. Diagnosis of nasal carcinoma was achieved through modified May-Grunwald Giemsa staining of nasal discharge and fluids. The occurrence of disease was reported since 2019 in affected sheep flocks in the region with the morbidity and mortality ranging from 15–16% and 9–15% respectively. Clinical examinations revealed unilateral and/or bilateral protrusion of the eyeball, extensive loss of reflexes, and vision impairment due to corneal damage. Affected sheep exhibited respiratory distress, abdominal breathing, anorexia, and progressive emaciation. Cytological examination of nasal samples confirmed nasal carcinoma with acute rhinitis. Haematological evaluations indicated anaemia and eosinophilia in clinically affected sheep. Necropsy findings included the presence of a white to grey, soft, friable and irregular tumour mass in the caudal part of the nasal cavity, with discrete areas of necrosis. In one sheep affected lungs showed consolidated lobes with tumour mass. Microscopically, nasal tumour sections revealed histological alterations indicative of a slowly proliferating adenocarcinoma associated with chronic inflammatory changes. Lung tumour sections showed characteristic proliferative changes of adenocarcinoma within the alveoli with papillomatous formations displaying distinct connective tissue cores. This study reported for the first time a rare outbreak of nasal adenocarcinoma in sheep with significant mortality and morbidity, leading to substantial losses for sheep stakeholders.

1 Introduction

Respiratory tumours are uncommon in small ruminants and the neoplasms such as ovine pulmonary adenocarcinoma (Sonawane et al. 2016) and nasal adenocarcinoma(Rajan 1987) have been rarely reported India. Enzootic nasal adenocarcinoma (ENA) has been reported worldwide in sheep and goat-rearing countries except in Australia, New Zealand and Great Britain (Svara et al. 2006). The surprising fact that in China, ENA has been reported in goats of many provinces, however, there is no single report of ENA in sheep. The disease is caused by the enzootic nasal tumour virus (ENTV), a retrovirus responsible for tumour development in small ruminants (Leroux and Mornex 2008). ENTV is genetically related to Jaagsiekte sheep retrovirus (JSRV), the etiological agent of ovine pulmonary adenocarcinoma (OPA) and causes disease in both sheep and goats. ENTV-1 induces nasal neoplasms in sheep, whereas ENTV-2 affects goats (Ortín et al. 2003). The disease is chronic, afebrile and characterized initially by profuse seromucous nasal discharge, which later becomes purulent. These signs are often accompanied by progressive respiratory distress. Tumours are generally unilateral and arise within one nasal cavity. Following cranially or laterally expansion of tumour, the exerted pressure on adjacent anatomical

structures often resulting in exophthalmos due to compression of the retro-orbital tissues (De las Heras et al. 2026). In some cases, the tumours may be bilateral, leading to more severe clinical manifestations. Following the onset of clinical signs, death may occur within a period ranging from 3 weeks to 9 months, primarily due to septicaemic or toxaemic complications (De las Heras et al. 2003). Although natural ENTV infection in sheep presents with a characteristic clinical pattern, it can be confused with other conditions, including chronic proliferative rhinitis caused by *Salmonella enterica* subsp. *diarizonae*, *Oestrus ovis* infestation, and other bacterial or fungal infections (Rubira et al. 2019).

In India, nasal tumours were first reported in cattle in Kerala during the 1960's by Rajan et al., (1972). Since then, Kerala has been recognized as an endemic region for this condition, often referred - as enzootic or endemic ethmoidal tumours. Initially, these tumours were believed to arise due to hereditary factors, viral involvement, or exposure to carcinogenic mycotoxins such as aflatoxin, based on their epidemiological characteristics (Rajan 1987). Subsequently, the condition has been reported in several species, including cross bred cow (Preena et al. 2020), buffaloes (Balasubramaniam et al. 2015), pigs (Pramod et al. 2014) and other domestic animals, including sheep and goats (Rajan 1987). In the present communication, we for the first time describe the epidemiological, clinical, and pathological findings associated with a natural outbreak of a nasal tumour resembling like enzootic nasal adenocarcinoma in sheep flocks from semi-arid Rajasthan.

2 Materials and Methods

2.1 Study animals and history of flocks

The study was conducted in sheep flocks (n= 3) located in villages of the Tonk (n= 1) and Jaipur (n=2) districts of Rajasthan (India). The area lies in a semi-arid region at a latitude of 26°17' N and longitude of 75°28' E. The maximum temperature during summer (April–July) ranges from 38 °C to 45 °C, while the minimum temperature during winter (November–February) ranges from 2 °C to 10 °C. The average annual rainfall is approximately 400 mm, occurring mainly during July and August.

The predominant native breed of sheep reared in this region is Malpura. Some farmers also maintain other breeds such as Patanwadi and Kheri. All animals were reared under an extensive management system with 8–10 hours of daily grazing on natural pastures consisting of a mixture of weeds and palatable grass species on community grazing land and forest. During the night, animals were housed in partially covered corrals. Usually, no supplementary feeding was practiced; however, animals had *ad libitum* access to drinking water. Deworming was performed regularly, whereas vaccination history was inadequate and often inconsistent. The practice of exchanging breeding males among different flocks was commonly reported.

The disease was first recorded during the post-monsoon months (September–October) of 2019 in three sheep flocks comprising more than 400 animals in one village of the Tonk district. Another incidence was reported during the same season in 2020 in two sheep flocks (100 animals per flock) of two located

in the Jaipur district adjacent to the affected villages of Tonk. Detailed information regarding morbidity and mortality, onset of clinical signs, previous treatments and vaccination history were collected. Animals exhibiting prominent clinical signs were examined thoroughly. Additionally, apparently healthy animals were screened for nasal discharge, snoring, and other respiratory signs.

2.2 Necropsy, sample collection, haematological and histopathological investigation

The necropsy examination of two dead animals available during the outbreak were subjected to detailed post-mortem examination with special emphasis on the head and nasal cavity. The side of exophthalmos and associated ocular lesions were recorded. Gross lesions in the visceral organs were examined and documented. Nasal discharge or fluid samples were collected from seven clinically affected sheep and directly smeared onto clean glass slides. The smears were air-dried, stained using a modified May–Grünwald–Giemsa staining method (Piaton et al. 2016) and examined under an optical microscope at 40x and 100x magnification for the presence of tumour cells. Blood samples were collected from the same seven clinically affected sheep for haematological analysis. Haemoglobin (g %) was estimated in the whole blood by cyanmethemoglobin method (Haldane 1901). Packed cell volume (PCV %) was determined in whole blood by capillary microhaematocrit method (Coles EH 1980). Total erythrocyte count (TLC), Total leucocyte count (TLC) was done manually by Haemocytometer (Neubaur's counting chamber) in whole EDTA blood. Differential leucocyte count was estimated in blood smear stained with Giemsa stain by routine method. Simultaneously, blood samples from six sheep belonging to an unaffected flock located approximately 50 km away from the outbreak area were collected and used as controls for haematological parameters. For histopathological examination, tissue samples from the nasal tumour, tumour-affected lungs and other visceral organs, including lymph nodes, liver, heart, kidneys, spleen, and brain were collected in 10% neutral buffered formalin. After fixation, tissues were trimmed, embedded in paraffin, sectioned at 5 µm thickness and stained with haematoxylin and eosin (H&E) for microscopic examination(Culling 1974).

2.3 Statistical analysis:

The haematological data were analysed by one way ANOVA using SPSS software (version 22.0).

3 Results

3.1 Clinical Signs

In village of the Tonk district, flock history indicated that 55-60 in the flocks of around 400 sheep had been affected by the same disease and the illness had adversely impacted flock performance for the preceding three months. However, young lambs, did not exhibit any clinical illness during the outbreak.

Among the total 400 sheep, 60 adult sheep (15%) were found to be clinically affected and exhibited moderate to severe clinical signs. Mortality records revealed that out of 400 sheep, 40 animals (10%) had died during the preceding two months. A similar disease occurrence was observed in 2020 in two sheep flocks from the Jaipur district, each comprising 100 animals, where 32 animals (16%) showed clinical signs and 18 sheep (9%) died due to the disease.

The clinical examination of affected sheep revealed unilateral exophthalmos, while bilateral protrusion of the eyeballs was observed in some cases. In severely affected animals, extensive ocular lesions were noted, including loss of corneal integrity, absence of natural reflexes, and complete loss of vision (Figure 1). Other prominent clinical signs included coarse respiratory noise (stertor), peripheral bilateral blindness, dilated pupils, flaring of nostrils, mouth breathing, frothy salivation, circling behaviour, and rapid muscle wasting. Despite the severity of clinical signs, affected animals maintained a relatively low but consistent level of feed intake. Examination of the nasal cavity did not reveal any visible polypoid mass; however, blood-tinged nasal discharge accompanied by inspiratory dyspnoea was evident. The menace reflex was absent, while the pupillary light reflex remained intact. Some animals showed only moderate weight loss with mild protrusion of the eyeball. Blood-mixed nasal discharge was observed in approximately 80% of affected animals. A few sheep exhibited stertorous breathing accompanied by coughing, and tracheal palpation elicited a cough reflex. Unilateral or bilateral exophthalmos was attributed to compression of the orbit by the expanding intranasal tumour mass. Nasal cytological examination of seven sheep revealed a high cellular turnover of round to polygonal epithelial cells arranged in clusters with evident cell-to-cell adhesion (Figure 2). These cells exhibited bluish cytoplasm with minimal anisocytosis and anisokaryosis, round nuclei with ropey chromatin, and small multiple nucleoli. Scattered neutrophils and plasma cells were also observed in some areas of the smears. Based on cytological findings, the condition was tentatively diagnosed as nasal carcinoma with concurrent acute rhinitis.

3.2 Clinical Haematology

Haematological examination of clinically affected sheep revealed significant ($P< 0.01$) decrease in the packed cell volume, total erythrocyte count, and haemoglobin concentration compared with those of the healthy control group. Differential leukocyte counts showed an increase in the eosinophil counts in affected sheep as compared to control (Table 1).

Table 1: Mean (±S.E.) **haematological parameters in sheep affected with enzootic nasal adenocarcinoma.**

Parameter	Normal (healthy control) (N=6)	Affected (N=7)
Hemoglobin (g %) **	12.37±0.13	8.86±0.40
Packed cell volume (%) **	30.00±0.73	25.14±0.74
Total erythrocyte count (x10^6/ dl) **	4.91±0.12	4.20±0.26
Total leukocyte count (x10^3/ dl)	8.23±0.35	8.56±0.86
Lymphocytes (%)	57.17±0.65	49.29±3.38
Neutrophils (%)	29.67±0.42	33.00±3.12
Monocytes (%)	6.00±0.45	7.57±0.78
Eosinophils (%) **	6.67±0.21	9.43±0.72
Basophils %	0.50±0.22	0.71±0.18

** - Significant between groups (P < 0.01)

3.3 Gross Lesions

On necropsy, the carcasses were found to be in poor body condition, emaciated, with pale musculature and scant adipose tissue. Longitudinal sectioning of the head along the midline revealed a white to grey, soft, friable, irregular tumour mass with discrete areas of necrosis located in the caudal portion of the nasal cavity. The tumour mass was attached to the mucosa of the ethmoid turbinate bones and extended into the frontal and maxillary sinuses but did not involve the brain (Figure 3).

The lungs revealed tumour masses predominantly in the left cranial lobes and less frequently, in other lobes. Tumour-affected lobes were enlarged, heavier, greyish to reddish in color, severely consolidated and firm in consistency. The cut surface of affected lung lobes showed a solid, granular appearance with elevated, round, greyish tumour nodules. In some areas, tumour-associated cavities filled with necrotic debris and purulent material were observed (Figure 4).

3.4 Histopathology

Histopathological examination of the nasal tumour sections revealed a proliferation of epithelial cells predominantly arranged in glandular and semi-papillary architectural patterns (Figure 5). These neoplastic epithelial structures were supported by a moderate fibrovascular stroma composed of fibrous connective tissue. The tumour stroma showed marked infiltration of inflammatory cells, mainly macrophages, along with plasma cells and lymphocytes, indicating a chronic inflammatory response

(Figure 6). The neoplastic cells were relatively uniform, exhibiting mild cellular pleomorphism, indistinct cell borders, moderate eosinophilic cytoplasm, and round to oval nuclei with finely dispersed chromatin. Mitotic figures were infrequent, suggesting a low mitotic index. Additionally, the tumour sections contained discrete foci of necrosis characterized by eosinophilic cellular debris and karyorrhectic nuclear fragments. Overall, these histomorphological features were indicative of a slowly proliferating adenocarcinoma associated with chronic inflammatory changes.

Histological examination of lung tumour sections revealed characteristic proliferative changes within the alveoli, consisting of papillomatous growth forming well-defined papillae with distinct connective tissue cores, imparting an adenomatous appearance. These papillary ingrowths partially or completely obstructed the alveolar lumina, projecting into the alveolar spaces (Figure 7). The bronchial and bronchiolar epithelium also showed hyperplastic changes, occasionally forming papillary projections that partially or completely occluded the bronchiolar lumen. Numerous macrophages were observed within the alveolar lumina and in the vicinity of proliferating alveoli. In certain areas, the interstitial spaces of the alveoli were thickened due to infiltration of lymphocytes and plasma cells (Figure 8). Similar mononuclear cell infiltration was evident in peribronchial, peribronchiolar, and perivascular regions. Additionally, neutrophilic aggregates were observed within the lumina of several alveoli. Histological examination of the lymph nodes, liver, heart, kidneys, spleen, and brain did not reveal any evidence of metastatic lesions and these organs appeared histologically normal.

4 Discussion

A tumour or neoplasm is defined as a newly formed mass of tissue resulting from excessive and uncontrolled cellular proliferation. In small ruminants, respiratory tumours are relatively rare; the most commonly described neoplasms include pulmonary adenomatosis and ethmoid bone–associated nasal tumours, particularly enzootic nasal adenocarcinoma (ENA). ENA is caused by infection with the enzootic nasal tumour virus (ENTV) a retrovirus responsible for contagious neoplastic diseases in small ruminants. This disease has been reported in several countries worldwide (Kane et al. 2005; Ajayi et al. 2013).

In India, reports of ENA-like tumours are extremely rare and have largely been confined to the southern regions of the country, including early descriptions in small ruminants from Kerala (Rajan 1987) and more recently in Madras Red sheep (Venkataramanan et al. 2021). In the present study, an outbreak of ENA-like neoplasms was recorded for the first time in adult sheep from Rajasthan with exhibition of typical ocular lesions and respiratory distress due to intranasal tumour growth. The observed morbidity and mortality rates in affected flocks ranged from 15–16% and 9–15%, respectively found to be higher in the present study than the previously reported epidemiological data on ENA ranging from 0.1% to 15% (De las Heras et al. 1998). Consistent with earlier reports, no apparent genetic, sex, or breed predisposition was observed in the affected sheep flocks.

The most prominent clinical signs in the present outbreak included unilateral or bilateral exophthalmos with severe ocular damage, respiratory distress accompanied by blood-tinged nasal discharge, and progressive emaciation. These distinctive clinical features facilitated the differentiation of ENA-affected sheep from other nasal conditions such as oestrosis, nasal polyps, or bacterial infections. Similar clinical manifestations have been described previously in sheep and goats affected with ENA (De las Heras et al. 2003; Walsh et al. 2013). Progressive emaciation observed in affected sheep was likely due to chronic disease and impaired respiration. The clinically affected sheep with nasal tumours appeared to be anaemic, as the mean values of packed cell volume, total erythrocyte count, and haemoglobin concentration were significantly decreased. The anaemia in these sheep might be attributed to prolonged illness, respiratory distress, anorexia, and emaciation caused by ENA. A significant increase in eosinophil count was observed; however, the differential leukocyte counts of the other white blood cells remained within normal ranges compared to those of the control sheep. Anemia, monocytosis, and eosinophilia in most affected animals, could be attributed to secondary bacterial complications associated with nasal and pulmonary tumours. Death in such cases has been reported to occur due to pneumonia or septicaemia (De las Heras et al. 2003).

Cytological examination of nasal smears from clinically affected sheep consistently revealed features suggestive of nasal carcinoma with concurrent acute rhinitis, highlighting the diagnostic value of this technique. Nasal cytology is a valuable, minimally invasive screening tool for the preliminary diagnosis of nasal tumours and can assist clinicians in deciding subsequent confirmatory diagnostic approaches and management strategies. Similar cytological techniques have been successfully employed in the diagnosis of ENA in sheep (Jahns and Cousens 2020) and goats (Ajayi et al. 2013), as well as in nasal tumours of other domestic animals (Caniatti et al. 2012).

In the present study, a soft, friable, white-to-grey tumour mass with necrotic areas was found to be located in the caudal nasal cavity, attached to the ethmoid turbinates and extending into the frontal or maxillary sinuses without involvement of the brain. Histologically, the nasal tumours exhibited glandular to papillary epithelial proliferation supported by fibrous stroma, mild inflammatory infiltration, low mitotic activity, and focal necrosis, consistent with previously reported gross and microscopic ENA lesions (Perl et al. 1987; De las Heras et al. 2003; Walsh et al. 2013; Jahns and Cousens 2020). ENA in sheep and goats is generally characterized by locally invasive growth within the nasal passages, leading to severe respiratory compromise and is typically considered non-metastatic (Svara et al. 2006). However, in the present study, metastatic grey-to-red consolidated tumour masses were detected in the lungs, a finding that is rarely reported in sheep. The lung lesions closely resembled the nasal tumours, displaying adenocarcinomatous features with papillomatous alveolar proliferation accompanied by infiltration of macrophages, lymphocytes, plasma cells, and neutrophils, along with interstitial thickening suggestive of Ovine pulmonary adenomatosis.

5 Conclusions

The present report appears to be the first report of an important ailment, enzootic nasal adenocarcinoma in sheep from the semi-arid region Rajasthan. However, molecular confirmation of the etiological agent involved is highly warranted. Emergence of ENA is sheep of Rajasthan reflects gaps in animal health surveillance, biosecurity and disease awareness within extensive grazing systems. Management practices such as communal grazing and exchange of breeding males likely facilitate virus transmission, emphasizing the need for integrated disease control strategies. The absence of effective vaccines, therapeutic options and early diagnostic tools prone to cull the breeding sheep, severely limits disease management and hinders accurate estimation of its prevalence. Given the economic importance of small ruminants to rural livelihoods, particularly in arid and semi-arid regions of India, the findings underscore the urgency for improved surveillance, farmer education and research focused on diagnostic and preventive measures.

Declarations

Data Availability statement

The raw data (images and haematology sheet) are not publicly disclosed due to confidential concern. The raw data is available as supplementary material and available with corresponding author.

Author Contributions

Conceptualization and outbreak investigation was done by GGS, JPS, JK. Necropsy and Sample collection- GGS, JPS, JK, DKS, SRS, Haematology and nasal cytological analysis by DKS and GGS, Histopathology and sample processing by GGS and DKS, Data Analysis and manuscript formulation by GGS, CPS, JPS, DKS. All authors have read and agreed to the published version of the manuscript.

Funding

This study did not receive any specific external funding, as it was conducted as part of the diagnostic investigation of emerging diseases in farmers' flocks. However, the laboratory investigations associated with this research were supported by the Indian Council of Agricultural Research (ICAR), New Delhi, India.

Generative AI statement

The authors acknowledge the use of the generative AI tool ChatGPT, which was employed solely for rephrasing and language editing of selected sentences in the manuscript. The content edited using the Generative AI has been checked for factual accuracy and plagiarism, the use of Generative AI has been included in the acknowledgements section of the manuscript. All intellectual content, including research design, data generation, and analysis, was entirely conceived and executed by the authors, who take full responsibility for the published work. Mendeley Reference Manager was used to manage citations and generate the bibliography for this manuscript.

References

1. Ajayi, O. L., Oyewusi, I. K., Olaniyi, M. O., Oyekunle, M. A., Jagun, A. T., Omotainse, S. O., & Biobaku, K. (2013). Enzootic nasal adenocarcinoma: Cytological and clinicopathological observations in a West African Dwarf goat. *Bulletin of Animal Health and Production in Africa*, *61*, 331–336.
2. Balasubramaniam, G. A., Balachandran, P., Arulmozhi, A., Madheswaran, R., Sivaseelan, S., & Srinivasan, P. (2015). Ethmoidal adenocarcinoma with pulmonary metastasis in a buffalo – a case report. *Indian Journal of Veterinary Pathology*, *39*(2), 164–165. https://doi.org/10.5958/0973-970X.2015.00036.X
3. Caniatti, M., Cunha, N. P. da, Avallone, G., Romussi, S., Mortellaro, C. M., Tranquillo, V., & Ghisleni, G. (2012). Diagnostic accuracy of brush cytology in canine chronic intranasal disease. *Veterinary Clinical Pathology*, *41*(1), 133–140. https://doi.org/10.1111/j.1939-165X.2011.00388.x
4. Coles EH. (1980). *Veterinary clinical pathology* (3rd ed.). Philadelphia (& London): W. B. Saunders.
5. Culling, C. F. A. (1974). *Handbook of Histopathological and Histochemical Techniques*. Elsevier. https://doi.org/10.1016/C2013-0-04011-X
6. De las Heras, M., Minguijón, E., Ferrer, L. M., Ortín, A., Dewar, P., Cebrián, L. M., Pascual, Z., García, L., García de Jalón, J. A., & Sharp, J. M. (1998). Naturally occurring enzootic nasal tumor of sheep in Spain: pathology and associated retrovirus. *European Journal of Veterinary Pathology*, *4*, 11–15.
7. De las Heras, M., Ortín, A., Cousens, C., Minguijón, E., & Sharp, J. M. (2003). *Enzootic Nasal Adenocarcinoma of Sheep and Goats* (pp. 201–223). https://doi.org/10.1007/978-3-642-55638-8_8
8. De las Heras, M., Ortín, A., & Sharp, J. M. (2026). Enzootic Nasal Adenocarcinoma in Sheep and Goats. In *Encyclopedia of Livestock Medicine for Large Animal and Poultry Production* (pp. 419–422). Springer Nature Switzerland. https://doi.org/10.1007/978-3-031-61549-8_207
9. Haldane, J. (1901). The colorimetric determination of hæmoglobin. *The Journal of Physiology*, *26*(6), 497–504. https://doi.org/10.1113/jphysiol.1901.sp000848
10. Jahns, H., & Cousens, C. (2020). Nasal adenocarcinoma associated with jaagsiekte sheep retrovirus infection in a sheep. *Journal of Veterinary Diagnostic Investigation*, *32*(1), 152–155. https://doi.org/10.1177/1040638719897032
11. Kane, Y., Rosati, S., Diop, O. M., Profiti, M., Niang, I., Kadja, M., Kaboret, Y. Y., Alogninouwa, T., & Lena, P. (2005). Tissue targets and phylogenetic characteristic of the enzootic nasal tumour virus (ENTV) infecting sahelian sheep. *Revue de Medecine Veterinaire*, *156*, 29–36.
12. Leroux, C., & Mornex, J. F. (2008). Retroviral infections in sheep and the associated diseases. *Small Ruminant Research*, *76*(1–2), 68–76. https://doi.org/10.1016/j.smallrumres.2007.12.010
13. Ortín, A., Cousens, C., Minguijón, E., Pascual, Z., Villarreal, M. P. de, Sharp, J. M., & Heras, M. D. las. (2003). Characterization of enzootic nasal tumour virus of goats: complete sequence and tissue distribution. *Journal of General Virology*, *84*(8), 2245–2252. https://doi.org/10.1099/vir.0.19125-0
14. Perl, S., Yakobson, B., Orgad-Klopfer, U., Abramson, M., & Nobel, T. (1987). Enzootic Nasal Tumour of sheep. *Veterinary Quarterly*, *9*(2), 118–122. https://doi.org/10.1080/01652176.1987.9694088

15. Piaton, E., Fabre, M., Goubin-Versini, I., Bretz-Grenier, M., Courtade-Saïdi, M., Vincent, S., Belleannée, G., Thivolet, F., Boutonnat, J., Debaque, H., Fleury-Feith, J., Vielh, P., Egelé, C., Bellocq, J., Michiels, J., & Cochand-Priollet, B. (2016). Guidelines for May-Grünwald–Giemsa staining in haematology and non-gynaecological cytopathology: recommendations of the French Society of Clinical Cytology (<scp>SFCC</scp>) and of the French Association for Quality Assurance in Anatomic and Cytologic Pathology (<scp>AFAQAP</scp>). *Cytopathology*, *27*(5), 359–368. https://doi.org/10.1111/cyt.12323
16. Pramod, S., Vijayan, N., Nair, N. D., Usha, A. P., Gopalakrishna, R., Tirupathi, V., & Lalithakunjamma, C. R. (2014). Gross and immunohistochemical studies on undifferentiated ethmoid carcinoma in an indigenous pig. *Veterinarski Arhiv*, *84*, 97–102.
17. Preena, P., Sahoo, D., John, C., Joseph, B., Renjith, R., Boby, N., & Palekkodan, H. (2020). Cytological diagnosis of ethmoid carcinoma in a cross bred cow with concurrent theileriosis. *Haryana Veterinarian*, *59*, 267–269.
18. Rajan, A. (1987). Carcinoma of the mucosa of the ethmoid in domestic animals. *Annales de Recherches Veterinaires. Annals of Veterinary Research*, *18*(1), 13–17.
19. Rajan, A., Sivadas, C. G., Nair, M. K., & Maryamma, K. I. (1972). Incidence and pathology of tumours of the paranasal sinuses in domestic animals. *The Kerala Journal of Veterinary Science*, *3*, 89–101.
20. Rubira, I., Figueras, L., De las Heras, M., Bueso, J. P., Castells, E., Climent, M., & Lacasta, D. (2019). Chronic proliferative rhinitis in sheep: An update. *Small Ruminant Research*, *179*, 21–25. https://doi.org/10.1016/j.smallrumres.2019.09.001
21. Sonawane, G. G., Tripathi, B. N., Kumar, R., & Kumar, J. (2016). Diagnosis and prevalence of ovine pulmonary adenocarcinoma in lung tissues of naturally infected farm sheep. *Veterinary World*, *9*(4), 365–370. https://doi.org/10.14202/vetworld.2016.365-370
22. Svara, T., Gombac, M., Vrecl, M., Juntes, P., Kostanjsek, R., Pogacnik, A., & Pogacnik, M. (2006). Enzootic Nasal Adenocarcinoma of Sheep in Slovenia. *Journal of Veterinary Medicine Series A*, *53*(1), 26–29. https://doi.org/10.1111/j.1439-0442.2006.00784.x
23. Venkataramanan, R., Hemalatha, S., Sreekumar, C., & Manonnmani, D. (2021). Clinicopathological findings in ethmoidal nasal tumour in Madras Red sheep. *Indian Journal of Small Ruminants*, *27*, 301–304.
24. Walsh, S. R., Linnerth-Petrik, N. M., Yu, D. L., Foster, R. A., Menzies, P. I., Diaz-Méndez, A., Chalmers, H. J., & Wootton, S. K. (2013). Experimental transmission of enzootic nasal adenocarcinoma in sheep. *Veterinary Research*, *44*(1), 66. https://doi.org/10.1186/1297-9716-44-66

Figures



Figure 1

A. Unilateral and **B.**bilateral exophthalmos in sheep affected with ENA, **C.** Extensive ocular lesions including loss of corneal integrity, absence of natural reflexes, and complete loss of vision in severely affected sheep.

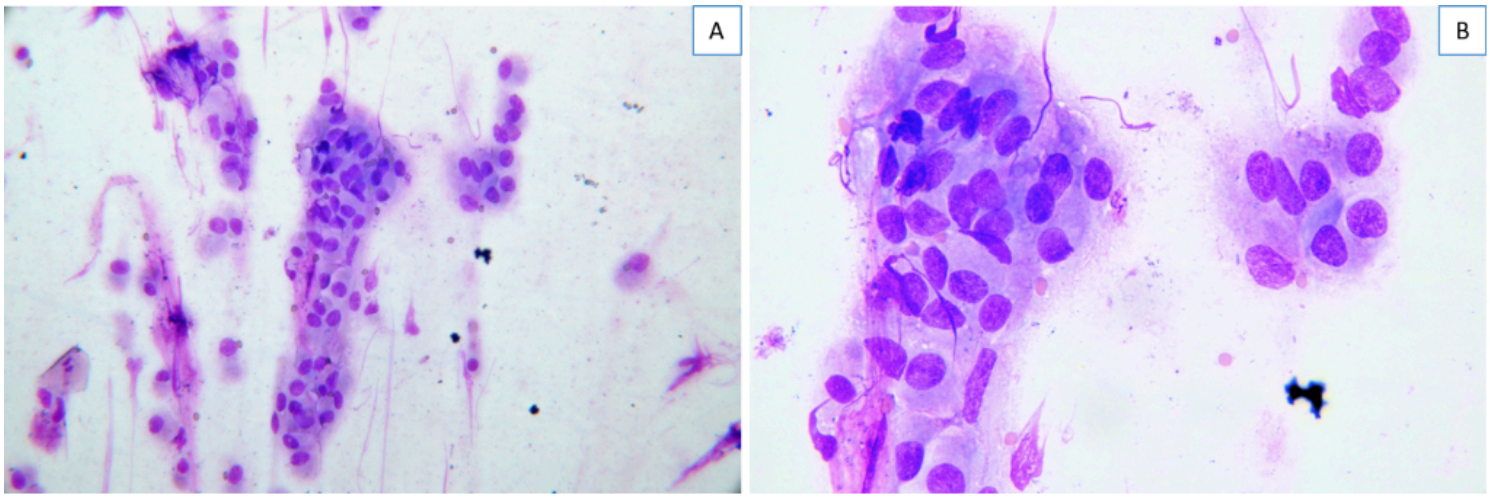

Figure 2

Nasal smear (A) Cluster of neoplastic cells with basophilic cytoplasm, anisocytosis and anisokaryosis, round nuclei containing ropey chromatin and small multiple small nucleoli (Modified May–Grünwald Giemsa stain, x40), (B) Cytomorphological features of the neoplastic cells (Modified May–Grünwald Giemsa stain, x100).

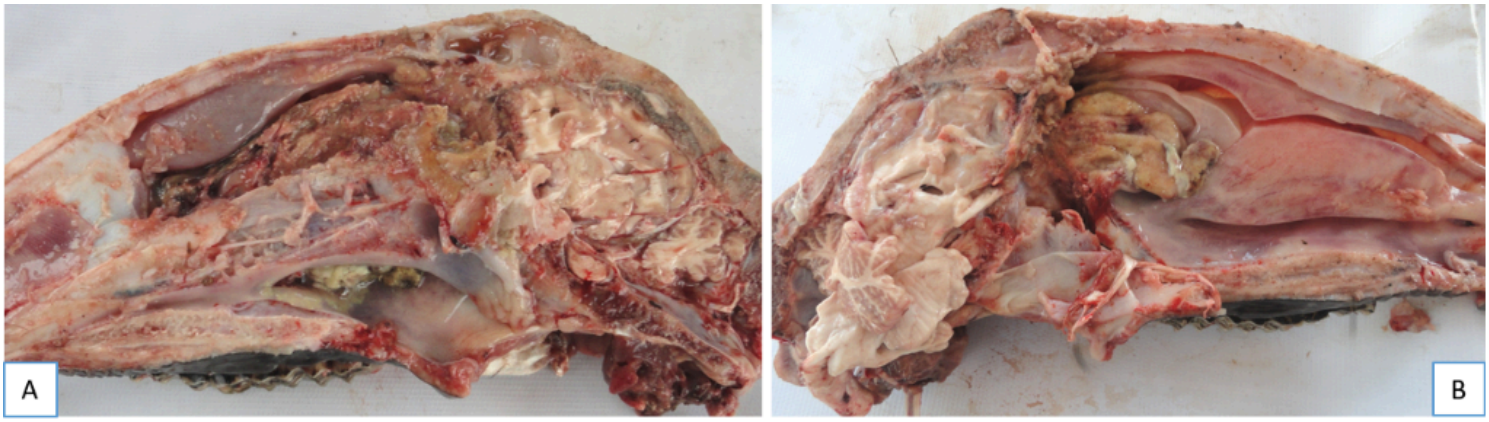

Figure 3

Longitudinal section of the head along the midline (A) Right side showing a white to grey, soft, friable, irregular tumour mass with multifocal areas of necrosis attached to the mucosa of the ethmoid turbinates and extending into the frontal and maxillary sinuses, (B) Left side showing no evidence of tumour involvement.



Figure 4

A. Left cranial lobe of the lungs showing tumour masses with severe consolidation and firm consistency**.** **B.** Cut surface of affected lung lobes showing a solid, granular appearance with elevated, round, greyish tumour nodules and cavities filled with necrotic debris and purulent material

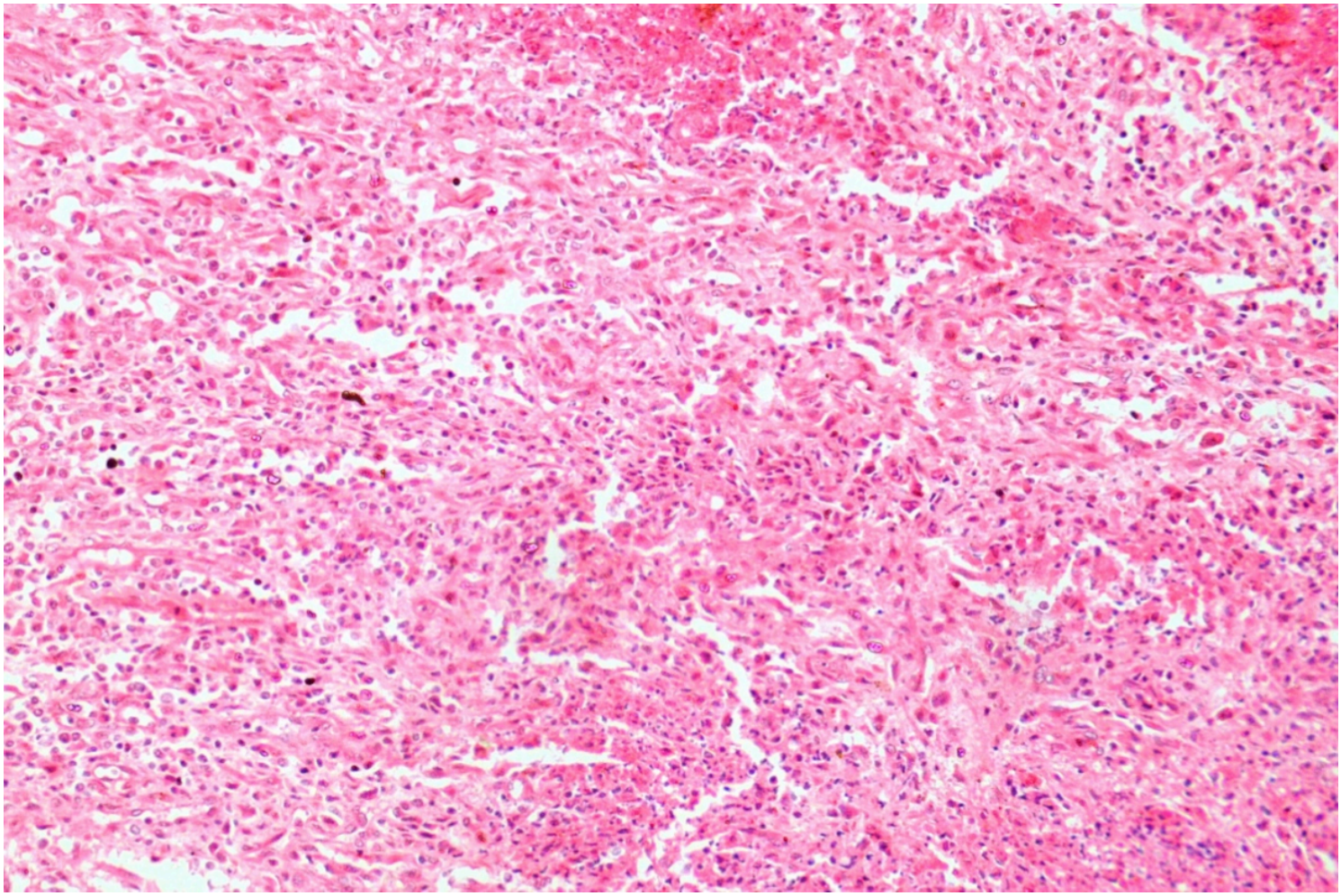

Figure 5

Nasal tumour section showing proliferation of epithelial cells arranged in glandular and semi-papillary architectural patterns (H&E, x20)

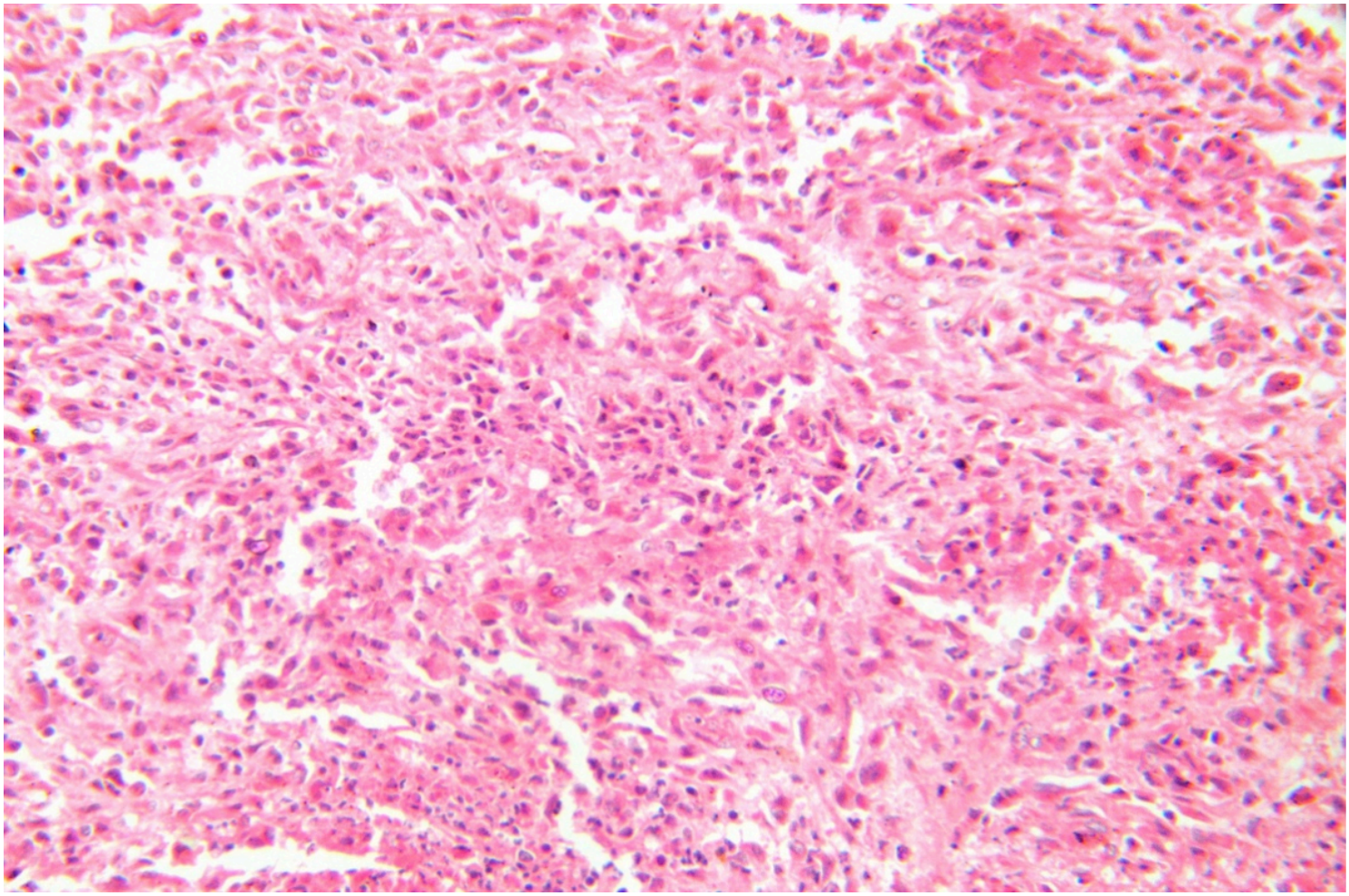

Figure 6

Neoplastic epithelial structures supported by a fibrous connective tissue along with infiltration of inflammatory cells (H&E, x40)

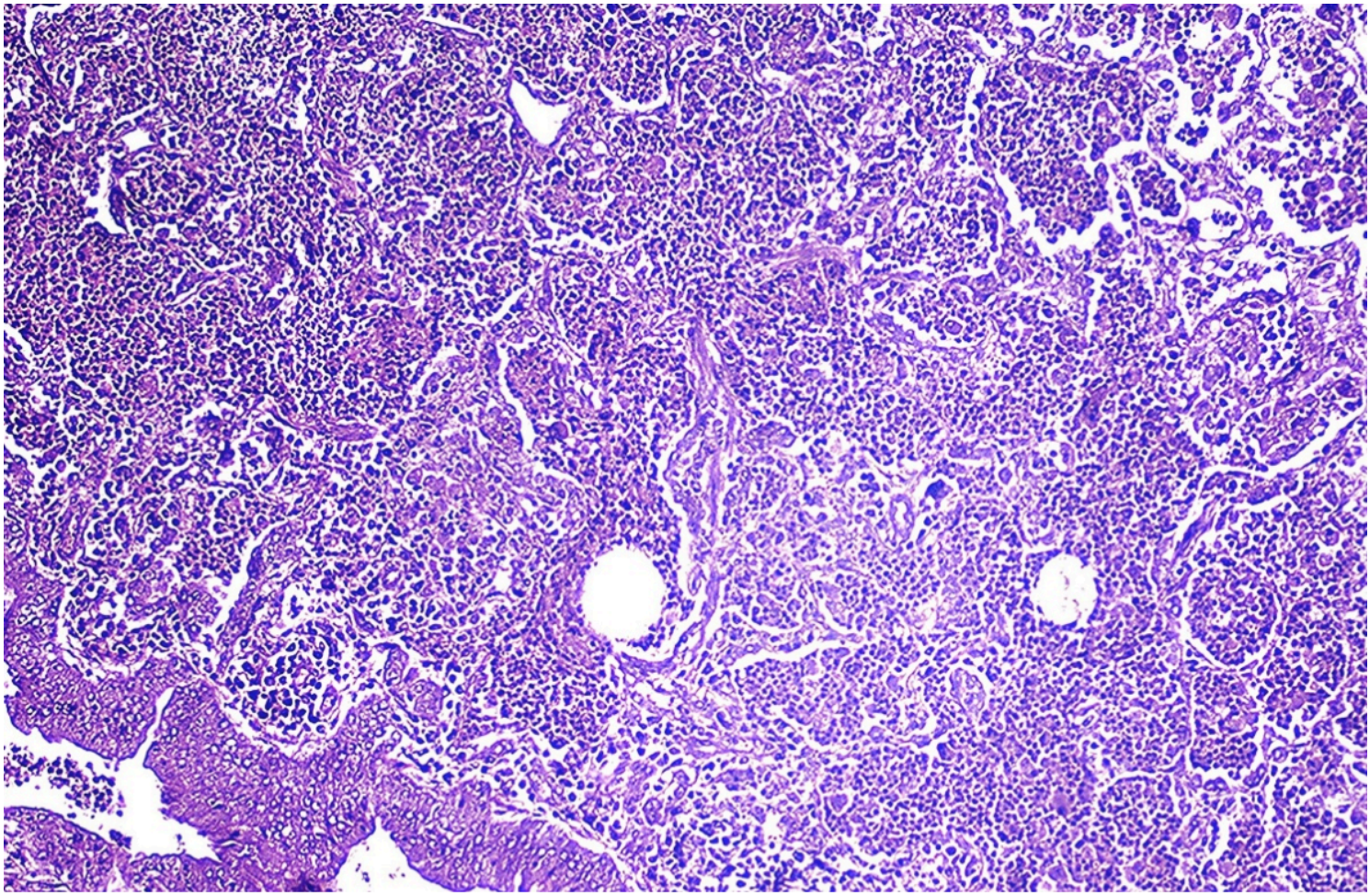

Figure 7

Lung tumour section showing characteristic proliferative changes within the alveoli imparting an adenomatous appearance (H&E, x10)

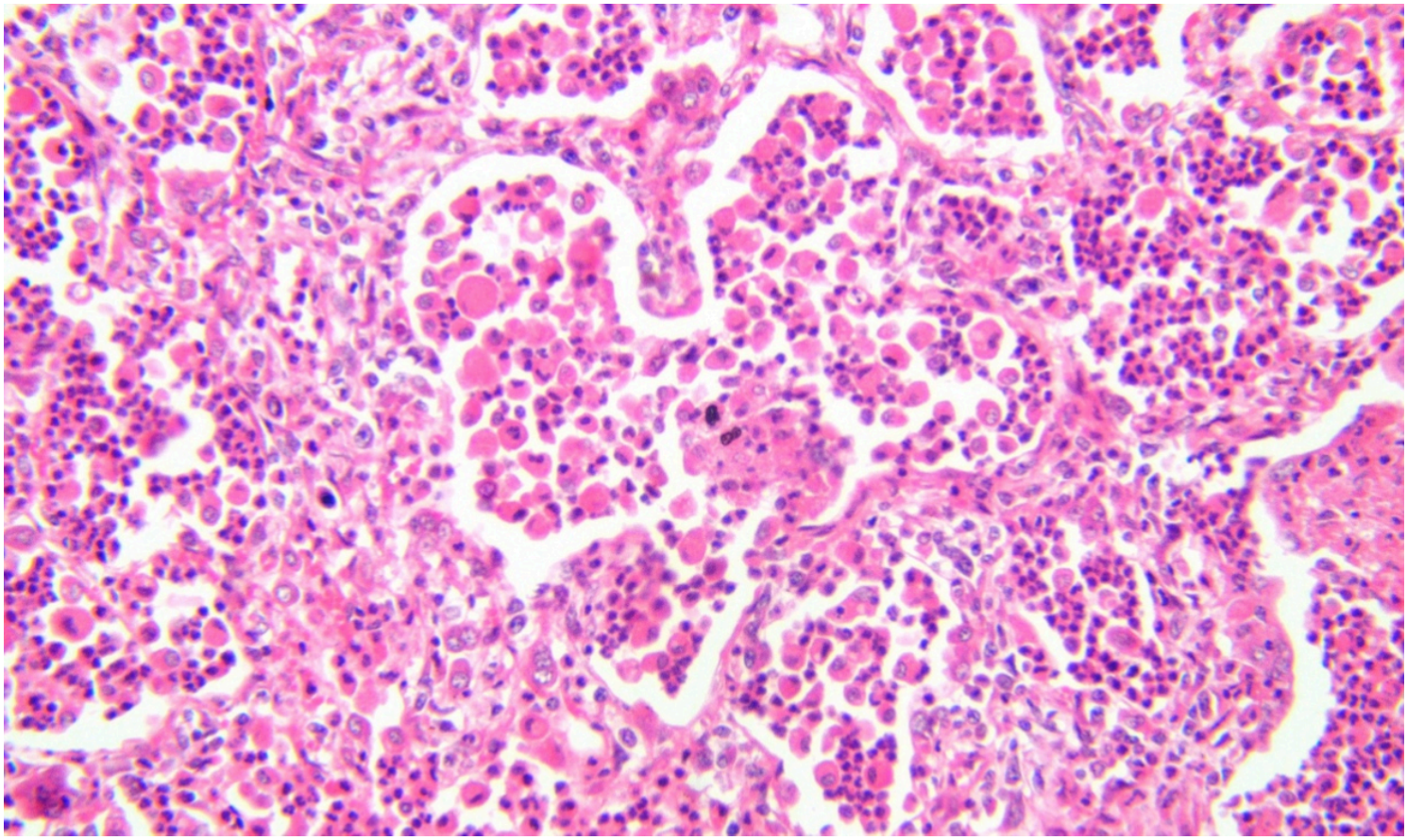

Figure 8

Numerous inflammatory cells within the alveolar lumina and in the vicinity of proliferating alveoli, thickened interstitial spaces of the alveoli due to infiltration of lymphocytes and plasma cells (H&E, x40)