Research Square

Preprints are preliminary reports that have not undergone peer review.
They should not be considered conclusive, used to inform clinical practice,
or referenced by the media as validated information.

Rare combination of knee injuries in an eight-year-old boy with spina bifida: A Case Report

Ralf Kraus
Universitätsklinikum Gießen und Marburg
Jonas Pawelke
Jonas.Pawelke@gmx.de
Universitätsklinikum Gießen und Marburg
Tim Ludwig Tuengler
Universitätsklinikum Gießen und Marburg
Gero Knapp
Universitätsklinikum Gießen und Marburg

Case Report

Keywords: Spina bifida, Patella sleeve fracture, Bucket-handle tear meniscus, Children, Case Report

Posted Date: November 23rd, 2026

DOI: https://doi.org/10.21203/rs.3.rs-10361363/v1

License: This work is licensed under a Creative Commons Attribution 4.0 International License.
Read Full License

Additional Declarations: No competing interests reported.

Rare combination of knee injuries in an eight-year-old boy with spina bifida: A Case Report

Authors: Ralf Kraus[1], Jonas Pawelke*[1] (Jonas.Pawelke@uk-gm.de), Tim Ludwig Tuengler[1] (Tim.Tuengler@uk-gm.de), Gero Knapp[1] (Gero.Knapp@chiru.med.uni-giessen.de)

[1] Department for Trauma, Hand and Reconstructive Surgery, University Hospital of Giessen, Rudolf-Buchheim-Straße 7, 35385 Gießen, Germany

*Corresponding author: Jonas.Pawelke@gmx.de

Abstract

Background: Patellar sleeve fractures and bucket-handle meniscal tears are both extremely rare injuries in children under ten years. Their sequential occurrence in a patient with pre-existing neuropediatric conditions has not been previously described.

Case presentation: We report the case of an eight-year-old boy with spina bifida and corresponding hypoplastic lower extremities. He subsequently suffered a sleeve fracture of the superior pole of the right patella and a bucket-handle tear of the lateral meniscus within a few months. The patellar fracture was treated with open reduction and tension band osteosynthesis, while the subsequent meniscal tear required an arthroscopic all-inside refixation.

Conclusions: The connection between these rare consecutive injuries and constitutionally determined knee instability is plausible. Both injuries require timely and appropriate surgical treatment to preserve the knee joint's range of motion and load-bearing capacity.

Keywords

Spina bifida – Patella sleeve fracture – Bucket-handle tear meniscus – Children – Case Report

Introduction

A typical, yet rare, knee injury in childhood and adolescence is the avulsion fracture of the superior or inferior pole of the patella, also known as a sleeve fracture. It occurs at the earliest when the ossification center of the patella becomes radiographically visible, i.e., around the age of 6 [1]. Most cases in the literature involve adolescents [2,3]. However, cases in healthy adults have also been described [4]. The inferior pole of the patella appears to be affected more frequently [5].

The morphological correlate of a patella sleeve fracture is the avulsion of the quadriceps or patellar tendon along with the remaining cartilaginous portion of the patella and a portion of the posterior patellar cartilage, which together are pulled away from the ossification center of the patella like a sleeve. The cause is considered to be maximal exertion of the extensor mechanism.

Clinical and imaging diagnostics can be problematic. The patient history is rather nonspecific and does not differentiate it from other knee injuries. Clinical examination reveals knee effusion with a floating patella and either superior or inferior patellar displacement. Active raising of the extended leg may be impossible.

Radiographically, the vertical displacement of the patella can be observed. Bony pole fragments are usually absent. The cartilaginous pole fragment can be visualized sonographically, as well as with magnetic resonance imaging [6].

This injury is extremely rare. Patellar fractures in children and adolescents account for a maximum of 1% of all fractures in this age group. Reports for fractures in incompletely ossified patellae range from 1% [1] to 57% [2].

Bucket-handle tears of the menisci in children under 10 years of age are also extremely rare injuries. Canton et al. A literature search in 2021 found only 21 cases [7]. Kramer et al. reported that children under 10 years of age in a cohort of 280

patients up to 19 years of age were only 5% [8]. Of eight cases published as case reports, only one involved the lateral meniscus [9].

In this case report, we present the case of an eight-year-old child with a serious pre-existing condition who consecutively suffered these two extremely rare injuries, describe our therapeutic approach, and discuss the possible causes.

Case Report

We report on an eight-year-old boy with a complex combination of injuries to the right knee joint and its successful treatment. A spina bifida aperta at L4/L5 was diagnosed and surgically closed in utero. Internal hydrocephalus developed, which is being treated with a Rickham reservoir. He also has bilateral clubfeet, which were treated with Ponsetti casts and bilateral Achilles tenotomy.

The young patient receives regular neuropediatric care. A Galileo device is used twice daily. His lower extremities are hypoplastic. He wears carbon-spring orthoses with polypropylene liners. With these, he is able to walk freely, albeit with a wide gait. He exhibits a Trendelenburg gait and pronounced lumbar lordosis, indicative of muscular insufficiency. Both knee joints are valgus, and the ligaments are lax. He still participates in physical education classes at his school and plays goalkeeper in soccer.

Four months after his last neuropediatric evaluation, he complains of pain in his right knee after a soccer game at school, and the knee swells considerably in the following days. Initial X-rays are unremarkable (Fig. 1).



Fig. 1: Initial X-rays oft he right knee showing no fracture but excessive swelling of the soft tissues.

An MRI scan reveals a sleeve fracture of the superior pole of the patella with a displacement of 2.5 cm (Fig. 2).



Fig. 2: MRI with sleeve fracture oft he proximal patellar pole.

Ten days after the injury, open reduction and tension band osteosynthesis are performed using two Kirschner wires and Suture-Tape® (Arthrex) (Fig. 3).



Fig. 3: intraoperative X-rays after tension banding oft he patella using 1.6 mm K-wires and a Suture-Tape®.

The knee is immobilized in a brace for four weeks with permitted weight-bearing. After six weeks, the osteosynthesis material is removed once bony consolidation has occurred.

Approximately eight weeks after hardware removal, the young patient resumed his athletic activities to the extent and within his usual limits. Two weeks later, pain recurred in his right knee. He experienced a 10-degree limitation in knee extension, although extension function remained intact, and effusion developed. X-rays showed the patella to be intact, and superior or inferior displacement could be ruled out. Magnetic resonance imaging (MRI) revealed an extensive, displaced bucket-handle tear of the lateral meniscus (Fig. 5) in the context of a healed patellar injury (Fig. 4). A discoid meniscus, a predisposing factor, was not present.



Fig. 4: MRI 8 weeks after metal removal showing completely healed patella.

Fig. 5: Same MRI with severely displaced bucket-handle tear oft he lateral meniscus.

Arthroscopic evaluation, unfortunately only performed three months later, revealed a stable cartilage covering on the posterior surface of the patella with a slight step-off at the junction of the proximal and middle thirds, a remnant of the completely healed sleeve fracture (Fig. 6).

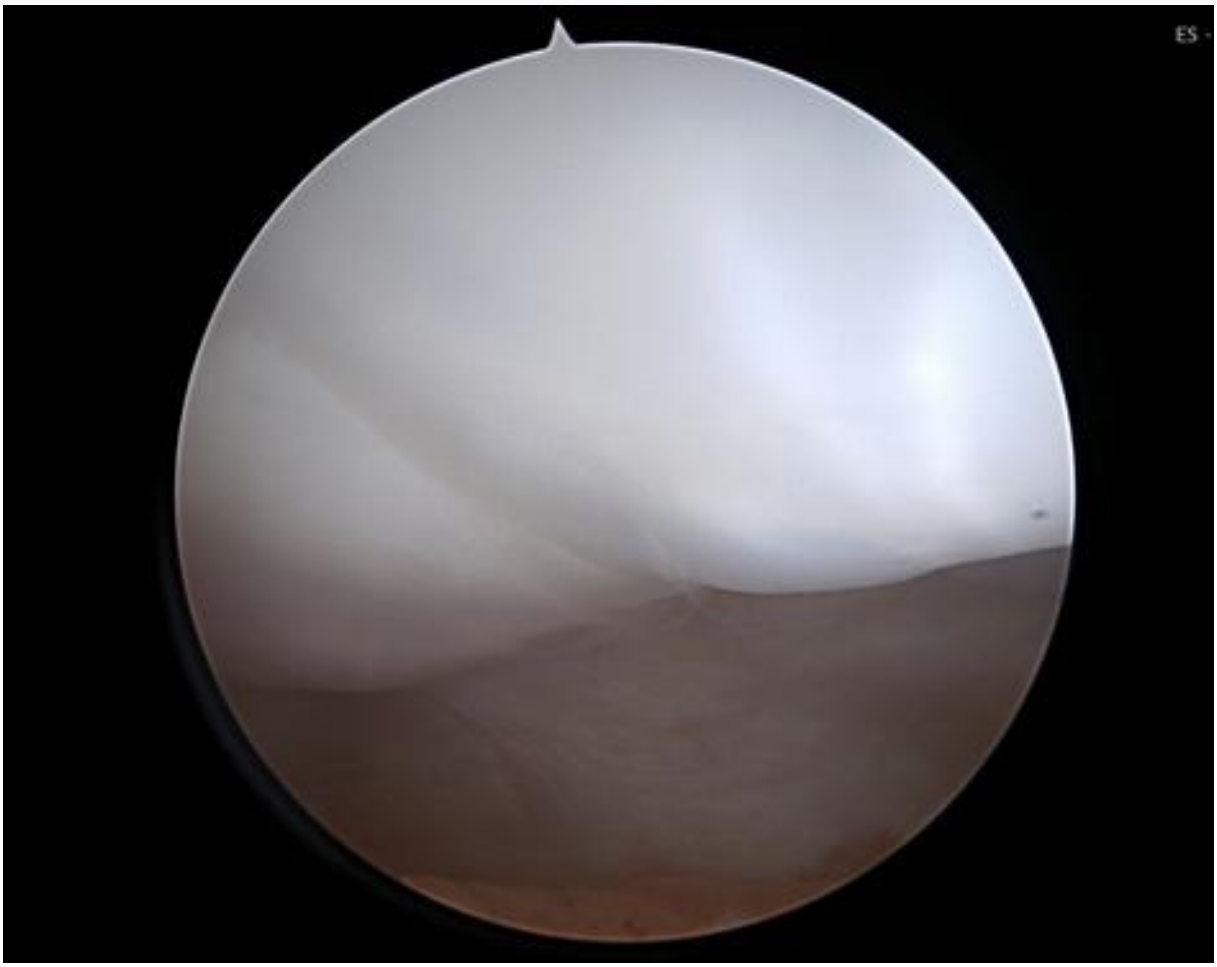

Fig. 6: Arthroscopic view on the retropatellar cartilage.

The patella was stable in the patellofemoral groove during flexion. The medial compartment (Fig. 7) and the cruciate ligament complex appear unremarkable.

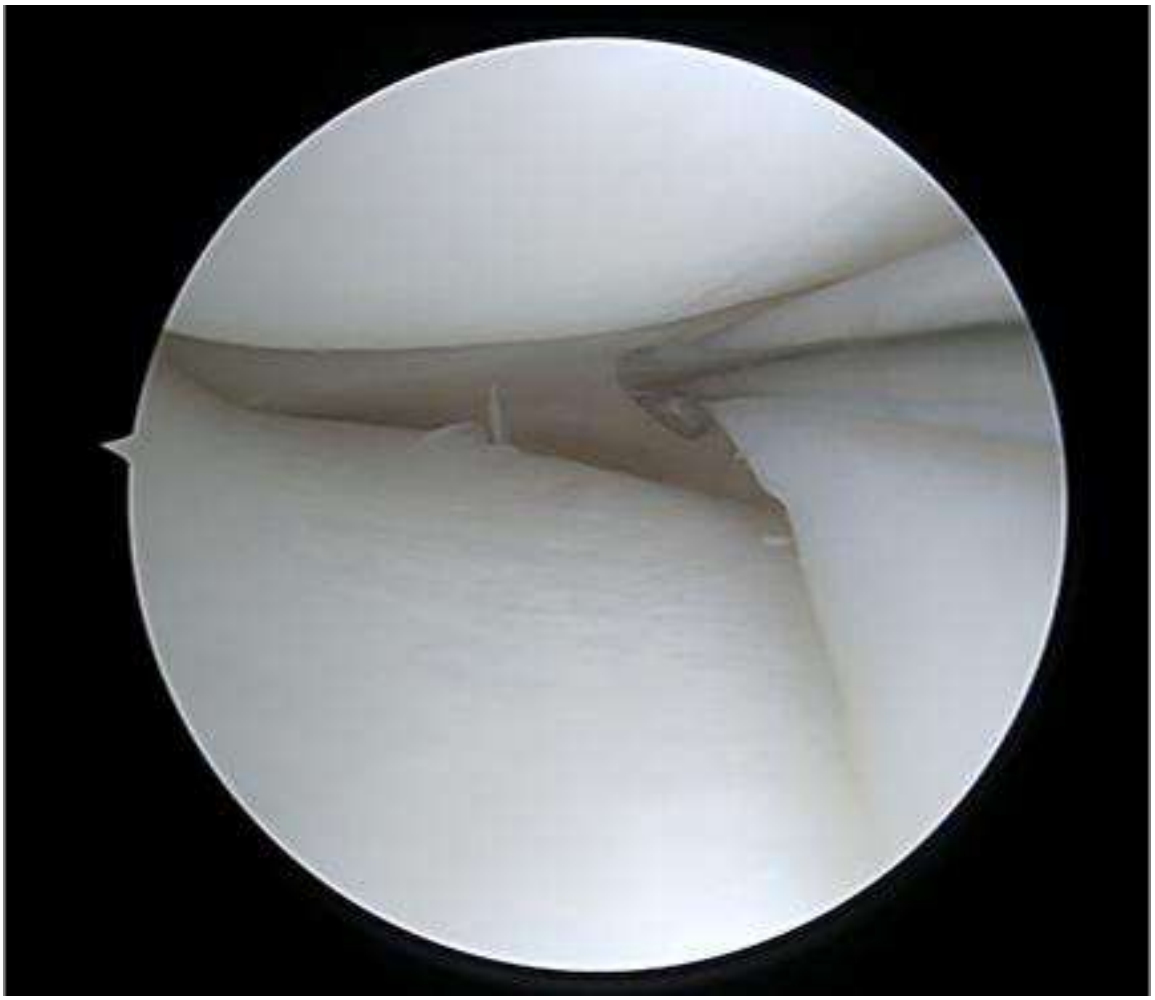

Fig. 7: Healthy medial meniscus.

In the lateral compartment, a bucket-handle tear of the lateral meniscus, dislocated anteriorly, is evident (Fig. 8).



Fig. 8: Displaced bucket-handle tear oft he lateral meniscus.

The tissue is swollen, making reduction correspondingly difficult. Refixation is performed with three all-inside sutures (Arthrex FiberStitch®) (Fig. 9).



Fig. 9: Lateral meniscus reduced and fixed with three all-inside FiberStitch® sutures.

Patient perspective

The patient and his parents were relieved that, despite the complex pre-existing conditions and the frustrating setback of a second severe knee injury within a few months, joint stability and function could be successfully restored. The parents noted after completing his recovery, the son was able to return to school physical education and his position as a soccer goalkeeper without major limitations.

Discussion

Both sleeve fractures of the patella and bucket-handle tears of the lateral meniscus are extremely rare injuries in children under 10 years of age. The occurrence of both injuries in such close succession in our eight-year-old patient must therefore be

considered a particular rarity. We are convinced that the pre-existing condition, with its consequences of knee malalignment and instability, played an important role in their development. Malalignment of the knee joint is cited as a predilection factor for meniscal tears even in otherwise healthy children and adolescents [9]. However, the extent to which this also applies to patellar pole avulsions is not addressed in the literature.

While the treatment of sleeve fractures is described more or less uniformly in the few published case reports, there is no consistent recommendation regarding the management of lateral meniscal lesions.

Osteosynthesis of the patella is recommended using classic tension band wiring or suture-anchor systems [5, 10-12]. The latter have the advantage that metal removal is not necessary. We opted for a tension band fixation to provide optimal stability to the patella in a patient with a constitutionally unstable knee. Suture Tape® as a cerclage was chosen for patients with very thin soft tissues to avoid a potentially bulky wire closure. The outcomes after these injuries are generally good, provided they are treated early. Delayed surgical treatment is considerably more complex [14,15].

The literature on meniscal tears in childhood is considerably more extensive. Approximately half of all meniscal tears occur during sports activities. Several authors have investigated the relationship between a lateral discoid meniscus and a bucket-handle tear of the lateral meniscus [10,16]. The proportion of discoid menisci among bucket-handle tears is estimated to be between 11% and 33% [7,8]. In these cases, the challenge lies in the need to repair the meniscal tear and simultaneously reshape the lateral meniscus, as meniscectomy alone generally leads to poor long-term outcomes.

However, reoperations are necessary in up to 30% of cases with meniscal repair [8]. A concurrent cruciate ligament rupture poses a particular risk, whereas the time interval between injury and reconstruction is likely to be of little consequence [7, 17]. Another problem is the persistent limitation of extension in up to 60% of cases [8].

Conclusion

A patellar sleeve fracture occurring in close temporal succession with a bucket-handle tear of the lateral meniscus is a previously undescribed combination of injuries in childhood. The connection with constitutionally determined knee instability is plausible. Both injuries require timely and appropriate treatment to preserve the knee joint's range of motion and load-bearing capacity.

Declarations

Ethics and consent to participate: According to institutional policy, ethical approval was not required for this case report.

Consent to publish: Written informed consent was obtained from the patient's parents or legal guardians for publication of this case report and any accompanying images. A copy of the written consent is available for review by the Editor-in-Chief of this journal.

Availability of data and materials: All data generated or analyzed during this study are included in this published article.

Competing interests: All authors declare that there is no conflict of interest concerning this manuscript.

Funding: The authors received no specific funding for this work.

Authors' contributions: R.K. conceived the study, treated the patient, performed the literature review, and drafted the manuscript. G.K. participated in the surgical

treatment, contributed to the interpretation of the clinical findings, and critically revised the manuscript. J.P. contributed to the interpretation of the radiological and clinical findings, prepared the figures, and critically revised the manuscript. J.P. and T.T. supervised the study, contributed to the interpretation of the findings, and critically revised the manuscript. All authors read and approved the final manuscript.

Acknowledgements: Not applicable.

References:

1. Fernandez F, Loose O, Rose S. Patellafrakturen. In: Schmittenbecher P, Sommerfeldt D (Hrsg): Praxis der Kinder- und Jugendtraumatologie. 2. Auflage, Springer 2024 509-512
2. Shimasaki K, Uesugi M, Kobayashi T, Tanaka H, Ichimura H. Inferior Pole Sleeve Fracture of the Patella in an Adolescent: A Case Report.Cureus. 2023 Jan 7;15(1):e33494. doi: 10.7759/cureus.33494. eCollection 2023 Jan.PMID: 36756006
3. Siddiqui R, Singh A, Cullinan C. Superior Pole Sleeve Fracture of the Patella in an Adolescent: A Case Report. JBJS Case Connect. 2020 Jul-Sep;10(3):e20.00007. doi: 10.2106/JBJS.CC.20.00007.PMID: 32865951
4. He WP, Ren CM, Luo F, Chen L, Wang WT, Qiu BT, Zhang XC, Chen HT. Bilateral sleeve fracture of the superior pole of the patella in a healthy adult: A case report. World J Orthop. 2025 Nov 18;16(11):110173. doi: 10.5312/wjo.v16.i11.110173. eCollection 2025 Nov 18.PMID: 41355838
5. Beatty EW, Hupin M, Kramer DE, Shore BJ, Heyworth BE.J Outcomes of treatment of patella fractures in children and adolescents. Child Orthop. 2024 Mar 20;18(3):258-265. doi: 10.1177/18632521241232301. eCollection 2024 Jun.PMID: 38831855

6. Devana SK, Trivellas A, Bennett A, Jackson N, Beck JJ. Clinical and Radiographic Differentiation of Pediatric Patellar Sleeve Fractures and Other Inferior Pole Pathologies. Am J Sports Med. 2022 Mar;50(4):977-983. doi: 10.1177/03635465221073995. Epub 2022 Feb 10.PMID: 35142232
7. Canton G, Maritan G, Impellizzeri F, Formentin C, Murena L. Bucket-handle meniscal tears in children under the age of 10: a literature review. Acta Biomed. 2021 Jul 26;92(S3):e2021020. doi: 10.23750/abm.v92iS3.11742.
8. Kramer DE, Kalish LA, Martin DJ, Yen YM, Kocher MS, Micheli LJ, Heyworth BE. Outcomes After the Operative Treatment of Bucket-Handle Meniscal Tears in Children and Adolescents. Orthop J Sports Med. 2019 Jan 15;7(1):2325967118820305. doi: 10.1177/2325967118820305. eCollection 2019 Jan
9. Yalçin N, Bektaşer B, Ciçekli O, Doşan M. [Buck et-handle tear of a discoid lateral meniscus in a 6-year-old girl]. Acta Orthop Traumatol Turc. 2009;43(6):528-31
10. Patel S, Wall EJ, Parikh SN. An Update on Meniscus Tears and Lower Limb Alignment in Pediatric Sports Injuries. Instr Course Lect. 2026;75:561-570
11. Turati M, Accadbled F, Tercier S, Thüsing M, Rigamonti L, Sinikumpu J, Tschopp B, Nicolaou N. Paediatric knee fractures: A current concept review. J Child Orthop. 2025 May 31;19(3):213-220. doi: 10.1177/18632521251327129. eCollection 2025 Jun.PMID: 40458206
12. Sullivan S, Maskell K, Knutson T. Patellar sleeve fracture. West J Emerg Med. 2014 Nov;15(7):883-4. doi: 10.5811/westjem.2014.8.22265.
13. Schütte V, Schmidt-Hebbel A, Imhoff AB, Achtnich A. Patellar sleeve fractures : Bracing and augmentation technique with suture tape. Oper Orthop

Traumatol. 2019 Feb;31(1):56-62. doi: 10.1007/s00064-018-0581-5.PMID: 30539194

14. Chotel F, Fauré F. Major Quadriceps Gap After Neglected Patellar Sleeve Fracture in a Child: A Case Report. JBJS Case Connect. 2026 Jan 29;16(1). doi: 10.2106/JBJS.CC.25.00367. eCollection 2026 Jan 1.PMID: 41610219
15. Kimball MJ, Kumar NS, Jakoi AM, Tom JA. Subacute superior patellar pole sleeve fracture. Am J Orthop (Belle Mead NJ). 2014 Jan;43(1):29-32.
16. Dale KM, Tenfelde A. Pediatric Meniscal Tears. Sports Med Arthrosc Rev. 2024 Dec 1;32(4):169-175.
17. Hampton M, Ali F, Nicolaou N, Ajuied A; Paediatric Meniscal Working Group. The management of isolated meniscal tears in skeletally immature children. An international expert consensus. Knee Surg Sports Traumatol Arthrosc. 2025 Apr;33(4):1259-1269. doi: 10.1002/ksa.12493. Epub 2024 Oct 24.

Supplementary Files

This is a list of supplementary files associated with this preprint. Click to download.

- CAREchecklist.pdf