Research Square

Preprints are preliminary reports that have not undergone peer review.
They should not be considered conclusive, used to inform clinical practice,
or referenced by the media as validated information.

Propranolol as Salvage Treatment in Children with Kasabach–Merritt Phenomenon Refractory to Sirolimus Plus Prednisolone

Yujia Zhang
West China Hospital of Sichuan University
Jiangyuan Zhou
West China Hospital of Sichuan University
Tong Qiu
West China Hospital of Sichuan University
Yuru Lan
West China Hospital of Sichuan University
Min Yang
West China Hospital of Sichuan University
Yunyan Han
West China Hospital of Sichuan University
Zixin Zhang
West China Hospital of Sichuan University
Xuepeng Zhang
West China Hospital of Sichuan University
Yi Ji
jijiyuanyuan@163.com

West China Hospital of Sichuan University

Research Article

Keywords: Kaposiform hemangioendothelioma, Kasabach–Merritt phenomenon, Propranolol, Sirolimus

Posted Date: November 25th, 2026

DOI: https://doi.org/10.21203/rs.3.rs-10335427/v1

License: This work is licensed under a Creative Commons Attribution 4.0 International License.
Read Full License

Additional Declarations: No competing interests reported.

Propranolol as Salvage Treatment in Children with Kasabach–Merritt Phenomenon Refractory to Sirolimus Plus Prednisolone

Yujia Zhang[a, #], Jiangyuan Zhou[a, b, #], Tong Qiu[a, b], Yuru Lan[a], Min Yang[a], Yunyan Han[a], Zixin Zhang[a, b], Xuepeng Zhang[c], Yi Ji[a, b*]

Affiliations:

[a]Department of Pediatric Surgery, West China Hospital, Sichuan University, Chengdu, 610041, China;

[b]Med-X Center for Informatics, Sichuan University, Chengdu, 610041, China;

[c]Department of Critical Care Medicine, West China Hospital, Sichuan University, Chengdu, 610041, China

[#]Contributed equally as co-first authors.

*** Correspondence:**

Yi Ji, MD, PhD, Division of Oncology, Department of Pediatric Surgery, West China Hospital of Sichuan University. 37# Guo-Xue-Xiang, Chengdu, 610041, China. Tel: +86 18980606865; Fax: +86 28 85423453; jijiyuanyuan@163.com.

Short title: Sirolimus Plus Propranolol for KHE with KMP

Keywords: Kaposiform hemangioendothelioma; Kasabach–Merritt phenomenon; Propranolol; Sirolimus

Abstract:

Background: Kaposiform hemangioendothelioma complicated by Kasabach–Merritt phenomenon is a rare but potentially life-threatening vascular tumor associated with severe thrombocytopenia and consumptive coagulopathy. Although sirolimus-based therapy has improved outcomes, some children have an inadequate early response or poor tolerance to corticosteroids, creating a need for alternative treatment strategies. This study evaluated the efficacy of switching from sirolimus plus prednisolone to sirolimus plus propranolol in children with kaposiform hemangioendothelioma complicated by Kasabach–Merritt phenomenon who did not respond adequately to initial treatment.

Results: This retrospective self-controlled study included 14 children. After switching to sirolimus plus propranolol, the cumulative durable platelet response rate was 57.1% at week 3 and 71.4% at week 4. Stabilization of fibrinogen levels was achieved in 64.3% of patients at week 4. By week 8 of treatment with sirolimus plus propranolol, the durable platelet response rate increased to 92.9%, and the fibrinogen stabilization rate reached 78.6%. All patients achieved overall lesion control during follow-up. Clinical trial number: not applicable.

Conclusions: Switching to sirolimus plus propranolol may promote hematologic recovery and lesion improvement in selected children with refractory kaposiform hemangioendothelioma complicated by Kasabach–Merritt phenomenon, and may offer a potential corticosteroid-sparing salvage strategy. However, because of the

retrospective design, small sample size, and limited mechanistic evidence, prospective studies are needed to better define the efficacy, safety, and optimal role of this combination regimen.

1. Introduction

Kaposiform hemangioendothelioma (KHE) is a rare, locally invasive vascular tumor that often occurs in infancy and early childhood. It is characterized by invasive growth and frequently involves deep tissues. KHE may be complicated by the Kasabach–Merritt phenomenon (KMP), a life-threatening consumptive coagulopathy marked by profound thrombocytopenia, hypofibrinogenemia, and secondary coagulation abnormalities[1-4]. The KMP occurs in a substantial proportion of patients with KHE and remains a major determinant of morbidity and mortality, particularly in those with large, deep, or intracavitary lesions[5].

Over the past decade, sirolimus has emerged as a key therapeutic option for KHE[6, 7], especially in patients with KMP, owing to its inhibitory effects on the PI3K/AKT/mTOR pathway[8-10]. Especially for KHE patients with KMP, sirolimus combined with corticosteroids, including prednisolone, can increase blood stability and is currently the first-line treatment option[7, 11-13]. However, a subset of patients respond poorly to sirolimus plus corticosteroids, and the optimal salvage strategies for refractory patients in these treatment groups remain unclear.

Propranolol is well established as a first-line therapy for infantile hemangioma (IH)[14-16], but its role in KHE is variable. Given the biological differences between IH and KHE, the therapeutic benefit of propranolol in KHE cannot be assumed. Some case reports and limited clinical observations have suggested that propranolol may exert adjunctive effects in selected patients with KHE[17, 18]. Whether switching

from sirolimus plus prednisolone to sirolimus plus propranolol can improve hematologic and lesion outcomes in children with KHE complicated by the KMP who fail initial combination therapy has not been systematically studied. Therefore, this study aimed to investigate the efficacy of sirolimus plus propranolol in this specific high-risk population using a retrospective self-controlled design.

2. Methods

2.1 Patients

This retrospective self-controlled before-and-after study was based on the KHE treatment cohort at West China Hospital, Sichuan University. From January 2012 to December 2023, patients with KHE complicated by the KMP who had received sirolimus plus prednisolone were screened.

The inclusion criteria were as follows: (1) were diagnosed with KHE at West China Hospital, Sichuan University; (2) had received sirolimus plus prednisolone for at least 8 weeks and were evaluated as treatment nonresponders; and (3) discontinued prednisolone and switched to propranolol while continuing sirolimus, thus receiving a sirolimus plus propranolol regimen for at least 8 weeks. The exclusion criteria were as follows: (1) age at disease onset >18 years; (2) incomplete clinical data; (3) other known diseases causing thrombocytopenia; and (4) severe cardiopulmonary insufficiency or contraindications to propranolol.

2.2 Treatment regimen

All patients initially received sirolimus plus prednisolone. Sirolimus was initiated

orally at 0.8 mg/m² per dose every 12 hours, and the dose was subsequently adjusted according to the trough concentration, with a target trough concentration ranging from 5–15 ng/mL. Concurrent prednisolone was administered orally at 2 mg/kg once daily. Patients who were assessed as nonresponders after 8 weeks of combination therapy discontinued prednisolone and were switched to propranolol while the sirolimus regimen was maintained. Propranolol was initiated at 1.0 mg/kg/day in two oral doses and was gradually increased to the target dosage of 2.0 mg/kg/day according to tolerance in terms of heart rate and blood pressure. After the patient's coagulation function indicators stabilized, propranolol was discontinued, and sirolimus monotherapy was used for maintenance treatment.

2.3 Data collection

Using the initiation of propranolol as the reference time point, data from the following two periods were retrospectively collected:

Late sirolimus + prednisolone period (4 weeks before switching, i.e., weeks 5–8): weekly platelet counts and fibrinogen levels. The last 4 weeks of the initial regimen, rather than the first 4 weeks, were chosen as the control period because sirolimus would have had sufficient time to exert its pharmacologic effect, while the response remained inadequate, thereby better reflecting the incremental effect of adding propranolol and avoiding interference from the early phase before stable sirolimus exposure was achieved.

Sirolimus + propranolol period (weeks 1–8 after switching): weekly platelet counts

and fibrinogen levels, as well as imaging assessment data of tumor lesions at 6 and 12 months after treatment.

All patients underwent complete blood count and coagulation testing once weekly. For each patient, paired comparisons were performed between the late sirolimus + prednisolone period and the early sirolimus + propranolol period by corresponding weeks (i.e., week 5 vs. week 1 after switching, week 6 vs. week 2, week 7 vs. week 3, and week 8 vs. week 4).

2.4 Outcomes

The primary outcome was the cumulative durable platelet response rate at week 4 after switching to sirolimus plus propranolol. Secondary outcomes included the cumulative durable platelet response rates at weeks 1–3 and week 8 after switching, as well as the fibrinogen stabilization rates at weeks 4 and 8 after switching. A durable platelet response was defined as a platelet count $\geq 100 \times 10^9$/L with maintenance of this level in the subsequent four consecutive weekly assessments. The durable platelet response rate at each week was expressed as the cumulative response rate, namely, the proportion of patients who had achieved this endpoint by that week and maintained it thereafter. Fibrinogen stabilization was defined as a fibrinogen concentration ≥ 1.6 g/L. Serial volumetric magnetic resonance imaging was performed at 6 and 12 months after treatment and every 12 months thereafter. The tumor volume at 12 months after treatment was compared with the baseline volume. The regression of KHE lesions was defined as a reduction in the volume of KHE lesions by more than 20% after 12

months of treatment.

2.5 Definitions

KHE lesions were classified into three groups: superficial, mixed and deep[19]. The KMP was defined as thrombocytopenia with a platelet count <100 × 10^9/L in the context of KHE, accompanied by hypofibrinogenemia and consumptive coagulopathy[1, 19]. Hypofibrinogenemia was defined as a fibrinogen concentration <1.6 g/L. Consumptive coagulopathy was defined as a low fibrinogen concentration (<1.6 g/L) together with an elevated D-dimer concentration (>0.5 μg/mL). Restricted range of motion was defined as extension ≥10°, flexion <120°, or both[20]. Chronic pain was defined as daily pain lasting ≥3 months[20]. KHE-associated lymphedema was defined as lymphedema that persisted for 6 months or longer after the onset of KHE and/or the KMP[21]. Failure of the initial sirolimus combination regimen was defined as a platelet count still <100 × 10^9/L after 8 weeks of sirolimus plus prednisolone treatment. A positive Stemmer sign was defined as the inability to pinch a fold of skin at the dorsum of the second toe (or the distal part of the affected limb)[22].

2.6 Statistical analysis

Statistical analyses were performed using IBM SPSS Statistics version 27.0. Continuous variables are presented as the mean (range) or median (range), as appropriate. Continuous variables were analyzed according to their distribution and study design using the independent-samples t test, Mann–Whitney U test, or

Wilcoxon signed-rank test, as appropriate. Categorical variables are presented as counts and percentages and were compared using the chi-square test or Fisher's exact test. All the statistical tests were two-sided, and $P<0.05$ was considered to indicate statistical significance.

In the analysis of the efficacy of propranolol in patients with KHE complicated by the KMP who did not respond to sirolimus plus prednisolone, paired comparisons of platelet counts and fibrinogen levels were performed between the late sirolimus + prednisolone period (weeks 5–8) and the early sirolimus + propranolol period (weeks 1–4 after switching) at corresponding time points using the Wilcoxon signed-rank test, and median differences with 95% CIs were estimated using the Hodges–Lehmann method. Because all the enrolled patients were defined as nonresponders to sirolimus + prednisolone at 8 weeks and therefore had a 0% platelet response rate before switching, paired comparisons or calculations of paired odds ratios were not feasible. Accordingly, the response rates after switching were analyzed as follows: (1) the cumulative durable platelet response rate and the instantaneous response rate at each week were reported as absolute proportions; (2) 95% CIs for weekly response rates were calculated using the exact binomial method (Clopper–Pearson method); and (3) McNemar's test was used to compare cumulative durable platelet response rates between weeks 4 and 8.

3. Results

3.1 Baseline characteristics

A total of 14 patients with KHE complicated by the KMP were ultimately included in this study (Table 1). There were 8 (57.1%) boys and 6 (42.9%) girls. The mean age at KHE diagnosis was 7.1 (0–20.5) months, with a median of 4.8 months. The mean age at KMP onset was 4.7 (0–15.8) months, with a median of 3 months. Both the mean and median ages indicated that the KMP occurred earlier than the confirmed diagnosis of KHE, suggesting that most patients had already developed platelet consumption and coagulation abnormalities before a definitive diagnosis was established.

No purely superficial lesions were observed in this cohort; all included cases involved disease beyond the superficial skin layer. Mixed lesions were the predominant type, occurring in 10 (71.4%) patients, whereas deep lesions were present in 4 (28.6%) patients. Thus, the study population included mainly patients with extensive infiltration and deep tissue involvement. With respect to lesion distribution, multiple anatomical sites could be involved in a single patient. Further analysis revealed that 10 (71.4%) patients had intracavitary involvement, indicating that most patients had extensive disease with deep extension. In terms of lesion size, 12 (85.7%) patients had a maximum lesion diameter ≥5 cm, whereas only 2 (14.3%) patients had lesions <5 cm.

Importantly, all patients had received sirolimus plus prednisolone as initial therapy before switching to propranolol. The duration of prior combination therapy was 8 weeks for all patients, and prednisolone was orally administered at 2 mg/kg once daily. Treatment failure was uniformly defined as a platelet count remaining $<100 \times 10^9$/L after 8 weeks of treatment with sirolimus plus prednisolone, indicating a

persistent KMP despite standard combination therapy.

3.2 Efficacy analysis

Overall, after the regimen was switched, patients showed favorable therapeutic responses in terms of platelet recovery and fibrinogen improvement.

Using the cumulative durable platelet response rate at the paired week 4 assessment as the primary outcome, 10 of 14 patients achieved a durable platelet response at the paired week 4 assessment, yielding a response rate of 71.4% (95% CI, 41.9%–91.6%), which represented a statistically significant improvement from the preswitch status (p=0.002). These findings suggest that, among patients who responded poorly to prior sirolimus plus prednisolone therapy, switching to sirolimus plus propranolol enabled most patients to achieve a clear and sustained platelet response within 4 weeks (Table 2).

Secondary outcome analysis revealed that durable platelet responses emerged progressively during the early treatment period and accumulated over time. At week 1 after switching, only a small proportion of patients achieved a durable platelet response; this proportion increased further at week 2, and the difference reached statistical significance by week 3. By the paired week 8 assessment, the number of patients with a durable platelet response had increased to 13, corresponding to a cumulative response rate of 92.9% (P<0.001). These findings indicate that the efficacy of sirolimus plus propranolol was not instantaneous but rather accumulated over the first several weeks of treatment and reached a high level within 8 weeks. The

only patient who did not meet the criteria for a durable platelet response at week 8 also showed no obvious improvement in coagulation function. Because of the inadequate hematologic response, propranolol was discontinued, and the regimen was changed to sirolimus plus aspirin. A durable platelet response was then achieved 2 weeks after this treatment was modified. Therefore, although one patient did not respond within the predefined 8-week evaluation window, hematologic remission was ultimately achieved in all patients after subsequent treatment adjustment.

Paired analyses of continuous variables further supported these findings (Table 3). Compared with those at the corresponding time points during the late sirolimus + prednisolone period, the platelet counts at all paired time points during the early sirolimus + propranolol period were markedly greater, and the magnitude of improvement increased over time (Figure 1). The Hodges–Lehmann median difference increased from 26.0 × 10^9/L at the week 1 paired comparison to 157.0 × 10^9/L at the week 4 paired comparison, with statistically significant differences at all time points (all p=0.001). These results indicate that after switching to sirolimus + propranolol, platelet levels not only increased rapidly but also continued to increase over subsequent weeks, suggesting that substantial hematologic benefit could be achieved early and further enhanced thereafter. Fibrinogen levels also improved. At the paired week 4 assessment, the fibrinogen stabilization rate was 64.3%, which represented a statistically significant improvement from the preswitch period (p=0.031). Analysis of the continuous data likewise revealed that fibrinogen levels increased significantly after switching compared with those before switching

(p=0.035).

In terms of lesion control, all 14 patients achieved a lesion response, yielding an overall lesion response rate of 100.0% (95% CI, 76.8%–100.0%), indicating that all patients showed some degree of improvement in imaging or clinical lesion status (Figures 2).

3.3 Complications

In terms of complications, both restricted range of motion and organ dysfunction were observed in 28.6% of patients (95% CI, 8.4%–58.1%), structural deformity was observed in 7.1% (95% CI, 0.2%–33.9%), and bone destruction was observed in 14.3% (95% CI, 1.8%–42.8%). Overall, functional complications were more common in this group, mainly manifested as limited movement and organ dysfunction, whereas structural damage was less frequent, with structural deformity and bone destruction observed only in a small number of patients. No lymphedema was observed. Taken together, these findings suggest that although sirolimus plus propranolol may effectively control disease activity and improve short-term outcomes, its ability to reverse preexisting tissue damage and functional impairment accrued during the earlier disease course may be limited. Therefore, in addition to improvements in lesions and laboratory parameters, attention should also be given to subsequent functional recovery and long-term quality of life.

4. Discussion

In recent years, the pharmacologic treatment of KHE has gradually shifted from

empirical regimens based mainly on corticosteroids and vincristine to targeted therapeutic strategies centered on sirolimus[6]. Particularly for high-risk children with the KMP, current consensus recommendations and randomized controlled studies have shown that sirolimus has become a key component of treatment and that sirolimus combined with prednisolone can correct thrombocytopenia and induce coagulopathy more rapidly than sirolimus alone can[7, 11, 12, 23-25]. Although the overall response rate is relatively high, in clinical practice, a subset of patients still fail to achieve the expected benefit after treatment with sirolimus plus prednisolone, manifesting as unsatisfactory platelet recovery, persistently low fibrinogen levels, or disease recurrence after treatment discontinuation[11, 19]. Therefore, when high-risk patients fail to respond adequately to standard therapy, clinicians often face the practical dilemma of what to do next, and this is precisely an area in KHE research where the evidence remains relatively limited. The present study focused on a clinically relevant question: can switching to sirolimus plus propranolol after 8 weeks of ineffective treatment with sirolimus plus prednisolone improve hematologic outcomes? We found that, in these patients, this regimen was associated with improvements in both the platelet response rate and the fibrinogen stabilization rate, promoted sustained platelet recovery within a relatively short period, and achieved a favorable overall lesion response. These findings suggest that this regimen may have short-term efficacy and potential clinical value in some patients with refractory disease.

The reported efficacy of propranolol in treating KHE remains inconsistent in the

literature. In a study of 11 children with KHE/tufted angioma, only approximately 36% responded to propranolol; therefore, the authors concluded that propranolol should not be recommended as a routine first-line treatment for KHE[16]. More recently, a prospective study suggested that propranolol may have some activity in selected cutaneous KHE lesions; however, the sample size was only 11 cases, most of which were superficial lesions, making it difficult to extrapolate these findings to high-risk patients with deep lesions or severe KMP[17]. Case reports have shown that propranolol may serve as a second-line treatment and lead to sustained improvement in children with KHE complicated by the KMP who respond poorly to other therapies[26]. In light of the efficacy observed in the present study, we speculate that propranolol and sirolimus may have a partially synergistic effect on the treatment of KHE. This effect may involve broader local hemodynamic alterations and modulation of angiogenesis-related signaling pathways[27, 28], thereby playing a complementary role in the treatment of KHE[3].

Among patients with KHE complicated by the KMP who respond poorly to sirolimus plus prednisolone, the more rapid platelet recovery observed after the addition of propranolol suggests that propranolol may contribute more than a nonspecific anti-inflammatory effect. A possible explanation is that propranolol acts synergistically with sirolimus by targeting complementary aspects of lesion biology, particularly lesional microhemodynamics, vascular–lymphatic permeability, and the platelet consumption loop underlying the KMP (Figure 3). Sirolimus is believed to act primarily through the inhibition of mTOR-dependent cellular proliferation,

angiogenesis, lymphangiogenesis, and inflammatory signaling in KHE[8, 29-32]. In contrast, propranolol may exert a more immediate functional effect by blocking β-adrenergic signaling, thereby inducing vasoconstriction, altering pericyte-associated contractility, and reducing abnormal vascular perfusion, tissue edema, and lymphatic leakage[2, 33]. In the setting of KHE, these changes may decrease lesion congestion and exudation while also limiting platelet entry into abnormal vascular channels and reducing intralesional platelet trapping and localized consumptive coagulopathy.

In addition to its hemodynamic effects, propranolol may also suppress upstream proangiogenic signaling. Studies of IH and other vascular anomaly models have shown that propranolol can inhibit HIF-1α/VEGF-related signaling, downregulate PI3K/AKT and MAPK pathway activity, and reduce endothelial proliferation, migration, and vascular-like structure formation[34-37]. It may also suppress matrix remodeling molecules such as MMP-2 and MMP-9, thereby limiting lesion invasion and infiltration[38, 39]. Moreover, sirolimus directly blocks mTOR, a key downstream effector in the PI3K/AKT/mTOR pathway, and may further suppress lesion growth by inhibiting endothelial proliferation[9, 29, 40], reducing VEGF-C expression, and limiting lymphangiogenesis[9, 29].

Because propranolol may preferentially attenuate upstream β-adrenergic and hypoxia-related proangiogenic signaling, whereas sirolimus inhibits a major downstream growth regulatory node, the two agents may provide complementary upstream and downstream suppression of lesion activity. Moreover, propranolol may reduce the opportunity for platelets to enter and become sequestered within abnormal vascular

spaces, whereas sirolimus may mitigate the procoagulant and consumption state by reducing platelet aggregation, adhesion, and fibrin formation. By acting at different levels of the KMP consumption cycle, the combination may therefore facilitate more rapid recovery from thrombocytopenia and coagulopathy than sirolimus-based therapy alone does.

This potential benefit may be particularly relevant in patients with body cavity involvement, serous effusions, marked edema, or diffuse infiltrative disease, in whom permeability-related fluid shifts, lymphatic dysfunction, and lesional hemodynamic abnormalities are likely to contribute substantially to disease activity. Nevertheless, direct mechanistic evidence for propranolol in KHE treatment remains limited, and many of these inferences are extrapolated from studies of IH, lymphatic malformations, and other vascular anomalies. Therefore, the synergistic effect of propranolol combined with sirolimus should currently be regarded as a biologically plausible hypothesis supported by indirect evidence and clinical observation, rather than a confirmed mechanism, and warrants further validation in both experimental and clinical studies.

On the basis of the currently available evidence, propranolol may be considered an individualized adjunctive option under close monitoring rather than a substitute for established first-line therapy. Potential candidates may include children with severe KMP, rapidly progressive disease, or an unsatisfactory early response to sirolimus plus prednisolone. In these challenging clinical settings, the addition of propranolol may offer a practical salvage or complementary strategy, particularly when prompt

hematologic improvement is desired and alternative options are limited. Nevertheless, given the limited direct evidence supporting the use of propranolol in patients with KHE, caution should be taken when it is used, and its use should be highly individualized. Before treatment initiation, contraindications such as bradycardia, hypotension, bronchospasm, and hypoglycemia should be carefully excluded, and relevant adverse events should be closely monitored during therapy[15, 16]. In addition, the treatment response should be assessed dynamically on the basis of platelet count, fibrinogen level, lesion status, and overall clinical course so that the regimen can be adjusted in a timely manner according to efficacy and tolerability.

This study has several limitations. First, this was a retrospective analysis and is therefore subject to inherent selection bias and residual confounding. However, some of the patients in this study were derived from a previously reported randomized controlled study based on sirolimus by our team[11], which was registered on ClinicalTrials.gov (NCT03188068), and this improved the consistency of diagnosis, treatment and follow-up. In addition, the sample size was small. Nevertheless, KHE complicated by the KMP is a rare disease, and patients refractory to sirolimus with or without corticosteroids are even less common. To our knowledge, this study currently represents one of the largest, focused series specifically evaluating a salvage approach for patients with KHE/KMP who failed treatment prior to receiving sirolimus-based therapy. Furthermore, because patients were switched from sirolimus plus prednisolone to sirolimus plus propranolol, the observed benefit cannot be attributed entirely to propranolol alone. The potential delayed effect of sirolimus, the impact of

corticosteroid withdrawal, and the natural course of disease may have contributed to the outcomes, despite our use of the late sirolimus + prednisolone period as the self-control phase. Moreover, without randomization or concurrent controls such as those with continued sirolimus alone, with reintroduction of corticosteroids, or with alternative salvage regimens, determining whether sirolimus plus propranolol is superior to other potential regimens remains difficult. This is an important methodological limitation. However, in children with KHE complicated by the KMP, prolonged thrombocytopenia and consumptive coagulopathy are associated with substantial risks of bleeding, rapid clinical deterioration, and even death; therefore, a washout design is often not ethically or clinically feasible in this high-risk setting. Finally, this study evaluated mainly short-term hematologic improvement and radiologic lesion response. Although these outcomes are clinically important, larger prospective multicenter studies are still needed to confirm the long-term efficacy, safety, and functional benefits of this strategy.

5. Conclusion

In children with KHE complicated by the KMP who showed an inadequate response to sirolimus plus prednisolone, switching to sirolimus plus propranolol was associated with improved platelet recovery, better fibrinogen stabilization, and favorable lesion control in this retrospective self-controlled study. These findings suggest that propranolol may serve as a potential adjunctive or salvage option for selected high-risk patients with refractory disease. However, given the small sample size, retrospective design, and limited mechanistic evidence, larger prospective studies are

389 needed to further clarify the efficacy, safety, and optimal role of this regimen in the
390 treatment of KHE with the KMP.

391 6. Abbreviations

AKT	Protein kinase B
CI	Confidence interval
HIF-1α	Hypoxia-inducible factor-1 alpha
IH	Infantile hemangioma
KHE	Kaposiform hemangioendothelioma
KMP	Kasabach-Merritt phenomenon
MAPK	Mitogen-activated protein kinase
MMP-2	Matrix Metalloproteinase-2
MMP-9	Matrix Metalloproteinase-9
MRI	Magnetic resonance imaging
mTOR	Mammalian of the target of rapamycin
PI3K	Phosphatidylinositol 3-kinase
VEGF-C	Vascular endothelial growth factor C

392 7. Author Contributions

393 Conception and design: YJZ, JYZ, TQ; Provision of study material or patients: YJ;
394 Literature research: YJZ, JYZ, TQ, YRL, MY, YYH, ZXZ, XPZ; Collection and
395 assembly of data: YJZ, JYZ, TQ, YRL, MY, YYH, ZXZ, XPZ; Data analysis and
396 interpretation: YJZ, JYZ, TQ; Manuscript preparation: YJZ, JYZ, TQ; Manuscript

editing: YJZ, JYZ, TQ, YJ; Manuscript revision/review: YJZ, JYZ, TQ, YJ; Manuscript final version approval: All authors.

8. Consent for publication

Consent for publication was obtained from the patients' parents or legal guardians.

9. Funding

This work was supported by the National Natural Science Foundation of China (grant numbers 82473553 and 82273556), the Excellent Youth Foundation of Sichuan Province of China (grant number 2025NSFJQ0070), the Natural Science Foundation of Sichuan Province of China (2025ZNSFSC0666, 2025ZNSFSC1525, and 2025ZNSFSC1547), the '0 to 1' Project of Sichuan University (grant number 2022SCUH0033), the Med-X Center for Informatics Funding Project (YGJC004), the 1·3·5 Project for Disciplines of Excellence-Clinical Research Incubation Project of West China Hospital of Sichuan University (grant number 2023HXFH004), and the 1·3·5 Project for Disciplines of Excellence-Clinical Research Interdisciplinary Innovation Project of West China Hospital of Sichuan University (ZYJC21060).

9. Acknowledgments

We specifically thank the patients and their parents for their cooperation and consent to publish this article.

10. Data Availability Statement

The original contributions presented in the study are included in the article, further

inquiries can be directed to the corresponding author.

11. Ethics approval and consent to participate

The study was conducted in compliance with the Declaration of Helsinki and was approved by the Ethics Committee of West China Hospital, Sichuan University. Due to the retrospective nature of the study, the requirement for informed consent to participate was waived by the Ethics Committee.

12. Conflicts of interest

None.

13. Declarations

Clinical trial number: not applicable.

References

1. Croteau SE, Liang MG, Kozakewich HP, Alomari AI, Fishman SJ, Mulliken JB, Trenor CC, 3rd: Kaposiform hemangioendothelioma: atypical features and risks of Kasabach-Merritt phenomenon in 107 referrals. *J Pediatr* 2013, 162(1):142-147.
2. Ji Y, Chen S, Xu C, Li L, Xiang B: The use of propranolol in the treatment of infantile haemangiomas: an update on potential mechanisms of action. *Br J Dermatol* 2015, 172(1):24-32.
3. Zhou J, Yang K, Dai S, Qiu T, Zhang X, Gong X, Chen S, Ji Y: Clinical features and management of kaposiform hemangioendothelioma and tufted angioma: Similarities and differences. *J Am Acad Dermatol* 2022, 87(1):172-174.
4. Borst AJ, Eng W, Griffin M, Ricci KW, Engel E, Adams DM, Dayneka J, Cohen-Cutler SJ, Andreoli SM, Wu MD *et al*: Treatment practices and response in kaposiform hemangioendothelioma: A multicenter cohort study. *Pediatr Blood Cancer* 2024, 71(3):e30779.
5. Zhou J, Lan Y, Qiu T, Gong X, Zhang Z, He C, Peng Q, Hu F, Zhang X, Lu G *et al*: Impact of age and tumor size on the development of the Kasabach-Merritt phenomenon in patients with kaposiform hemangioendothelioma: a retrospective cohort study. *Precis Clin Med* 2023, 6(2):pbad008.
6. Huang X, Jin J, Li Y, Zhang Y, Zhang L, Si W, Yang K: Clinical treatment, research topic and global trends of Kaposiform hemangioendothelioma: a review and bibliometric analysis. *Int J Surg* 2025.
7. Zhou J, Qiu T, Zhang Z, Lan Y, Huo R, Xiang B, Chen S, Qiu L, Xia C, Xu X *et al*:

Consensus statement for the diagnosis, treatment, and prognosis of kaposiform hemangioendothelioma. *Int J Cancer* 2025, 156(10):1986-1994.

8. Ji Y, Chen S, Yang K, Xia C, Li L: Kaposiform hemangioendothelioma: current knowledge and future perspectives. *Orphanet J Rare Dis* 2020, 15(1):39.

9. Adams DM, Trenor CC, 3rd, Hammill AM, Vinks AA, Patel MN, Chaudry G, Wentzel MS, Mobberley-Schuman PS, Campbell LM, Brookbank C *et al*: Efficacy and Safety of Sirolimus in the Treatment of Complicated Vascular Anomalies. *Pediatrics* 2016, 137(2):e20153257.

10. Wang Z, Li K, Yao W, Dong K, Xiao X, Zheng S: Steroid-resistant kaposiform hemangioendothelioma: a retrospective study of 37 patients treated with vincristine and long-term follow-up. *Pediatr Blood Cancer* 2015, 62(4):577-580.

11. Ji Y, Chen S, Zhou J, Yang K, Zhang X, Xiang B, Qiu T, Gong X, Zhang Z, Lan Y *et al*: Sirolimus plus prednisolone vs sirolimus monotherapy for kaposiform hemangioendothelioma: a randomized clinical trial. *Blood* 2022, 139(11):1619-1630.

12. Drolet BA, Trenor CC, 3rd, Brandão LR, Chiu YE, Chun RH, Dasgupta R, Garzon MC, Hammill AM, Johnson CM, Tlougan B *et al*: Consensus-derived practice standards plan for complicated Kaposiform hemangioendothelioma. *J Pediatr* 2013, 163(1):285-291.

13. Gasparella P, Haxhija EQ, Andersen R, Barea M, Baselga E, Serrano MB, Berger S, Bisdorff AA, Boccara O, Borgards P *et al*: The VASCERN-VASCA diagnostic and management pathways for kaposiform hemangioendothelioma. *Eur J Pediatr* 2025, 185(1):14.

14. Krowchuk DP, Frieden IJ, Mancini AJ, Darrow DH, Blei F, Greene AK, Annam A, Baker CN, Frommelt PC, Hodak A *et al*: Clinical Practice Guideline for the Management of Infantile Hemangiomas. *Pediatrics* 2019, 143(1).

15. Léauté-Labrèze C, Hoeger P, Mazereeuw-Hautier J, Guibaud L, Baselga E, Posiunas G, Phillips RJ, Caceres H, Lopez Gutierrez JC, Ballona R *et al*: A randomized, controlled trial of oral propranolol in infantile hemangioma. *N Engl J Med* 2015, 372(8):735-746.

16. Chiu YE, Drolet BA, Blei F, Carcao M, Fangusaro J, Kelly ME, Krol A, Lofgren S, Mancini AJ, Metry DW *et al*: Variable response to propranolol treatment of kaposiform hemangioendothelioma, tufted angioma, and Kasabach-Merritt phenomenon. *Pediatr Blood Cancer* 2012, 59(5):934-938.

17. Wei L, Li L, Xu Z, Zhang B, Han X, Wang C, Liu Y, Xiu B, Qiu L, Sun Y *et al*: Comparison of Effectiveness of Two Different Doses of Propranolol on Kaposiform Hemangioendothelioma. *Front Pediatr* 2022, 10:760401.

18. Xiu B, Xu Z, Xu Z, Zhang B, Wei L, Ma L: Additive Therapeutic Effects of Topical Sirolimus Following Oral Propranolol Therapy for Kaposiform Hemangioendothelioma. *Clin Cosmet Investig Dermatol* 2025, 18:1261-1267.

19. Ji Y, Yang K, Peng S, Chen S, Xiang B, Xu Z, Li Y, Wang Q, Wang C, Xia C *et al*: Kaposiform haemangioendothelioma: clinical features, complications and risk factors for Kasabach-Merritt phenomenon. *Br J Dermatol* 2018, 179(2):457-463.

20. Ji Y, Yang K, Chen S, Peng S, Lu G, Liu X: Musculoskeletal complication in kaposiform hemangioendothelioma without Kasabach-Merritt phenomenon: clinical

493 characteristics and management. *Cancer Manag Res* 2018, 10:3325-3331.
494 21. Ji Y, Chen S, Xia C, Zhou J, Jiang X, Xu X, Yang K, Zhang X, Kong F, Lu G *et al*:
495 Chronic lymphedema in patients with kaposiform hemangioendothelioma: incidence,
496 clinical features, risk factors and management. *Orphanet J Rare Dis* 2020, 15(1):313.
497 22. Stemmer R: [Stemmer's sign--possibilities and limits of clinical diagnosis of
498 lymphedema]. *Wien Med Wochenschr* 1999, 149(2-4):85-86.
499 23. Zhou J, Lan Y, Qiu T, Zhang Z, Gong X, Zhang X, Yang C, Zhou Z, Zhang Y, Yang M
500 *et al*: Efficacy and safety of high-vs low-dose sirolimus in patients with kaposiform
501 hemangioendothelioma: A randomized clinical trial. *J Am Acad Dermatol* 2025,
502 93(1):124-131.
503 24. Ji Y, Chen S, Xiang B, Li K, Xu Z, Yao W, Lu G, Liu X, Xia C, Wang Q *et al*:
504 Sirolimus for the treatment of progressive kaposiform hemangioendothelioma: A
505 multicenter retrospective study. *Int J Cancer* 2017, 141(4):848-855.
506 25. Zhou J, Li Y, Qiu T, Gong X, Yang K, Zhang X, Zhang Z, Lan Y, Hu F, Peng Q *et al*:
507 Long-term outcomes of sirolimus treatment for kaposiform hemangioendothelioma:
508 Continuing successes and ongoing challenges. *Int J Cancer* 2023, 153(3):600-608.
509 26. Filippi L, Tamburini A, Berti E, Perrone A, Defilippi C, Favre C, Calvani M, Della
510 Bona ML, la Marca G, Donzelli G: Successful Propranolol Treatment of a
511 Kaposiform Hemangioendothelioma Apparently Resistant to Propranolol. *Pediatr*
512 *Blood Cancer* 2016, 63(7):1290-1292.
513 27. Seebauer CT, Graus MS, Huang L, McCann A, Wylie-Sears J, Fontaine F, Karnezis T,
514 Zurakowski D, Staffa SJ, Meunier F *et al*: Non-beta blocker enantiomers of

propranolol and atenolol inhibit vasculogenesis in infantile hemangioma. *J Clin Invest* 2022, 132(3).

28. Zhu T, Wang P, Wang R, Tong G, Sun Y, Yang S, Zhou X, Mou D, Zhong W, Cai Y: Propranolol accelerates adipogenesis and inhibits endothelium differentiation of HemSCs via suppressing HK2 mediated glycolysis. *Pediatr Res* 2026, 99(1):351-361.

29. Hammill AM, Wentzel M, Gupta A, Nelson S, Lucky A, Elluru R, Dasgupta R, Azizkhan RG, Adams DM: Sirolimus for the treatment of complicated vascular anomalies in children. *Pediatr Blood Cancer* 2011, 57(6):1018-1024.

30. Kobayashi S, Kishimoto T, Kamata S, Otsuka M, Miyazaki M, Ishikura H: Rapamycin, a specific inhibitor of the mammalian target of rapamycin, suppresses lymphangiogenesis and lymphatic metastasis. *Cancer Sci* 2007, 98(5):726-733.

31. Rodriguez V, Lee A, Witman PM, Anderson PA: Kasabach-merritt phenomenon: case series and retrospective review of the mayo clinic experience. *J Pediatr Hematol Oncol* 2009, 31(7):522-526.

32. Ji Y, Chen S, Li K, Xiao X, Zheng S, Xu T: The role of β-adrenergic receptor signaling in the proliferation of hemangioma-derived endothelial cells. *Cell Div* 2013, 8(1):1.

33. Wu JK, Hooper ED, Laifer-Narin SL, Simpson LL, Kandel J, Shawber CJ: Initial Experience With Propranolol Treatment of Lymphatic Anomalies: A Case Series. *Pediatrics* 2016, 138(3).

34. Stiles J, Amaya C, Pham R, Rowntree RK, Lacaze M, Mulne A, Bischoff J, Kokta V, Boucheron LE, Mitchell DC *et al*: Propranolol treatment of infantile hemangioma

endothelial cells: A molecular analysis. *Exp Ther Med* 2012, 4(4):594-604.

35. Li P, Guo Z, Gao Y, Pan W: Propranolol represses infantile hemangioma cell growth through the β2-adrenergic receptor in a HIF-1α-dependent manner. *Oncol Rep* 2015, 33(6):3099-3107.

36. Chim H, Armijo BS, Miller E, Gliniak C, Serret MA, Gosain AK: Propranolol induces regression of hemangioma cells through HIF-1α-mediated inhibition of VEGF-A. *Ann Surg* 2012, 256(1):146-156.

37. Ji Y, Chen S, Li K, Xiao X, Zheng S: Propranolol: a novel antihemangioma agent with multiple potential mechanisms of action. *Ann Surg* 2015, 261(2):e52-53.

38. Park M, Jung HL, Shim YJ, Kim HS, Yoon HS, Park SK, Cheuh HW, Lee MJ, Lee JM, Park ES *et al*: Serum cytokine profiles in infants with infantile hemangiomas on oral propranolol treatment: VEGF and bFGF, potential biomarkers predicting clinical outcomes. *Pediatr Res* 2020, 88(5):749-755.

39. Wu S, Wang B, Chen L, Xiong S, Zhuang F, Huang X, Wang M, Huang Z: Clinical efficacy of propranolol in the treatment of hemangioma and changes in serum VEGF, bFGF and MMP-9. *Exp Ther Med* 2015, 10(3):1079-1083.

40. Qiu T, Xiang S, Zhou J, Yang M, Lan Y, Zhang X, Gong X, Zhang Z, Ji Y: Sirolimus for kaposiform hemangioendothelioma: Potential mechanisms of action and resistance. *Int J Cancer* 2025, 156(4):689-699.

Figure Legends

Figure 1: Median platelet count during paired study weeks in the late SIR+PRE period and the early SIR+PRO period. The error bars indicate the interquartile range (Q1–Q3).

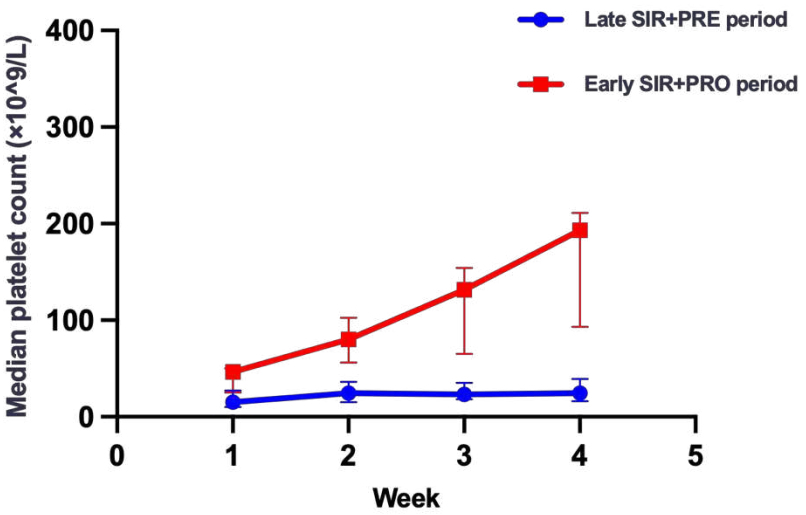

Figure 2: (A) Right thigh KHE before sirolimus combined with prednisolone therapy; (B) after 8 weeks of ineffective treatment, patients were switched to sirolimus combined with propranolol for 4 weeks of treatment; (C) left forearm and elbow joint KHE before sirolimus combined with prednisolone therapy; (D) after 8 weeks of ineffective treatment, patients were switched to sirolimus combined with propranolol for 4 weeks of treatment. (E) Pelvic KHE before sirolimus combined with prednisolone therapy, after 8 weeks of ineffective treatment; (F) the treatment was switched to sirolimus combined with propranolol for 6 months; (G) descending colon and sigmoid colon KHE before sirolimus combined with prednisolone therapy; (H) after 8 weeks of ineffective treatment, the treatment was switched to sirolimus combined with propranolol for 6 months.

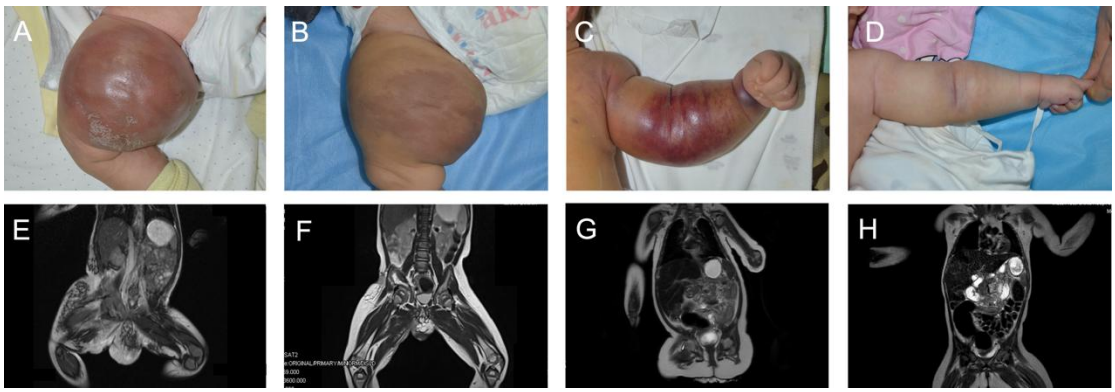

Figure 3: Proposed synergistic mechanisms of propranolol and sirolimus in kaposiform hemangioendothelioma (KHE) complicated by the Kasabach–Merritt phenomenon (KMP).

Propranolol may improve KHE by blocking β-adrenergic signaling, leading to vasoconstriction, altered pericyte-associated contractility, and reduced abnormal vascular perfusion, edema, and lesion congestion. These hemodynamic effects may decrease platelet entry into abnormal vascular channels and reduce intralesional platelet trapping in the Kasabach–Merritt phenomenon (KMP). Propranolol may also suppress upstream proangiogenic signaling, including HIF-1α/VEGF-related pathways, PI3K/AKT, p38/MAPK, and matrix-remodeling molecules such as MMP-2 and MMP-9. Sirolimus directly inhibits mTORC1, a major downstream effector of the PI3K/AKT/mTOR pathway, thereby suppressing lesion growth, angiogenesis, and lymphangiogenesis, partly through inhibition of HIF-1α translation, VEGF-related signaling, and VEGF-C expression. Taken together, these findings suggest that propranolol and sirolimus may provide complementary upstream and downstream inhibition of lesion activity. In the KMP, propranolol may reduce the likelihood of platelet trapping, whereas sirolimus may inhibit platelet aggregation, adhesion, and fibrin formation, thereby potentially promoting more rapid recovery from thrombocytopenia and consumptive coagulopathy. This model remains hypothetical and requires further mechanistic validation in KHE patients.

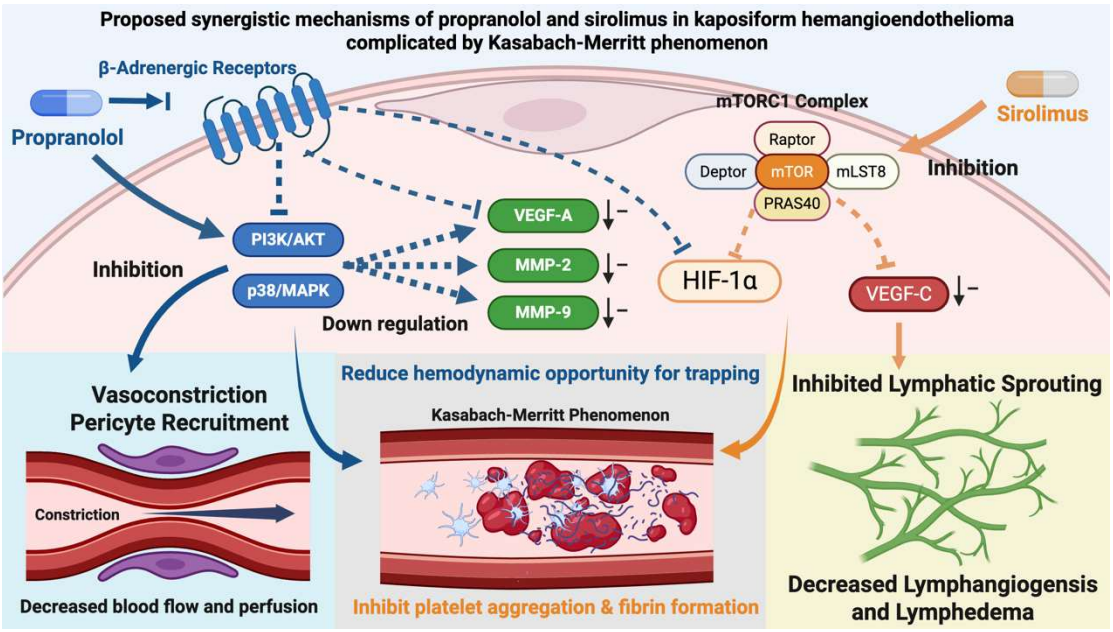
Proposed synergistic mechanisms of propranolol and sirolimus in kaposiform hemangioendothelioma complicated by Kasabach-Merritt phenomenon
β-Adrenergic Receptors
Propranolol
mTORC1 Complex
Raptor
Deptor
mTOR
mLST8
PRAS40
Sirolimus
Inhibition
PI3K/AKT
p38/MAPK
Inhibition
VEGF-A
MMP-2
MMP-9
Down regulation
HIF-1α
VEGF-C
Vasoconstriction
Pericyte Recruitment
Constriction
Decreased blood flow and perfusion
Reduce hemodynamic opportunity for trapping
Kasabach-Merritt Phenomenon
Inhibit platelet aggregation & fibrin formation
Inhibited Lymphatic Sprouting
Decreased Lymphangiogensis
and Lymphedema

593

Table 1 Baseline data and clinical characteristics of KHE* patients with the KMP who did not respond to SIR+PRE

Patients	Cases (n=14)
Sex (n,%)	
Male	8(57.1)
Female	6(42.9)
Age at diagnosis of KHE (months)	
Mean (range)	7.1(0-20.5)
Median	4.8
Age at onset of KMP (months)	
Mean (range)	4.7(0-15.8)
Median	3
Morphology (n,%)	
Superficial	0(0.0)
Mixed	10(71.4)
Deep	4(28.6)
Involvement† (n,%)	
Trunk	12(85.7)
Limbs	3(21.4)
Head and neck	3(21.4)
Perineum	4(28.6)
Intracavity involvement (n,%)	
Yes	10(71.4)
No	4(28.6)
Maximal tumor dimension (n,%)	
≥ 5 cm	12(85.7)
< 5 cm	2(14.3)

*KHE, kaposiform hemangioendothelioma; KMP, Kasabach-Merritt phenomenon; SIR, sirolimus; PRE, prednisolone; PRO, propranolol.

†Some patients had multiple sites of involvement.

Table 2 Analysis of Primary and Secondary Outcomes

	SIR*+PRO (n=14)	95.0% CI§	*P* value‡
Primary outcome			
Cumulative durable platelet response rate at paired week 4 (n,%)			
	10(71.4)	41.9–91.6	0.002
Secondary outcome			
Cumulative durable platelet response rate at paired weeks 1–3 (n,%)			
Week 1	1(7.1)	0.2–33.9	1.000
Week 2	5(35.7)	12.8–64.9	0.063
Week 3	8(57.1)	28.9–82.3	0.008
Fibrinogen stabilization rate at paired week 4 (n,%)			
Week 4	9(64.3)	35.1–87.2	0.031
Cumulative durable platelet response rate at SIR+PRO treatment week 8 (n,%)			
Week 8	13(92.9)	66.1–99.8	N/A
Fibrinogen stabilization rate at SIR+PRO treatment week 8 (n,%)			
Week 8	11(78.6)	49.1–95.3	N/A
Overall lesion response rate (n,%)			
	14(100.0)	76.8–100.0	N/A

*KHE, kaposiform hemangioendothelioma; KMP, Kasabach-Merritt phenomenon; SIR, sirolimus; PRE, prednisolone; PRO, propranolol; CI, confidence interval.

†95% CIs were calculated using the Clopper–Pearson exact method.

‡*P* values were calculated using McNemar's test.

Table 3 Paired Comparisons Before and After Regimen Switching in Patients with KHE[*] Complicated by the KMP

	Late SIR+PRE period	Early SIR+PRO period	Median difference (95% CI)[§]	*P* value[‡]
Platelet count (×10⁹/L), median (Q1, Q3)				
Week 5 vs. week 1 after switching	15.0(10, 27)	46.5(25, 59)	26.0 (16.0, 50.0)	0.001
Week 6 vs. week 2 after switching	24.5(15, 36)	80.0(56, 120)	57.5 (31.0, 102.5)	0.001
Week 7 vs. week 3 after switching	23.0(18, 35)	131.5(65, 197)	103.0 (59.5, 154.0)	0.001
Week 8 vs. week 4 after switching	24.5(16, 39)	193.0(93, 270)	157.0 (109.5, 211.0)	0.001
Fibrinogen (g/L), median (Q1, Q3)				
Week 5 vs. week 1 after switching	1.2(0.8, 1.6)	1.9(1.1, 2.6)	0.72 (0.14, 1.37)	0.035

[*]KHE, kaposiform hemangioendothelioma; KMP, Kasabach-Merritt phenomenon; SIR, sirolimus; PRE, prednisolone; PRO, propranolol; CI, confidence interval.

[§]Median differences and 95% CIs were estimated using the Hodges–Lehmann method.

[‡]*P* values were calculated using the Wilcoxon signed-rank test.