Research Square

Preprints are preliminary reports that have not undergone peer review. They should not be considered conclusive, used to inform clinical practice, or referenced by the media as validated information.

Titanium Mesh Cage Versus Autogenous Strut Graft for Anterior Column Reconstruction in Pyogenic Infectious Spondylitis: Are Outcomes Comparable?

Jin-Hwan Kim
Inje University Ilsan Paik Hospital
Sung Tan Cho
Asan Medical Center
Kyeong-Woo Park
Inje University Ilsan Paik Hospital
Gyu-Heon Lee
Republic of Korea Army Cadet Military School
Dong Seok Kim
andy479797@gmail.com

Inje University Ilsan Paik Hospital

Research Article

Keywords:

Posted Date: October 22nd, 2026

DOI: https://doi.org/10.21203/rs.3.rs-10333269/v1

License: This work is licensed under a Creative Commons Attribution 4.0 International License. Read Full License

Additional Declarations: No competing interests reported.

Abstract

Background

Anterior column reconstruction after corpectomy for pyogenic infectious spondylitis employs titanium mesh cage (TMC) or autogenous strut graft; comparative clinical evidence remains limited. This study compared radiographic and clinical outcomes between these two approaches.

Methods

This retrospective comparative study included 45 patients undergoing anterior corpectomy for pyogenic infectious spondylitis at a single center (2003–2023): 23 received TMC (Ti group) and 22 autogenous strut graft (Auto group). Primary outcomes were radiographic fusion, subsidence, and revision surgery; multivariate logistic regression adjusted for age and infection etiology.

Results

The Ti group was significantly older (69.3 ± 8.3 vs. 56.0 ± 17.0 years, $p = 0.002$) with a lower proportion of primary spondylitis (43% vs. 77%, $p = 0.033$). After multivariate adjustment, no significant differences were observed in fusion (70% vs. 86%; adjusted odds ratio [OR] 0.32, 95% confidence interval [CI] 0.06–1.84, $p = 0.202$), subsidence (87% vs. 68%; adjusted OR 2.24, 95% CI 0.37–13.59, $p = 0.379$), or revision (17% vs. 0%; $p = 0.109$). Complication rates, readmission rates, and hospital stay were comparable. Final erythrocyte sedimentation rate was significantly higher in the Ti group (20.0 ± 15.3 vs. 11.6 ± 10.4 mm/hr, $p = 0.021$); final C-reactive protein did not differ.

Conclusions

TMC and autogenous strut graft showed comparable outcomes for anterior column reconstruction in pyogenic infectious spondylitis after adjustment for confounders. These exploratory findings suggest implant selection may be individualized based on patient characteristics and bone quality, pending confirmation in larger prospective cohorts.

Trial registration

Not applicable.

BACKGROUND

Pyogenic infectious spondylitis is a serious spinal infection with rising incidence, attributable to increasing immunocompromising conditions, growing use of invasive spinal procedures, and an aging global population [1, 2]. It predominantly affects the anterior vertebral column, causing progressive vertebral destruction, spinal instability, and neurological compromise [2, 3]. When conservative management fails or significant structural collapse is present, surgical intervention is required to eradicate infection, restore anterior column support, achieve spinal fusion, and prevent deformity progression [1, 4].

Anterior radical debridement is the cornerstone of surgical treatment, and anterior column reconstruction after corpectomy is essential to restore biomechanical stability [3, 5]. Autogenous structural bone graft—from the iliac crest or fibula—has historically been the gold standard for reconstruction, given its osteoinductive and osteoconductive properties [6, 7], but harvest carries non-negligible donor site morbidity (wound complications, chronic donor site pain, hematoma, sensory nerve injury) [8], and anterior strut grafts in the infected field risk resorption and collapse when unsupported by posterior instrumentation [7]. Titanium mesh cages (TMC) have emerged as an alternative, offering immediate structural support, avoidance of donor site morbidity, and the capacity for packing with local or allogeneic bone graft [1, 6]. Their use in an infected field was historically controversial—titanium provides excellent mechanical strength but is biologically inert compared with autogenous bone, with a further theoretical concern of bacterial adhesion and biofilm formation—but multiple series, employing anterior, combined anterior-posterior, and posterior-only approaches, have subsequently demonstrated that TMC placement within the infected operative field does not impede infection eradication [1, 3, 9, 10, 11, 12].

Despite growing TMC adoption, adequately powered comparative data specifically isolating TMC from other cage designs remain limited. Pee et al. [13] retrospectively compared autologous iliac bone strut (n = 23) with cage reconstruction (n = 37) in 60 patients with pyogenic spondylodiscitis, but only 5 of the 37 cage-group patients received a titanium mesh cage, the remainder receiving solid titanium or polyetheretherketone (PEEK) cages—precluding a clean TMC-specific comparison. Pee et al. [13] themselves identified the sole prior study specifically evaluating TMC against strut graft—that of Hee et al. [14]—as limited to five TMC patients and confounded by inconsistent use of posterior instrumentation between groups. Cha et al. [15] reported comparable clinical and radiographic outcomes in 25 patients comparing autogenous bone graft versus a metal cage with allogeneic bone graft, though their cage arm used allogeneic rather than autogenous bone and the sample size was small. In the distinct pathological context of tuberculosis spondylitis, TMC and bone graft reconstruction have similarly shown comparable outcomes [16, 17]. A recent meta-analysis pooling 32 heterogeneous single-arm series (1088 patients) found no significant difference in fusion rate, screw loosening, or reoperation across titanium, PEEK, allograft, and autograft instrumentation in spondylodiscitis broadly [18], but compared proportions across non-matched series rather than performing a direct within-cohort comparison, without isolating titanium mesh cage architecture or restricting analysis to pyogenic etiology. Comparative data for PEEK cages in pyogenic spondylodiscitis are similarly limited to comparisons against other cage types or allogeneic graft rather than autogenous bone [19, 20]. No adequately powered within-cohort comparative

study using a single, consistent TMC design against autogenous strut graft has been reported for fusion rate, subsidence, and revision surgery. Given the fundamental differences in material properties between titanium alloy and biological autograft—particularly with respect to osseointegration, mechanical load transfer, and endplate interaction—a direct clinical comparison in this specific disease context remains warranted [21, 22].

Therefore, this study aimed to compare clinical and radiographic outcomes of TMC versus autogenous strut graft for anterior column reconstruction following corpectomy in patients with pyogenic infectious spondylitis, with adjustment for potential confounders including patient age and infection etiology. The primary outcomes of interest were radiographic fusion, cage subsidence, and revision surgery rate.

MATERIALS AND METHODS

Study Design and Patient Selection

This retrospective comparative study was conducted at a single tertiary referral center in accordance with the Declaration of Helsinki. Institutional Review Board (IRB) approval was obtained prior to data collection, and the requirement for informed consent was waived given the retrospective nature of the study. Patients who underwent anterior corpectomy and anterior column reconstruction for pyogenic infectious spondylitis between 2003 and 2023 were identified from the institutional surgical database. Inclusion criteria were: (1) diagnosis of pyogenic infectious spondylitis confirmed by clinical, laboratory, and imaging findings; (2) surgical treatment consisting of anterior radical debridement, corpectomy, and anterior column reconstruction with either a titanium mesh cage or an autogenous strut graft, combined with posterior pedicle screw fixation; and (3) minimum follow-up of 12 months. Exclusion criteria were: (1) tuberculous or fungal spondylitis; (2) spinal tumor or metastatic disease; and (3) incomplete clinical or radiographic data. All patients identified from the institutional surgical database as having undergone anterior corpectomy and anterior column reconstruction for pyogenic infectious spondylitis during the study period met these inclusion criteria and none met an exclusion criterion; the resulting 45 patients therefore represented the entire eligible cohort, with no exclusions.

Surgical Technique

All procedures were performed under general anesthesia by a single spine surgeon with standardized technique. Following anterior radical debridement of the infected vertebral segment, anterior column reconstruction was performed using either a titanium mesh cage (Ti group) or an autogenous tricortical iliac crest strut graft (Auto group). Reconstruction material selection was not randomized and reflected evolving institutional practice over the study period: autogenous iliac crest strut graft was the predominant reconstruction material in the early phase of the series (2003–2012), while titanium mesh cage became predominant in the latter phase (2014–2023), driven by accumulating evidence supporting TMC safety in the infected field and growing recognition of the morbidity associated with iliac crest

harvest in an aging surgical population. In both groups, the mesh cage or strut graft was packed with a mixture of local autogenous bone and allogeneic bone graft. Posterior pedicle screw fixation and posterolateral fusion were subsequently performed in the same operative session in all patients. Postoperative intravenous antibiotics were administered based on intraoperative culture results and infectious disease consultation, followed by oral antibiotics for a minimum of 6 weeks.

Outcome Measures

The primary outcomes were: (1) radiographic fusion; (2) cage or graft subsidence; and (3) revision surgery during the entire follow-up period. Radiographic fusion was graded as confirmed (grade 2), suspected (grade 1), or absent (grade 0) on lateral plain radiographs, and confirmed fusion (grade 2) was used as the binary outcome for analysis; this three-tier scheme was conceptually consistent with, though independently defined from, prior numbered radiographic grading systems developed for serial plain-film fusion assessment in similar populations [23]. Fusion status was determined at the radiograph closest to 2 years postoperatively that was available for each patient; because the minimum follow-up required for study inclusion was 12 months, a subset of patients with shorter overall follow-up had fusion status determined at their final available radiograph rather than strictly at 2 years (patient counts and a corresponding sensitivity analysis are reported in Results). Subsidence was defined as a ≥ 2 mm reduction in anterior column height or radiographic evidence of implant migration on serial lateral plain radiographs, consistent with thresholds used in prior titanium mesh cage subsidence studies [21, 24]; unlike fusion, subsidence was treated as an event outcome captured at the time of first radiographic detection during follow-up (or, if absent, confirmed not to have occurred through the last available radiograph) rather than at a fixed postoperative time point, consistent with its typically early clinical course after construct loading. Revision surgery was defined as any unplanned return to the operating room for implant-related or infection-related reasons through the final follow-up visit.

Secondary outcomes included: postoperative complication rate, hospital readmission, length of hospital stay, and serial inflammatory markers (erythrocyte sedimentation rate [ESR] and C-reactive protein [CRP]) at 1 month and at final follow-up.

Statistical Analysis

Continuous variables were presented as mean ± standard deviation and compared between groups using the Mann-Whitney U test. Categorical variables were presented as frequencies and percentages and compared using Fisher's exact test. A *p*-value of less than 0.05 was considered statistically significant.

To adjust for potential confounding by patient age and infection etiology—the two variables that differed significantly between groups at baseline—multivariate logistic regression was performed for each binary primary outcome, with implant type (Ti vs. Auto), age, and infection etiology (primary vs. post-operative) entered as covariates. Propensity score matching was considered but yielded insufficient matched pairs (n = 8) due to substantial baseline imbalance between groups; multivariate logistic regression was

therefore employed to retain the full analytic sample of 45 patients. For revision surgery, complete separation (zero events in the Auto group) precluded standard logistic regression; the Fisher's exact *p*-value is reported for this outcome. A sensitivity analysis incorporating additional covariates (sex, hypertension, and diabetes mellitus) was performed to assess the robustness of findings. Because reconstruction material selection evolved over the 20-year study period (see Surgical Technique), an additional sensitivity analysis incorporating calendar year of surgery as a covariate was performed to assess confounding by treatment era. Because fusion status was not determined at a uniform postoperative time point across all patients (see Outcome Measures), a further sensitivity analysis restricted the fusion comparison to the subset of patients with radiographic assessment at or beyond 24 months. Multivariate logistic regression was also performed for the secondary outcome of any complication; readmission was modeled but the resulting effect estimate was materially unstable owing to quasi-complete separation (odds ratio 89.19, 95% confidence interval 0.35–23025.47); only the univariate Fisher's exact result is reported for this outcome. A prospective sample-size projection was calculated for the two radiographic primary outcomes using the two-proportion z-test (two-sided alpha = 0.05, target power 80%): based on the observed proportions, approximately 185 patients (93 per group) would be required to detect the observed fusion difference (70% vs. 86%) and approximately 149 patients (74 per group) for the observed subsidence difference (87% vs. 68%) at conventional significance. These findings are accordingly interpreted as exploratory and hypothesis-generating. All statistical analyses were performed using Python (version 3.14; statsmodels 0.14.6, scipy 1.17.1). An artificial intelligence language model (Claude Sonnet 4.6; Anthropic, San Francisco, CA) was used for assistance in manuscript preparation; all data collection, interpretation, scientific content, and conclusions are the sole responsibility of the authors.

RESULTS

Patient Characteristics

A total of 45 patients met the inclusion criteria and were included in the final analysis: 23 in the titanium mesh cage (Ti) group and 22 in the autogenous strut graft (Auto) group. The mean overall follow-up duration was 64.0 months. Baseline demographic and clinical characteristics are summarized in Table 1. The Ti group was significantly older than the Auto group (69.3 ± 8.3 vs. 56.0 ± 17.0 years, $p = 0.002$), and a significantly higher proportion of patients in the Auto group presented with primary infectious spondylitis compared with the Ti group (77% vs. 43%, $p = 0.033$). No significant differences were observed between the groups in sex, comorbidities, corpectomy level, preoperative symptoms, or preoperative inflammatory markers (Table 1).

Table 1
Baseline characteristics of patients undergoing anterior column reconstruction with titanium mesh cage versus autogenous strut graft for pyogenic infectious spondylitis.

Variable	Ti mesh cage (n = 23)	Autogenous strut (n = 22)	*p*-value
Demographics			
Age (years)	69.3 ± 8.3	56.0 ± 17.0	0.002
Male sex	12 (52%)	14 (64%)	0.550
Follow-up duration (months)†	58.7 ± 42.5	69.5 ± 56.7	0.847
Comorbidities			
Hypertension	14 (61%)	10 (45%)	0.376
Diabetes mellitus	10 (43%)	7 (32%)	0.542
Cerebrovascular disease	4 (17%)	2 (9%)	0.665
Chronic kidney disease	3 (13%)	0 (0%)	0.233
Operative profile			
Primary infectious spondylitis	10 (43%)	17 (77%)	0.033
Thoracic corpectomy‡	2 (9%)	0 (0%)	0.489
Preoperative fever	11 (48%)	11 (50%)	1.000
Preoperative radicular pain	14 (61%)	12 (55%)	0.767
Preoperative inflammatory markers			
ESR (mm/hr)	49.7 ± 24.0	51.0 ± 20.3	0.812
CRP (mg/dL)	4.7 ± 5.1	7.8 ± 10.2	0.481

Data presented as mean ± standard deviation or n (%).

Continuous variables compared using the Mann-Whitney U test; categorical variables compared using Fisher's exact test.

†Given the right-skewed distribution of follow-up duration, median (IQR) values are also reported: Ti 50.0 (24.7–81.0) months; Auto 51.8 (24.7–110.9) months.

‡Thoracolumbar junction levels (e.g., T11–L1, T12–L1) were classified as lumbar for this row; only single-level thoracic corpectomies (T7–8, T9–10) were classified as thoracic.

Abbreviations: Ti, titanium; ESR, erythrocyte sedimentation rate; CRP, C-reactive protein.

Primary Outcomes

Radiographic fusion, cage/graft subsidence, and revision surgery during follow-up are presented in Table 2. Representative postoperative radiographs from each group are shown in Fig. 1. The radiographic fusion rate was 70% in the Ti group and 86% in the Auto group; this difference did not reach statistical significance (adjusted OR 0.32, 95% CI 0.06–1.84, $p = 0.202$ on multivariate analysis). Fusion status was determined at or beyond 24 months postoperatively in 27 of 45 patients (60%); the remaining 18 patients (Ti 10, Auto 8), whose overall follow-up met the 12-month minimum but did not reach 24 months, had fusion status determined at their final available radiograph (range 12.0–23.0 months). Subsidence was more frequent in the Ti group (87% vs. 68%), though this difference similarly did not reach statistical significance (adjusted OR 2.24, 95% CI 0.37–13.59, $p = 0.379$ on multivariate analysis); subsidence, captured as an event outcome at the time of radiographic detection (see Methods), was identified at a median of 24 months postoperatively among affected patients (range 12–55 months). Revision surgery was performed in four patients (17%) in the Ti group and in none in the Auto group; owing to complete separation, the Fisher's exact *p*-value was 0.109. The causes of revision in the Ti group were rod breakage with screw and rod revision (n = 1), posterior re-fixation for construct failure (n = 1), spinopelvic fixation for sacroiliac instability (n = 1), and posterior instrumentation extension for progressive deformity (n = 1).

Table 2
Clinical and radiographic outcomes of patients undergoing anterior column reconstruction with titanium mesh cage versus autogenous strut graft for pyogenic infectious spondylitis.

Outcome	Ti mesh cage (n = 23)	Autogenous strut (n = 22)	*p*-value
Primary outcomes			
Radiographic fusion at 2 years†	16 (70%)	19 (86%)	0.284
Cage/graft subsidence at 2 years†	20 (87%)	15 (68%)	0.165
Revision surgery during follow-up	4 (17%)	0 (0%)	0.109
Secondary outcomes			
Any complication	6 (26%)	3 (14%)	0.459
Readmission	4 (17%)	1 (5%)	0.346
Length of hospital stay (days)‡	40.6 ± 50.3	36.4 ± 19.2	0.290
Inflammatory markers at follow-up			
1-month ESR (mm/hr)	34.6 ± 16.3	30.3 ± 20.5	0.275
1-month CRP (mg/dL)	1.6 ± 3.0	1.4 ± 2.2	0.955
Final ESR (mm/hr)	20.0 ± 15.3	11.6 ± 10.4	0.021
Final CRP (mg/dL)	0.3 ± 0.3	0.2 ± 0.3	0.477

Data presented as mean ± standard deviation or n (%).

Continuous variables compared using the Mann-Whitney U test; categorical variables compared using Fisher's exact test.

†Fusion was assessed at the radiograph closest to 2 years postoperatively available for each patient (18/45 patients assessed < 24 months per the 12-month minimum follow-up criterion; see Results). Subsidence was captured as an event outcome at the time of first radiographic detection during follow-up and defined as ≥ 2 mm reduction in anterior column height or evidence of implant migration on lateral plain radiograph.

Revision surgery defined as any unplanned return to the operating room through the final follow-up visit.

‡Given the right-skewed distribution of length of stay, median (IQR) values are also reported: Ti 28.0 (18.5–38.0) days; Auto 34.0 (19.2–44.8) days.

Abbreviations: Ti, titanium; ESR, erythrocyte sedimentation rate; CRP, C-reactive protein.

Secondary Outcomes

Secondary outcomes are detailed in Table 2. Complication rates, readmission rates, and length of hospital stay did not differ significantly between groups. At the 1-month postoperative assessment, no significant intergroup difference was observed in ESR or CRP. At final follow-up, the Ti group demonstrated a significantly higher ESR compared with the Auto group (20.0 ± 15.3 vs. 11.6 ± 10.4 mm/hr, $p = 0.021$), whereas final CRP did not differ significantly between groups ($p = 0.477$). This ESR difference persisted after excluding the four Ti-group patients who underwent revision surgery (19.2 ± 14.2 vs. 11.6 ± 10.4 mm/hr, $p = 0.030$), indicating that it was not solely attributable to the revision subgroup.

Multivariate Analysis

On multivariate logistic regression adjusting for patient age and infection etiology, no statistically significant association between implant type and any evaluated outcome was identified; full regression results are detailed in Table 3. Results were consistent across sensitivity analyses additionally incorporating sex, hypertension, and diabetes mellitus as covariates (data not shown). Because implant selection was associated with calendar year of surgery (Ti group: 2010–2023, mean 2018.1; Auto group: 2003–2015, mean 2009.2; 5-year period of overlap, 2010–2015), a sensitivity analysis incorporating calendar year as an additional covariate was performed; the association between implant type and fusion or subsidence remained non-significant (fusion: adjusted OR 0.23, $p = 0.276$; subsidence: adjusted OR 8.92, $p = 0.199$), although these estimates were imprecise given collinearity between implant type and treatment era. A further sensitivity analysis restricted to the 27 patients with fusion status assessed at or beyond 24 months (Ti n = 13, Auto n = 14) showed a similar direction of effect (fusion 69% vs. 93%; adjusted OR 0.08, 95% CI 0.00–2.65, $p = 0.160$), consistent with, though less precise than, the primary analysis of the full cohort.

Table 3
Multivariate logistic regression analysis of clinical outcomes adjusted for age and infection etiology.

Outcome	Adjusted OR (Ti vs Auto)*	95% CI	*p*-value
Primary outcomes			
Radiographic fusion	0.32	0.06–1.84	0.202
Cage/graft subsidence	2.24	0.37–13.59	0.379
Revision surgery†	—	—	0.109
Secondary outcomes			
Any complication	2.09	0.30–14.68	0.460

OR, odds ratio; CI, confidence interval; Ti, titanium; Auto, autogenous.

*OR > 1 indicates higher odds in the Ti mesh cage group relative to the autogenous strut group.

†Complete separation precluded logistic regression (0 events in autogenous strut group); *p*-value derived from Fisher's exact test.

Covariates in model: implant type, patient age, infection etiology (primary vs. post-operative).

Readmission was modeled but is not shown owing to quasi-complete separation producing a materially unstable estimate (odds ratio 89.19, 95% CI 0.35–23025.47); only the univariate Fisher's exact result (Table 2) is reported for this outcome.

A sensitivity analysis additionally adjusting for calendar year of surgery yielded consistent non-significant findings for fusion (adjusted OR 0.23, $p = 0.276$) and subsidence (adjusted OR 8.92, $p = 0.199$); see Discussion for interpretation given collinearity between implant type and treatment era.

DISCUSSION

This study found comparable clinical and radiographic outcomes between titanium mesh cage and autogenous strut graft for anterior column reconstruction after corpectomy for pyogenic infectious spondylitis, with no statistically significant differences in fusion, subsidence, revision, or complication rates after adjustment for age and infection etiology. The Ti group showed numerically lower fusion (70% vs. 86%), higher subsidence (87% vs. 68%), and higher revision (17% vs. 0%), but none of these differences reached significance after multivariate adjustment—suggesting the disparities are substantially attributable to the Ti group's older age and higher proportion of post-operative infection rather than to implant material per se.

The finding of comparable outcomes aligns with prior comparative literature. Cha et al. [15] reported similar outcomes with autogenous graft versus metal cage with allogeneic bone in 25 patients, and in the tuberculosis literature, Zhang et al. [16] and Zhong et al. [17] similarly found no significant TMC advantage over bone graft. In contrast, Pee et al. [13] reported higher subsidence in their strut group than their pooled cage group; however, only 5 of 37 cage-group patients received a true TMC, the majority

receiving solid titanium or PEEK cages with a wider endplate contact area—a difference that plausibly explains their lower cage-group subsidence, consistent with the known relationship between contact area and subsidence risk [22]. Our subsidence rates (87% Ti, 68% Auto), while numerically high, are consistent with Schomacher et al.'s [19] 70.3% cage subsidence in a directly comparable pyogenic series; Zheng et al. [20] reported a lower rate (12.8%) via a less invasive posterior approach with a more restrictive definition, plausibly explaining the discrepancy. This study extends these observations to autogenous—rather than allogeneic—bone as the comparator, with a longer mean follow-up of 64 months. Consistent with the established safety of TMC in the infected field [1, 2, 3, 9], no implant-associated persistent infection requiring cage removal occurred in the Ti group.

Selection of TMC as the index implant, rather than solid metallic or polymer alternatives, reflects biomaterial considerations. Solid titanium cages are mechanically robust but largely non-porous, restricting bone ingrowth, and their high elastic modulus relative to cancellous bone promotes stress shielding and subsidence, particularly in osteoporotic hosts [22]. Solid carbon-fiber-reinforced PEEK (CFRP) cages offer radiolucency and a modulus closer to cortical bone but lack established evidence of biological incorporation in the infected field [4]. Expandable titanium cages permit intraoperative height adjustment with favorable outcomes in mixed-etiology vertebral osteomyelitis [25], but comparative data against autogenous graft in pyogenic spondylitis are similarly lacking. Titanium mesh cages, by contrast, have a fenestrated architecture permitting vascularized bone ingrowth through the apertures, reduced effective stiffness relative to solid constructs, and demonstrated biocompatibility in the infected field across multiple series [1, 3, 9, 12]—properties intermediate between autogenous bone and solid metallic implants, eliminating donor site morbidity while still facilitating biological incorporation. The institutional transition from strut graft to TMC accordingly reflects recognition of this intermediate profile, not simply avoidance of iliac crest harvest morbidity.

Titanium (Ti-6Al-4V) is biologically inert relative to autogenous bone and lacks intrinsic osteoinductive potential, relying entirely on the packed graft material and host biology for incorporation [6]; its higher elastic modulus relative to cancellous bone concentrates stress at the cage–endplate interface, predisposing to subsidence and secondary construct failure, particularly in elderly or osteoporotic patients [22]. Ji et al. [21] identified lower bone mineral density (Hounsfield units) as an independent risk factor for TMC subsidence; given the Ti group's older age (69.3 vs. 56.0 years), reduced bone density may have independently contributed to its higher subsidence rate. A metallic surface may also serve as a substrate for bacterial colonization if residual infection persists, though adequate debridement and targeted antibiotics generally permit eradication regardless [1]. No implant-associated persistent infection requiring removal occurred here, supporting TMC's clinical safety after radical debridement, though titanium should still be regarded as a mechanically reliable but biologically passive scaffold rather than a biological equivalent to autogenous bone. The Ti group's higher final ESR, despite comparable CRP, may reflect a low-grade foreign body inflammatory response compounded by older age and comorbidity burden [1]. Autogenous strut graft, by contrast, provides osteoconductive and osteoinductive biology with progressive remodeling into the host endplate [7], and its modulus more closely approximates native bone—plausibly explaining the numerically higher fusion and lower

subsidence in the Auto group, though neither difference was statistically significant. The choice between these materials therefore extends beyond infection control alone, reflecting a balance of mechanical reliability, biological incorporation, host bone quality, and donor site morbidity.

Given the wide confidence intervals and exploratory nature of these findings, the following implant-selection considerations are hypothesis-generating rather than definitive. Autogenous strut graft may be preferentially considered in younger patients with primary infectious spondylitis and adequate donor site availability, given its osteoinductive and remodeling advantages [7]; TMC represents a comparable alternative in older patients or those with post-operative infection, in whom bone quality may be compromised and harvest morbidity greater [8]. The donor-site morbidity of iliac crest harvest is a theoretical TMC advantage, though its magnitude in this specific context warrants emphasis beyond the generic complication list typically cited: unlike the small-volume cancellous chip harvest used to supplement posterolateral fusion, a tricortical strut adequate for corpectomy anterior-column reconstruction requires a substantially larger harvest, and series restricted to this large-defect range report significantly greater donor-site pain, inferior cosmetic outcome, and defect-specific complications (skin tenting over the residual defect, bursitis, skin necrosis) than are apparent in morbidity series that pool harvests of all volumes together [8, 26]. Clinically, this morbidity is less a matter of chronic low back pain—the complication most often emphasized alongside sensory nerve injury and hematoma—than of localized pain and a palpable structural defect at the donor ilium itself, at times symptomatic with direct external pressure (e.g., a belt). None of the three Auto-group complications in this series were harvest-related, and the cohort is not powered to independently confirm this benefit. The Ti group's 17% revision rate, though not statistically significant, warrants continued vigilance and compares unfavorably with contemporary pyogenic spondylodiscitis series [4, 27, 28]. All four Ti-group revisions had documented subsidence—preceding revision in two cases, detected concurrently in the other two—consistent with, though not conclusively establishing, a mechanistic link between anterior subsidence and the posterior construct failures (rod breakage, screw loosening, metal failure) necessitating revision [22, 24]; since both groups received identical posterior fixation, this implicates load transfer from anterior collapse rather than a difference in posterior instrumentation.

Several limitations warrant consideration. First, the retrospective, non-randomized design introduces selection bias: the Ti group's older age and higher post-operative-infection prevalence reflect surgeon preference rather than systematic allocation, and residual confounding cannot be excluded despite multivariate adjustment. Implant selection was also substantially associated with calendar year over this 20-year series—strut graft predominant through 2012, TMC predominant from 2014 onward, with case dates actually overlapping from 2010–2015 (Ti: 2010–2023; Auto: 2003–2015). A sensitivity analysis adjusting for calendar year did not materially change the non-significant fusion/subsidence findings, but implant type and treatment era remain substantially collinear, and era-related factors (antibiotic protocols, imaging, perioperative care) cannot be fully disentangled from the implant effect. Second, the sample size of 45 substantially limits power, reflected in the wide confidence intervals for fusion (0.06–1.84) and subsidence (0.37–13.59); approximately 185 and 149 patients, respectively, would be needed at conventional 80% power, and findings should be interpreted as exploratory rather than as evidence of

equivalence. Third, fusion status was not assessed at a uniform postoperative time point: while the minimum follow-up for study inclusion was 12 months, fusion was targeted at 2 years, and 18 of 45 patients (Ti 10, Auto 8) had fusion status determined at their final available radiograph before 24 months (range 12.0–23.0 months); a sensitivity analysis restricted to the 27 patients assessed at or beyond 24 months showed a consistent direction of effect (adjusted OR 0.08, 95% CI 0.00–2.65) but with wider, less precise confidence intervals given the smaller restricted subsample, and cannot exclude the possibility that fusion was under-ascertained in patients imaged earlier than 2 years. Fourth, this was a single-center, single-surgeon study, which may limit generalizability. Fifth, bone mineral density was not systematically measured, precluding adjustment for this subsidence confounder. Sixth, patient-reported functional outcomes were not assessed. Seventh, formal neurological grading (Frankel/ASIA) was not systematically recorded, precluding assessment of neurological recovery as a discrete outcome. Despite these limitations, this study represents one of the largest single-center comparative series of TMC versus autogenous strut graft in pyogenic infectious spondylitis, with mean follow-up exceeding 5 years, and provides clinically relevant data to inform implant selection. Prospective studies with systematic bone mineral density assessment, standardized functional outcomes, and larger cohorts are warranted to definitively establish the relative merits of these strategies.

CONCLUSION

Titanium mesh cage and autogenous strut graft demonstrated comparable clinical and radiographic outcomes for anterior column reconstruction following corpectomy in pyogenic infectious spondylitis, with no statistically significant differences in fusion rate, subsidence, or revision surgery after adjustment for patient age and infection etiology. Although autogenous strut graft offers inherent biological advantages through osteoinductivity and physiological load transfer, titanium mesh cage represents a clinically comparable alternative that avoids donor site morbidity in appropriately selected patients. These exploratory findings suggest that implant selection may be individualized based on patient age, bone quality, infection etiology, and donor site availability, pending confirmation in adequately powered prospective studies.

Abbreviations

TMC
titanium mesh cage
PEEK
polyetheretherketone
CFRP
carbon-fiber-reinforced PEEK
ESR
erythrocyte sedimentation rate
CRP
C-reactive protein

OR
odds ratio
CI
confidence interval
IRB
Institutional Review Board

Declarations

Ethics approval and consent to participate: This study was conducted in accordance with the Declaration of Helsinki and was approved by the Institutional Review Board of Inje University Ilsan Paik Hospital (IRB No. 2026-02-010). The requirement for individual informed consent was waived by the Institutional Review Board given the retrospective nature of the study.

Consent for publication: Not applicable.

Availability of data and materials: The data that support the findings of this study are available from the corresponding author upon reasonable request.

Competing interests: The authors declare no competing interests.

Funding: This research received no specific grant from any funding agency in the public, commercial, or not-for-profit sectors.

Authors' contributions: DSK: Conceptualization, data curation, formal analysis, writing – original draft. STC: Writing – review and editing. KWP: Data curation, writing – review and editing. GHL: Writing – review and editing. JHK: Conceptualization, supervision, writing – review and editing. All authors read and approved the final manuscript.

Acknowledgements: Not applicable.

Use of artificial intelligence: An artificial intelligence language model (Claude Sonnet 4.6; Anthropic, San Francisco, CA) was used for assistance in manuscript preparation. All data collection, interpretation, scientific content, and conclusions are the sole responsibility of the authors.

References

1. Korovessis P, Repantis T, Iliopoulos P, Hadjipavlou A. Beneficial influence of titanium mesh cage on infection healing and spinal reconstruction in hematogenous septic spondylitis: a retrospective analysis of surgical outcome of twenty-five consecutive cases and review of literature. Spine (Phila Pa 1976). 2008;33(23):E759–E767. doi:10.1097/BRS.0b013e318187875e
2. Korovessis P, Vardakastanis K, Fennema P, Syrimbeis V. Mesh cage for treatment of hematogenous spondylitis and spondylodiskitis. How safe and successful is its use in acute and chronic

complicated cases? A systematic review of literature over a decade. Eur J Orthop Surg Traumatol. 2016;26(5):481–490. doi:10.1007/s00590-016-1803-x

3. Ruf M, Stoltze D, Merk HR, Ames M, Harms J. Treatment of vertebral osteomyelitis by radical debridement and stabilization using titanium mesh cages. Spine (Phila Pa 1976). 2007;32(9):E275–E280. doi:10.1097/01.brs.0000261034.83395.7f
4. Burkhardt BW, Bullinger Y, Mueller SJ, Oertel JM. The Surgical Treatment of Pyogenic Spondylodiscitis using Carbon-Fiber-Reinforced Polyether Ether Ketone Implants: Personal Experience of a Series of 81 Consecutive Patients. World Neurosurg. 2021;150:e728–e737. doi:10.1016/j.wneu.2021.04.064
5. Si M, Yang ZP, Li ZF, Yang Q, Li JM. Anterior versus posterior fixation for the treatment of lumbar pyogenic vertebral osteomyelitis. Orthopedics. 2013;36(6):831–836. doi:10.3928/01477447-20130523-33
6. Fayazi AH, Ludwig SC, Dabbah M, Bryan Butler R, Gelb DE. Preliminary results of staged anterior debridement and reconstruction using titanium mesh cages in the treatment of thoracolumbar vertebral osteomyelitis. Spine J. 2004;4(4):388–395. doi:10.1016/j.spinee.2004.01.004
7. Ha KY, Shin JH, Kim KW, Na KH. The fate of anterior autogenous bone graft after anterior radical surgery with or without posterior instrumentation in the treatment of pyogenic lumbar spondylodiscitis. Spine (Phila Pa 1976). 2007;32(17):1840–1845. doi:10.1097/BRS.0b013e318108b804
8. Arrington ED, Smith WJ, Chambers HG, Bucknell AL, Davino NA. Complications of iliac crest bone graft harvesting. Clin Orthop Relat Res. 1996;(329):300–309. doi:10.1097/00003086-199608000-00037
9. Korovessis P, Petsinis G, Koureas G, Iliopoulos P, Zacharatos S. Anterior surgery with insertion of titanium mesh cage and posterior instrumented fusion performed sequentially on the same day under one anesthesia for septic spondylitis of thoracolumbar spine: is the use of titanium mesh cages safe? Spine (Phila Pa 1976). 2006;31(9):1014–1019. doi:10.1097/01.brs.0000215049.08622.9d
10. Zhang HQ, Wang YX, Wu JH, Chen J. Debridement and Interbody Graft Using Titanium Mesh Cage, Posterior Monosegmental Instrumentation, and Fusion in the Surgical Treatment of Monosegmental Lumbar or Lumbosacral Pyogenic Vertebral Osteomyelitis via a Posterior-Only Approach. World Neurosurg. 2020;134:e576–e583. doi:10.1016/j.wneu.2019.11.072
11. Lee JC, Kim YI, Shin BJ. Safety and efficacy of pedicle screws and titanium mesh cage in the treatments of tuberculous spondylitis of the thoracolumbar spine. Asian Spine J. 2008;2(2):64–73. doi:10.4184/asj.2008.2.2.64
12. Sundararaj GD, Amritanand R, Venkatesh K, Arockiaraj J. The use of titanium mesh cages in the reconstruction of anterior column defects in active spinal infections: can we rest the crest? Asian Spine J. 2011;5(3):155–161. doi:10.4184/asj.2011.5.3.155

13. Pee YH, Park JD, Choi YG, Lee SH. Anterior debridement and fusion followed by posterior pedicle screw fixation in pyogenic spondylodiscitis: autologous iliac bone strut versus cage. J Neurosurg Spine. 2008;8(5):405–412. doi:10.3171/SPI/2008/8/5/405
14. Hee HT, Majd ME, Holt RT, Pienkowski D. Better treatment of vertebral osteomyelitis using posterior stabilization and titanium mesh cages. J Spinal Disord Tech. 2002;15(2):149–156. doi:10.1097/00024720-200204000-00010
15. Cha JR, Hwang IY, Kwon SH, Chung HY. Autogenous Bone Grafts versus Metal Cage with Allogenic Bone Grafts for Post-Corpectomy Anterior Column Reconstruction in Patients with Infectious Spondylitis. J Korean Neurosurg Soc. 2020;63(6):756–764. doi:10.3340/jkns.2019.0127
16. Zhang HQ, Li M, Wang YX, Tang MX, Guo CF, Liu SH, et al. Minimum 5-Year Follow-Up Outcomes for Comparison Between Titanium Mesh Cage and Allogeneic Bone Graft to Reconstruct Anterior Column Through Posterior Approach for the Surgical Treatment of Thoracolumbar Spinal Tuberculosis with Kyphosis. World Neurosurg. 2019;126:e190–e198. doi:10.1016/j.wneu.2019.03.139
17. Zhong D, Lin L, Liu Y, Ke ZY, Wang Y. Analysis of Nanohydroxyapatite/Polyamide-66 Cage, Titanium Mesh, and Iliac Crest in Spinal Reconstruction of the Patients with Thoracic and Lumbar Tuberculosis. Neurol India. 2022;70(5):1937–1943. doi:10.4103/0028-3886.360908
18. Maddy KS, Tigre JY, Lu VM, Costello MC, Errante EL, Levi AD, et al. Influence of instrumentation type on outcomes after surgical management of spondylodiscitis: a systematic review and meta-analysis. Eur Spine J. 2024;33(8):3175–3190. doi:10.1007/s00586-023-08065-w
19. Schomacher M, Finger T, Koeppen D, Süss O, Vajkoczy P, Kroppenstedt S, et al. Application of titanium and polyetheretherketone cages in the treatment of pyogenic spondylodiscitis. Clin Neurol Neurosurg. 2014;127:65–70. doi:10.1016/j.clineuro.2014.09.027
20. Zheng HL, Li B, Song SK, Chen PB, Zheng XF, Jiang LS, et al. Safety and Efficacy of Polyetheretherketone (PEEK) Cages and Cadaveric Allografts in Transforaminal Lumbar Interbody Fusion (TLIF) for Treating Lumbar Pyogenic Spondylodiscitis. Mediators Inflamm. 2023;2023:5171620. doi:10.1155/2023/5171620
21. Ji C, Yu S, Yan N, Wang J, Hou F, Hou T, et al. Risk factors for subsidence of titanium mesh cage following single-level anterior cervical corpectomy and fusion. BMC Musculoskelet Disord. 2020;21(1):21. doi:10.1186/s12891-019-3036-8
22. Zhou E, Huang H, Zhao Y, Wang L, Fan Y. The effects of titanium mesh cage size on the biomechanical responses of cervical spine after anterior cervical corpectomy and fusion: A finite element study. Clin Biomech (Bristol). 2022;91:105547. doi:10.1016/j.clinbiomech.2021.105547
23. Patil ND, El Ghait HA, Boehm C, Boehm H. Evaluation of Spinal Fusion in Thoracic and Thoracolumbar Spine on Standard X-Rays: A New Grading System for Spinal Interbody Fusion. Global Spine J. 2022;12(7):1481–1494. doi:10.1177/2192568220983796
24. Tang Y, Geng X, Li F, Sun Y, Jia L, Zhou S, et al. Factors affecting titanium mesh cage subsidence in single-level anterior cervical corpectomy and fusion for ossification of the posterior longitudinal

ligament. J Orthop Surg Res. 2022;17(1):539. doi:10.1186/s13018-022-03409-6

25. Lu DC, Wang V, Chou D. The use of allograft or autograft and expandable titanium cages for the treatment of vertebral osteomyelitis. Neurosurgery. 2009;64(1):122–129. doi:10.1227/01.NEU.0000336332.11957.0B
26. Bapat MR, Chaudhary K, Garg H, Laheri V. Reconstruction of large iliac crest defects after graft harvest using autogenous rib graft: a prospective controlled study. Spine (Phila Pa 1976). 2008;33(23):2570–2575. doi:10.1097/BRS.0b013e318185287d
27. Rezvani M, Veisi S, Sourani A, Ahmadian H, Foroughi M, Mahdavi SB, et al. Spondylodiscitis instrumented fusion, a prospective case series on a standardized neurosurgical protocol with long term follow up. Injury. 2024;55(2):111164. doi:10.1016/j.injury.2023.111164
28. Hamed M, Brandecker S, Lampmann T, Asoglu H, Salemdawod A, Güresir E, et al. Early fusion outcome after surgical treatment of single-level and multi-level pyogenic spondylodiscitis: experience at a level 1 center for spinal surgery-a single center cohort study. J Orthop Surg Res. 2023;18(1):107. doi:10.1186/s13018-023-03584-0

Figures

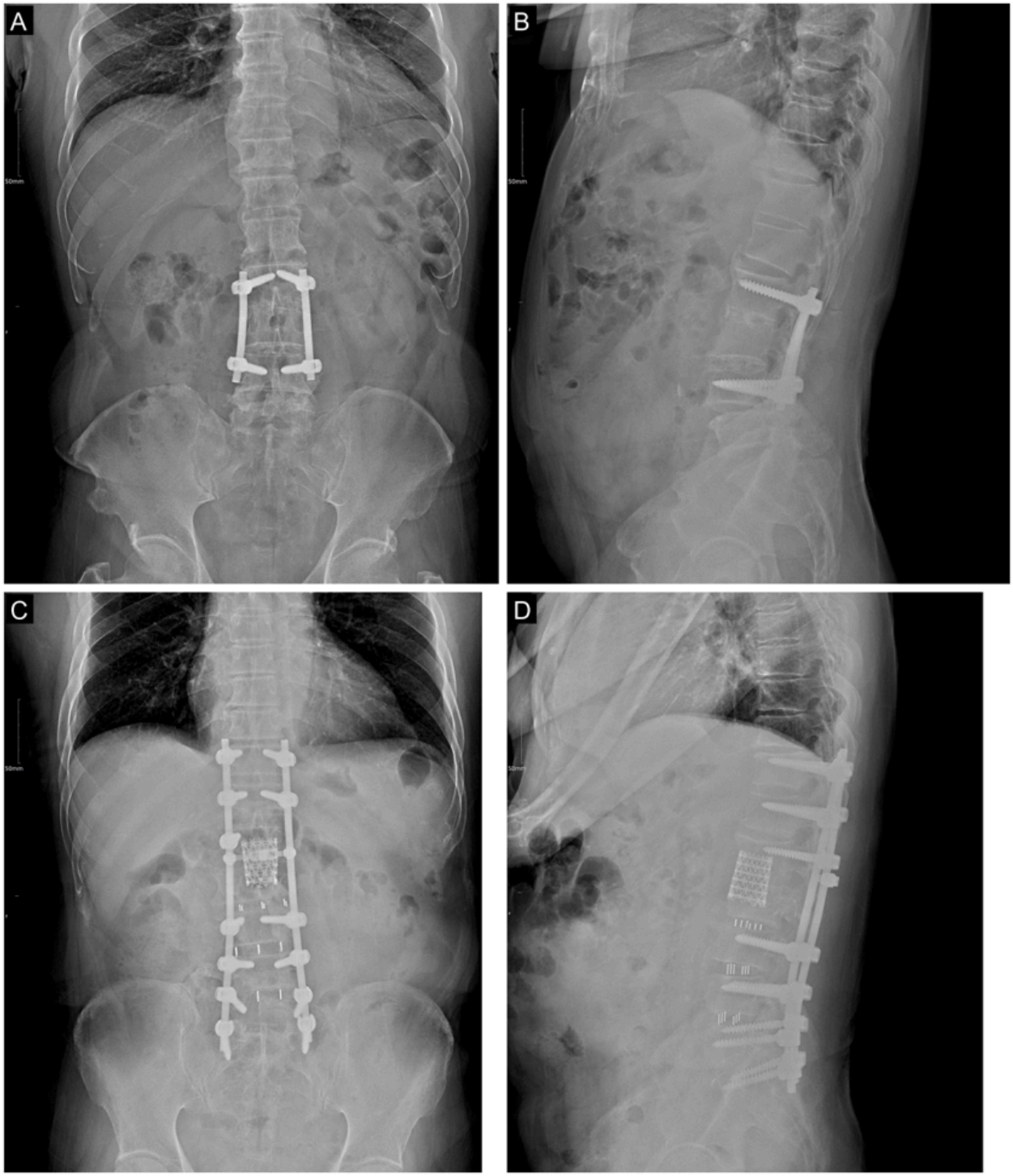

Figure 1

Representative postoperative radiographs of anterior column reconstruction. (A, B) Anteroposterior and lateral radiographs of a 54-year-old man in the Auto group who underwent L2–3 corpectomy and autogenous tricortical iliac crest strut graft reconstruction with posterior pedicle screw fixation, showing confirmed fusion (grade 2) at 24 months without subsidence. (C, D) Anteroposterior and lateral radiographs of a 76-year-old man in the Ti group who underwent L1–2 corpectomy and titanium mesh

cage reconstruction with posterior pedicle screw fixation, showing confirmed fusion (grade 2) at 23 months with mild cage subsidence.