Research Square

Preprints are preliminary reports that have not undergone peer review.
They should not be considered conclusive, used to inform clinical practice,
or referenced by the media as validated information.

Femtosecond laser–assisted nanothin DSAEK using optical coherence tomography–guided pachymetric oversizing: outcomes and risk factors for failure

Jose A. Gegundez-Fernandez

doctorgegundez@gmail.com

Hospital Clinico San Carlos

Barbara Burgos-Blasco

Hospital Clinico San Carlos

Mayte Ariño-Gutierrez

Hospital Clinico San Carlos

Belen Alfonso-Bartolozzi

Instituto oftalmologico Fernandez-Vega

Carlos Lisa-Fernandez

Instituto oftalmologico Fernandez-Vega

Luis Fernandez-Vega Cueto

Instituto oftalmologico Fernandez-Vega

Rosalia Mendez-Fernandez

Hospital Clinico San Carlos

David Diaz-Valle

Hospital Clinico San Carlos

Jose F. Alfonso-Sanchez

Instituto oftalmologico Fernandez-Vega

Research Article

Keywords: DSAEK, ultrathin, nanothin, femtosecond laser, intraoperative OCT

Posted Date: June 28th, 2026

DOI: https://doi.org/10.21203/rs.3.rs-10143266/v1

License: This work is licensed under a Creative Commons Attribution 4.0 International License.
Read Full License

Additional Declarations: No competing interests reported.

Abstract

Purpose:To describe femtosecond laser donor preparation for nanothin Descemet stripping automated endothelial keratoplasty (DSAEK) using intraoperative optical coherence tomography (OCT) guidance and pachymetric oversizing, and to report outcomes and risk factors for failure.

Methods:Retrospective interventional case series. Donor corneas were cut using femtosecond deep lamellar dissection with pachymetric oversizing and the dissection plane was monitored using intraoperative OCT to target a graft thickness of 50–75 μm. Outcomes included intraoperative and 1-month graft thickness, best-corrected visual acuity (BCVA), and endothelial cell density (ECD) at 1 year. Preoperative factors included isolated endothelial failure, re-transplantation, aphakia, glaucoma drainage device, iris abnormalities, and prior posterior vitrectomy.

Results:Eighteen eyes were included. The mean age was 64.6 years (range, 16–89). Mean intraoperative graft thickness was 57.0 μm (range 38–74), decreasing to 49.9 at 1 month (range 30–79). Clinical success was achieved in 10 (55.6%) eyes. Postoperative BCVA was significantly better in successful cases (median 0.52 vs 1.60 LogMAR; *P*=0.001). One-year ECD was available for 10 eyes (mean 1,338.3 cells/mm²; range, 860–1,900). Primary cases were significantly more likely to achieve success (87.5% vs. 12.5%; *P*=0.041), whereas re-transplantation showed a trend toward failure (*P*=0.070).

Conclusion:OCT-guided pachymetric oversizing during femtosecond donor cutting produced reproducible ultrathin/nanothin DSAEK graft thickness. Visual outcomes were significantly better in successful cases. In this complex cohort, primary cases were more likely to achieve success, whereas prior graft failure tended to have lower success rates.

Key messages

- Femtosecond laser–assisted nanothin DSAEK with OCT-guided pachymetric oversizing enables reproducible preparation of ultrathin grafts, even in complex eyes.
- Primary case status and larger graft diameter are significantly associated with clinical success, while prior graft failure is linked to lower success rates.
- Postoperative visual acuity is significantly better in successful cases, highlighting the importance of precise donor preparation and patient selection.

Introduction

Endothelial keratoplasty has largely replaced penetrating keratoplasty (PK) for isolated endothelial dysfunction, offering faster visual rehabilitation and less refractive morbidity [1-3]. Conventional Descemet stripping automated endothelial keratoplasty (DSAEK; ≥100 μm) typically relies on microkeratome or femtosecond laser (FSL) dissection, resulting in thicker grafts and more gradual visual recovery. Ultrathin DSAEK (50–100 μm) and nanothin DSAEK (≤50 μm) use refined preparation

techniques (eg, double-pass microkeratome or FSL approaches) to achieve faster and improved visual outcomes approaching those of Descemet membrane endothelial keratoplasty (DMEK), while preserving the handling advantages of DSAEK [4-6]. However, thinner grafts require greater control during tissue preparation and manipulation [7].

Comparative studies and meta-analyses generally report better high-contrast visual acuity after DMEK, while ultrathin/nanothin DSAEK may offer a lower complication burden in selected settings [8-10]. Achieving consistently thin planar grafts remains technically demanding and requires precise, reproducible donor preparation [4-6]. Procedure selection depends on surgeon experience, ocular anatomy, and comorbidities.

FSL approaches have been explored to improve the precision and consistency of posterior lamellar preparations [11-13]. However, standard platforms often limit the minimum cutting depth to approximately 125 µm from the endothelial surface, restricting the ability to create thinner grafts. Pachymetric oversizing—intentional overestimation of corneal thickness in the planning software—allows the cutting plane to be set closer to the endothelium [14]. In parallel, intraoperative optical coherence tomography (OCT) enables real-time visualization and quantitative control of tissue planes, supporting image-guided maneuvers and decision-making [15-17] and facilitates reliable reduction of graft thickness into the nanothin range.

Most nanothin DSAEK techniques reported to date are microkeratome-based and rely on pachymetry-driven nomograms, whereas femtosecond-only approaches have largely been described in laboratory settings or within an ultrathin range [18-19].

We report an initial clinical series of FSL–assisted ultrathin/nanothin DSAEK using intraoperative OCT-guided pachymetric control and an oversizing strategy. We further explored preoperative factors associated with success versus failure in a cohort of patients with complex anterior segment conditions.

Methods

Study design and ethics

This retrospective interventional case series included 18 consecutive DSAEK procedures that were performed by a single surgeon (JAGF) between June 2022 and October 2025. Institutional Review Board approval was obtained from both centers, written informed consent was obtained from all participants, and the study adhered to the Declaration of Helsinki.

Preoperative and surgical characteristics

Preoperative factors included isolated endothelial failure, prior graft failure (re-transplantation) versus primary case status, presence of a glaucoma drainage device, prior posterior vitrectomy (PPV), aphakia, and iris abnormalities. The surgical approach consisted of primary corneal transplantation,

repeat procedures over the previous PK, deep anterior lamellar keratoplasty (DALK) or superficial anterior lamellar keratoplasty (SALK), and combined modalities with PPV or retropupillary iris-claw intraocular lens (IOL) implantation for aphakia.

Donor preparation

All donor corneas were prepared using the Victus® FSL platform (Bausch & Lomb, Rochester, NY, USA) equipped with high-resolution real-time intraoperative OCT guidance. Donor tissue was mounted in a Barron® artificial anterior chamber (Katena Products, Inc., Corza Medical, Parsippany, NJ, USA). Pachymetric oversizing was performed by intentionally overestimating corneal thickness in the planning software, allowing the cutting plane to be set closer to the endothelium than standard platform limits. This approach enables the creation of ultrathin/nanothin of 50–75 µm grafts while minimizing the risk of perforation and improving reproducibility, especially in regular, homogeneous corneas.

The lenticule was fashioned with a bed-cut close to the Descemet membrane and an internal side-cut directed toward the endothelium (typically 7.8–8.1 mm in diameter). Laser parameters were as follows: bed energy 0.95 µJ with spot/line spacing 5.5/5.5 µm; rim energy 1.10 µJ with spot/line spacing 5.5/2.0 µm; and side-cut angle 90°. The key steps of donor preparation and the surgical procedure are illustrated in both Fig. 1 and supplemental digital content (Video 1).

After FSL cutting, the donor cornea was removed from the artificial chamber, inverted, and the pre-cut endothelial-stromal lenticule was carefully dissected using a Sinskey hook and blunt spatulas to avoid any contact with the endothelium. The graft was temporarily stored in preservation solution until implantation in the recipient.

Recipient surgical technique and postoperative management

The incision size ranges from 4.0 to 4.5 mm. A Busin glide was used for graft insertion in most cases, employing a pull-through technique; an Endoserter® device (CorneaGen, Seattle, WA, USA) was used in 3 cases. The anterior chamber was filled with sulfur hexafluoride (SF6) to promote adherence. Postoperative management included strict supine positioning for 4 hours followed by intermittent supine positioning per protocol for 24-48 hours. Topical tobramycin 0.3% or moxifloxacin 0.5% was prescribed for 1 week, and topical dexamethasone 1% four times daily for 1 month, then tapered monthly until fluorometholone acetate 1% once daily for 6 months.

Outcome measures

Clinical success was defined as a clear graft with improved visual acuity and no need for repeat keratoplasty at 1 year. Failure was defined as persistent graft edema, loss of clarity, or the need for re-transplantation.

Outcomes included intraoperative and 1-month graft thickness, best-corrected visual acuity (BCVA; logMAR), and endothelial cell density (ECD) at 1 year (when available). Complications were recorded.

Statistical analysis

Given the limited sample size, multivariable modeling was not performed, and all the risk factor analyses were exploratory. Categorical variables were compared using two-sided Fisher's exact test. Odds ratios (ORs) for success and 95% confidence intervals (CIs) were also calculated. Haldane–Anscombe correction (adding 0.5 to all cells) was applied when the cell count was zero. Continuous variables were compared using the Mann–Whitney U test. All tests were two-sided, and $P<0.05$. BCVA is presented as median (range); other continuous variables are presented as mean ± SD (range) unless otherwise specified.

Results

Supplementary Table S1 provides the individual case data for the FSL-assisted nanothin DSAEK cohort. Table 1 summarizes the key clinical, surgical, and outcome variables for the cohort, grouped by success and failure.

Cohort characteristics

Eighteen eyes of 18 patients (10 male, 8 female) were included (mean age 64.6 ± 18.7 years; range 16–89). There was a non-significant trend toward higher age in the success group compared to failures (mean 71.5 ± 12.6 vs 56.0 ± 22.2 years, respectively, $P = 0.172$). Complex cases comprised 83.3% of the cohort (15/18), including 10 re-transplants (55.6%), 4 aphakic eyes (22.2%), 4 eyes with glaucoma drainage devices (22.2%), 3 with iris abnormalities (16.7%; partial aniridia, atrophy, or synechiae), and 8 with prior PPV (44.4%).

Surgical indications

Eight eyes underwent a primary DSAEK. Ten patients previously had previously undergone surgery, including repeat endothelial grafting after DSAEK (n=4), DSAEK over prior penetrating keratoplasty (n=2), DSAEK in eyes with prior DALK (n=1) or prior SALK (n=1), DSAEK combined with PPV (n=1), and DSAEK combined with retropupillary iris-claw IOL implantation (n=1).

Donor and recipient measurements

Mean graft diameter was 7.7 ± 0.4 mm (range 6.0–8.1), and mean donor central corneal thickness was 573.3 ± 47.8 µm (range 505–640). Graft diameter was significantly greater in the success group (mean 7.9 ± 0.1 mm) than in the failure group (mean 7.6 ± 0.6 mm, $P = 0.037$). Mean intraoperative graft thickness was 57.0 ± 8.8 µm (range 38–74) and mean 1-month thickness was 49.9 ± 14.9 µm (range 30–79). One-month thickness tended to be lower in successes (45.4 ± 13.1 vs 55.6 ± 15.8 µm) without reaching statistical significance ($P=0.182$).

Clinical outcomes and risk factors

Postoperative BCVA was significantly better in successes than in failures (median 0.52 vs 1.60 LogMAR; *P*=0.001), whereas preoperative BCVA did not differ (*P*=0.143). Fig. 2 shows the postoperative visual acuity outcomes according to group.

Clinical success was achieved in 10 of 18 eyes (55.6%), defined as a clear graft with improved visual acuity and no need for repeat keratoplasty at 1 year. The preoperative factors associated with success and failure are summarized in Table 2. On univariate analysis (Fisher exact test), primary cases (no prior graft) were significantly more likely to achieve clinical success (87.5% vs. 12.5%; OR for success 21.00, 95% CI 2.00–220.44; *P*=0.041). Re-transplantation was associated with a lower likelihood of success (30.0% vs. 70.0%; OR 0.11, 95% CI 0.01–0.77; *P*=0.070), although this was not reach statistically significant. The presence of a glaucoma drainage device showed a trend toward lower success rates (25.0% vs. 75.0%; OR 0.19, 95% CI 0.01–2.34; *P*=0.273). Aphakia was not associated with clinical outcomes (OR 0.75, 95% CI 0.10–5.93; *P*=1.000) or prior posterior vitrectomy (OR 1.67, 95% CI 0.22–12.67; *P*=0.638). Iris defects were not significantly associated with treatment failure (OR 0.33, 95% CI 0.03–4.00; *P*=0.523). Isolated endothelial failure showed a nonsignificant trend toward higher success (100% vs. 0%; OR 7.93, 95% CI 0.35–180.91; *P*=0.200). Given the small sample size and wide confidence intervals, these findings should be interpreted as exploratory in nature. Fig. 3 displays the odds ratios for preoperative risk factors.

One-year ECD was available in 8 eyes (mean 1,338.3 ± 382.5 cells/mm²; range 860–1,900) and was unavailable in failures.

Complications were infrequent: one retinal detachment and one DALK melting occurred (both failures). No rebubbling was recorded and no graft rejection occurred.

Discussion

This series demonstrates that FSL donor preparation with real-time OCT pachymetric control can reproducibly produce nanothin DSAEK grafts, achieving a mean thickness of approximately 50 μm at one month. Achieving thinner posterior lamellar grafts is clinically relevant, because thinner grafts have been associated with faster visual recovery and outcomes approaching DMEK in selected cohorts [4-6].

To date, clinical series specifically reporting nanothin DSAEK prepared exclusively with femtosecond laser techniques are scarce, with most nanothin approaches relying on microkeratome-based methods [7]. Table 3 summarizes key differences between microkeratome- and femtosecond laser–based donor preparation techniques for ultrathin/nanothin DSAEK. The advantage of pachymetric oversizing lies in its ability to overcome platform limitations for minimum cutting depth, enabling safe and reproducible preparation of nanothin grafts. By intentionally overestimating donor thickness, the surgeon can achieve a dissection plane closer to the endothelium, which is particularly valuable in complex cases where precise control is essential.

Despite achieving the target thickness, overall clinical success was strongly influenced by the patient's history. In our exploratory univariate analysis, primary cases were significantly more likely to achieve success, whereas prior graft failure (re-transplantation) showed a trend toward lower success and glaucoma drainage devices showed a nonsignificant trend in the same direction. In contrast, prior posterior vitrectomy, aphakia, and iris defects were not significantly associated with the outcomes in this cohort. These findings should be interpreted cautiously given the small sample size, heterogeneous indications, and wide confidence intervals.

Few clinical series have reported the outcomes of DSAEK prepared exclusively using FSL techniques, and most published studies have focused on ultrathin rather than nanothin grafts. Rosa et al. and Hosny et al. achieved mean graft thicknesses in the ultrathin range (typically 80–110 μm), with visual outcomes comparable to those of conventional DSAEK, but without significant improvement in endothelial cell density or complication rates [11-12]. Tan et al. provided morphological and scanning electron microscopy evaluation of FSL-prepared donor lamellae, demonstrating precise dissection but noting that clinical application was restricted to the ultrathin range due to minimum depth settings [13]. More recently, Diaz-Valle et al. confirmed the feasibility of achieving thinner grafts using intentional pachymetric oversizing and real-time OCT guidance, but clinical data remain limited. Importantly, this technique requires regular, homogeneous corneas without and is not suitable for keratoconus [14]. Phillips et al. described ultrathin DSAEK tissue prepared with low-pulse energy, high-frequency FSL, achieving mean thicknesses of 60–80 μm and demonstrating endothelial viability comparable to controls, but nanothin results were not reported [18]. Alburayk et al. presented six-year outcomes of ultrathin FSL-assisted DSAEK, with mean graft thicknesses of 70–90 μm and stable endothelial cell density, but again, nanothin grafts (<50 μm) were not the focus [19]. Favorable clinical outcomes for nanothin DSAEK have also been reported in other series, such as Han YE et al., which demonstrated improved visual acuity and safety in Korean patients with corneal endothelial dysfunction [20].

In contrast, our series achieved mean intraoperative and postoperative graft thicknesses in the nanothin domain (~50 μm at 1 month) using intentional pachymetric oversizing and real-time OCT guidance to overcome the platform limitations. The visual outcomes in our cohort were comparable or superior to those reported in a previous FSL series, with a significant improvement in the postoperative BCVA in successful cases. Comparative evidence generally shows superior high-contrast visual acuity with DMEK, whereas ultrathin/nanothin DSAEK may offer a favorable complication profile in selected settings [8-10]. In clinical practice, procedure selection depends on surgeon experience and ocular anatomy, particularly in higher-risk eyes where DMEK may not be feasible [4-6]. However, even with reproducibly thin grafts, complex ocular comorbidity and prior surgical history remain the dominant determinants of clinical success in our cohort.

Age showed a non-significant trend toward higher values in the success group, whereas graft diameter was significantly associated with clinical outcomes. The finding that a larger graft diameter correlated with success may reflect improved endothelial coverage or technical factors and is consistent with previous reports [21]. Further studies are needed to clarify the clinical relevance of these associations.

The main limitations of this study are the small sample size and the heterogeneity of the cohort, which included both primary and complex cases. These factors may affect the generalizability of the findings, and the results should be interpreted as exploratory and hypothesis-generating.

FSL-assisted nanothin DSAEK using real-time OCT pachymetric oversizing achieved reproducibly thin grafts. In this complex cohort, postoperative BCVA differed significantly between the successes and failure groups. Primary case status was associated with higher success rates, whereas prior graft failure showed a trend toward lower success rates in exploratory analyses.

Declarations

Financial interests: The authors declare they have no financial interests.

Funding: No dedicated external funding was received.

Ethics approval: Institutional Review Board approval was obtained from both centers.

Informed consent: was obtained from all participants, and the study adhered to the Declaration of Helsinki.

References

1. Price FW Jr, Price MO. Descemet's stripping with endothelial keratoplasty in 200 eyes: early challenges and techniques to enhance donor adherence. *J Cataract Refract Surg.* 2006;32(3):411-418. doi:10.1016/j.jcrs.2005.12.078.
2. Price MO, Price FW Jr. Descemet's stripping with endothelial keratoplasty: comparative outcomes with microkeratome-dissected and manually dissected donor tissue. *Ophthalmology.* 2006;113(11):1936-1942. doi:10.1016/j.ophtha.2006.05.034.
3. Gorovoy MS. Descemet-stripping automated endothelial keratoplasty. *Cornea.* 2006;25(8):886-889. doi:10.1097/01.ico.0000214224.90743.01.
4. Busin M, Madi S, Santorum P, Scorcia V, Beltz J. Ultrathin Descemet's stripping automated endothelial keratoplasty with the microkeratome double-pass technique: two-year outcomes. *Ophthalmology.* 2013;120(6):1186-1194. doi:10.1016/j.ophtha.2012.11.030.
5. Hsu M, Hereth WL, Moshirfar M. Double-pass microkeratome technique for ultra-thin graft preparation in Descemet's stripping automated endothelial keratoplasty. *Clin Ophthalmol.* 2012;6:425-432. doi:10.2147/OPTH.S29479.
6. Mencucci R, Favuzza E, Marziali E, Cennamo M, Mazzotta C, Lucenteforte E, Virgili G, Rizzo S. Ultrathin Descemet stripping automated endothelial keratoplasty versus Descemet membrane endothelial keratoplasty: a fellow-eye comparison. *Eye Vis (Lond).* 2020;7:25. doi:10.1186/s40662-020-00191-6.

7. Cheung AY, Hou JH, Bedard P, Grimes V, Buckman N, Eslani M, Holland EJ. Technique for preparing ultrathin and nanothin Descemet stripping automated endothelial keratoplasty tissue. *Cornea.* 2018;37(5):661-666. doi:10.1097/ICO.0000000000001510.
8. Singh A, Zarei-Ghanavati M, Avadhanam V, Liu C. Systematic review and meta-analysis of clinical outcomes of Descemet membrane endothelial keratoplasty versus Descemet stripping endothelial keratoplasty/Descemet stripping automated endothelial keratoplasty. *Cornea.* 2017;36(11):1437-1443. doi:10.1097/ICO.0000000000001320.
9. Hurley DJ, Murtagh P, Guerin M. Ultrathin Descemet stripping automated endothelial keratoplasty (UT-DSAEK) versus Descemet membrane endothelial keratoplasty (DMEK): a systematic review and meta-analysis. *Eye (Lond).* 2023;37(14):3026-3032. doi:10.1038/s41433-023-02467-2.
10. Zhu L, Zha Y, Cai J, Zhang Y. Descemet stripping automated endothelial keratoplasty versus Descemet membrane endothelial keratoplasty: a meta-analysis. *Int Ophthalmol.* 2018;38:897-905. doi:10.1007/s10792-017-0533-3.
11. Rosa AM, Silva MF, Quadrado MJ, Costa E, Marques I, Murta JN. Femtosecond laser and microkeratome-assisted Descemet stripping endothelial keratoplasty: first clinical results. *Br J Ophthalmol.* 2013;97(9):1104-1108. doi:10.1136/bjophthalmol-2012-302378.
12. Hosny MH, Marrie A, Sidky MK, GamalEldin S, Salem M. Results of femtosecond laser-assisted Descemet stripping automated endothelial keratoplasty. *J Ophthalmol.* 2017;2017:8984367. doi:10.1155/2017/8984367.
13. Tan DT, Parthasarathy A, Beuerman RJ, Cajucom-Uy H, Mehta JS, Por YM. Femtosecond laser-assisted endothelial keratoplasty (FLEK): morphological and scanning electron microscopic evaluation of donor cornea posterior lamella preparation with the Femtec 20/10 Perfect Vision femtosecond laser. *Invest Ophthalmol Vis Sci.* 2007;48(suppl):Abstract 1129. ARVO Annual Meeting Abstract.
14. Diaz-Valle D, Burgos-Blasco B, Ariño-Gutierrez M, Gegundez-Fernandez JA. Predescemetic femtosecond laser-assisted deep anterior lamellar keratoplasty with simulated pachymetry. *Graefes Arch Clin Exp Ophthalmol.* 2024;262(5):1653-1655. doi:10.1007/s00417-024-06370-8.
15. Steven P, Le Blanc C, Velten K, Lankenau E, Krug M, Oelckers S, Heindl LM, Gehlsen U, Hüttmann G, Cursiefen C. Optimizing Descemet membrane endothelial keratoplasty using intraoperative optical coherence tomography. *JAMA Ophthalmol.* 2013;131(9):1135-1142. doi:10.1001/jamaophthalmol.2013.4672.
16. Patel AS, Goshe JM, Srivastava SK, Ehlers JP. Intraoperative optical coherence tomography-assisted Descemet membrane endothelial keratoplasty in the DISCOVER study: first 100 cases. *Am J Ophthalmol.* 2019;210:167-173. doi:10.1016/j.ajo.2019.09.018.
17. Muijzer MB, Delbeke H, Dickman MM, Nuijts RMMA, Noordmans HJ, Imhof SM, Wisse RP. Outcomes of the advanced visualization in corneal surgery evaluation trial: randomized trial evaluating intraoperative OCT during DMEK. *Front Ophthalmol.* 2023;2:1041778. doi:10.3389/fopht.2022.1041778.

18. Phillips PM, Phillips LJ, Saad HA, Terry MA, Stolz DB, Stoeger C, Franks J, Davis-Boozer D. Ultrathin DSAEK tissue prepared with a low-pulse energy, high-frequency femtosecond laser. *Cornea.* 2013;32(1):81-86. doi:10.1097/ICO.0b013e31825c72dc.
19. Alburayk K, Al Somali A, Aljindan M, Alshaibani AK, Alkharashi M. Six-year outcome of ultrathin femtosecond laser-assisted Descemet stripping automated endothelial keratoplasty. *Eur J Ophthalmol.* 2025 Dec 3:11206721251403808. doi:10.1177/11206721251403808. Online ahead of print.
20. Han YE, Chung HS, Lee H, Kim JY, Tchah H. Clinical outcomes of nanothin Descemet stripping automated endothelial keratoplasty in Korean patients with corneal endothelial dysfunction. *Korean J Ophthalmol.* 2022;36(2):131-137. doi:10.3341/kjo.2021.0161.
21. Tan GS, He M, Tan DT, Mehta JS. Correlation of anterior segment optical coherence tomography measurements with graft trephine diameter following Descemet stripping automated endothelial keratoplasty. *BMC Med Imaging.* 2012;12:19. doi:10.1186/1471-2342-12-19.

Tables

Table 1. Patient characteristics and clinical and surgical outcomes by group

Variable[a]	Overall (n=18)	Success (n=10)	Failure (n=8)	*P* (Mann–Whitney U)
Clinical outcome, n (%)	18 (100)	10 (55.6)	8 (44.4)	—
Age (years)	64.6 ± 18.7	71.5 ± 12.6	56.0 ± 22.2	0.172
Graft diameter (mm)	7.7 ± 0.4	7.9 ± 0.1	7.6 ± 0.6	0.037*
Donor pachymetry (μm)	573.3 ± 47.8	568.0 ± 47.3	580.0 ± 50.8	0.563
Intraoperative graft thickness (μm)	57.0 ± 8.8	55.4 ± 8.9	59.0 ± 8.8	0.247
Postoperative month-1 thickness (μm)	49.9 ± 14.9	45.4 ± 13.1	55.6 ± 15.8	0.182
BCVA preoperative (LogMAR)	1.60 (0.70–2.30)	1.30 (0.70–2.30)	1.60 (1.30–2.30)	0.143
BCVA postoperative (LogMAR)	1.05 (0.40–1.60)	0.52 (0.40–1.60)	1.60 (1.30–1.60)	0.001*
ECD[b] at 1 year (cells/mm²)	—	1,338.3 ± 382.5	NA	—
Complications, n (%)	2/18 (11.1)	0/10 (0)	2/8 (25.0)	—

Abbreviations: BCVA, best-corrected visual acuity; ECD, endothelial cell density; LogMAR, logarithm of the minimum angle of resolution; NA, not available.

[a] BCVA is presented as median (range); age, graft diameter, thickness variables, and ECD as mean ± SD.

[b] ECD was only available for the 10 successful eyes; no hypothesis testing was performed.

Table 2. Preoperative risk factors associated with success vs failure

Preoperative factor	Success n/N (%)	Failure n/N (%)	*P* (Fisher)[a]	OR for success (95% CI)
Re-transplant	3/10 (30.0)	7/10 (70.0)	0.070	0.11 (0.01–0.77)
Primary case (no prior graft)	7/8 (87.5)	1/8 (12.5)	0.041*	21.00 (2.00–220.44)
Valve (glaucoma drainage device)	1/4 (25.0)	3/4 (75.0)	0.273	0.19 (0.01–2.34)
PPV	5/8 (62.5)	3/8 (37.5)	0.638	1.67 (0.22–12.67)
Aphakia	2/4 (50.0)	2/4 (50.0)	1.000	0.75 (0.10–5.93)
Iris defect	1/3 (33.3)	2/3 (66.7)	0.523	0.33 (0.03–4.00)
Isolated endothelial failure	3/3 (100.0)	0/3 (0.0)	0.200	7.93 (0.35–180.91)

Abbreviations: ORs, odds ratio; PPV, pars plana vitrectomy.

[a] Fisher exact tests are two-sided. Haldane–Anscombe correction (adding 0.5 to all cells) was applied when any cell count was zero.

Table 3. Microkeratome-based vs femtosecond laser–based donor preparation for ultrathin/nanothin DSAEK

Aspect	Microkeratome-based	Femtosecond laser-based
Cutting principle	Mechanical lamellar dissection (single- or double-pass) using pachymetry-based nomograms.[a,c,e]	Photodisruptive lamellar dissection planned by depth; minimum cutting depth limited by platform.[e]
Nanothin capability (≤50 µm)	NT grafts ≤50 µm achieved with nomogram-driven techniques.[c,f]	Clinical femtosecond-only series rarely report explicit NT thickness; data mainly in UT range.[e]
Thickness reproducibility	Dependent on donor pachymetry/nomograms; variability and tissue loss reported with double-pass techniques.[c]	High planning precision. OCT enables real-time verification to safely approach the endothelium.[d]
Preparation risks / interface	Perforations reported, particularly during second microkeratome pass.[a]	Acceptable endothelial viability. Stromal surface quality reported as suboptimal in laboratory studies.[b]
Endothelial viability	Endothelial cell loss comparable to UT-DSAEK and DMEK when preparation is successful.[c,f]	Endothelial damage comparable to controls in laboratory studies, with no clear detrimental effect attributable to laser cutting.[e]
Evidence base	Extensive clinical literature (UT/NT-DSAEK).[a,c,f]	Limited to laboratory studies and UT clinical series; NT femtosecond-only data scarce.[e,b]
Present study	—	Mean intraoperative thickness 56.1 µm and 1-month thickness 49.9 µm using OCT-guided pachymetric oversizing.

Abbreviations: DSAEK, Descemet stripping automated endothelial keratoplasty; NT, nanothin; OCT, optical coherence tomography; UT, ultrathin.

[a] Busin[4], 2013. [b] Hsu[5], 2012. [c] Cheung[7], 2018. [d] Steven[15], 2013. [e] Phillips[18], 2013. [f] Han[20], 2022

Figures

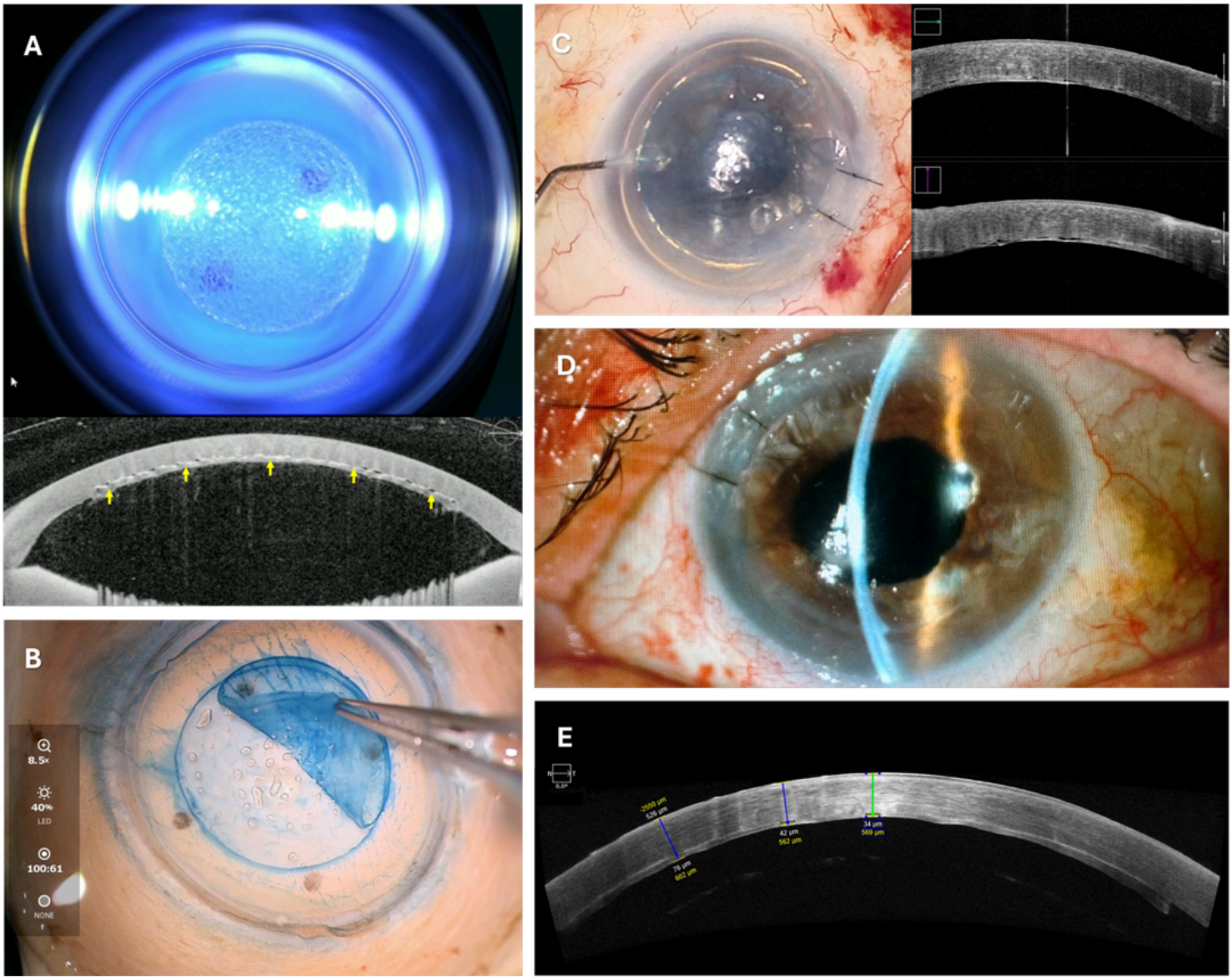

Figure 1

Key steps in femtosecond laser–assisted nanothin DSAEK. (A) Femtosecond laser lamellar cut of the donor cornea (yellow arrows). (B) Manual dissection of the endothelial–stromal lenticule avoiding any contact with the endothelium. (C) Graft insertion and anterior chamber gas fill (SF6). (D) Postoperative slitlamp appearance with a clear graft. (E) Anterior segment OCT demonstrating nanothin graft thickness at 1 month.

DSAEK, Descemet stripping automated endothelial keratoplasty; OCT, optical coherence tomography; SF6, sulfur hexafluoride.

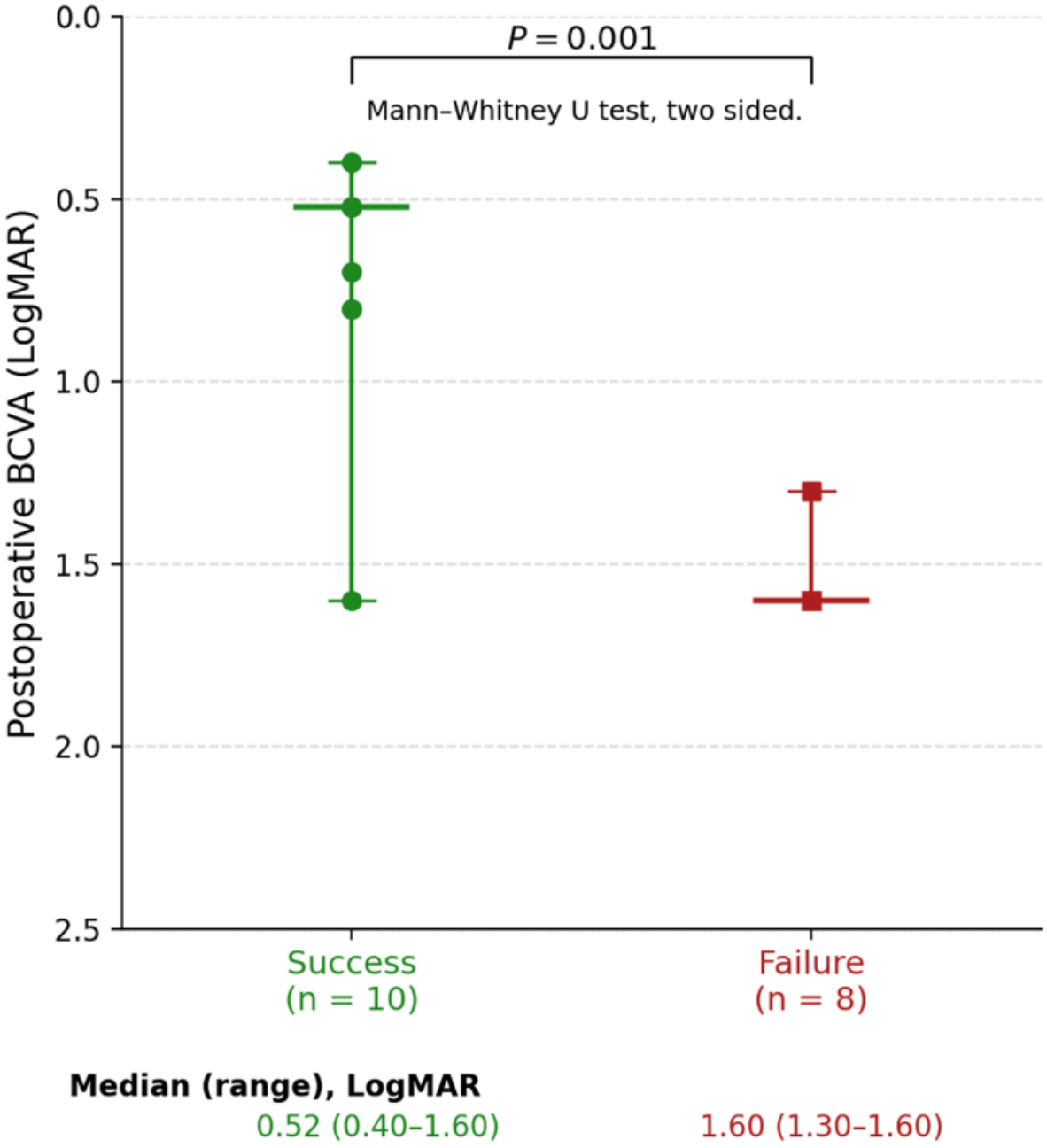

Figure 2

Postoperative BCVA (LogMAR) by clinical outcome (success n=10 vs failure n=8).

BCVA, best-corrected visual acuity; LogMAR, logarithm of the minimum angle of resolution.

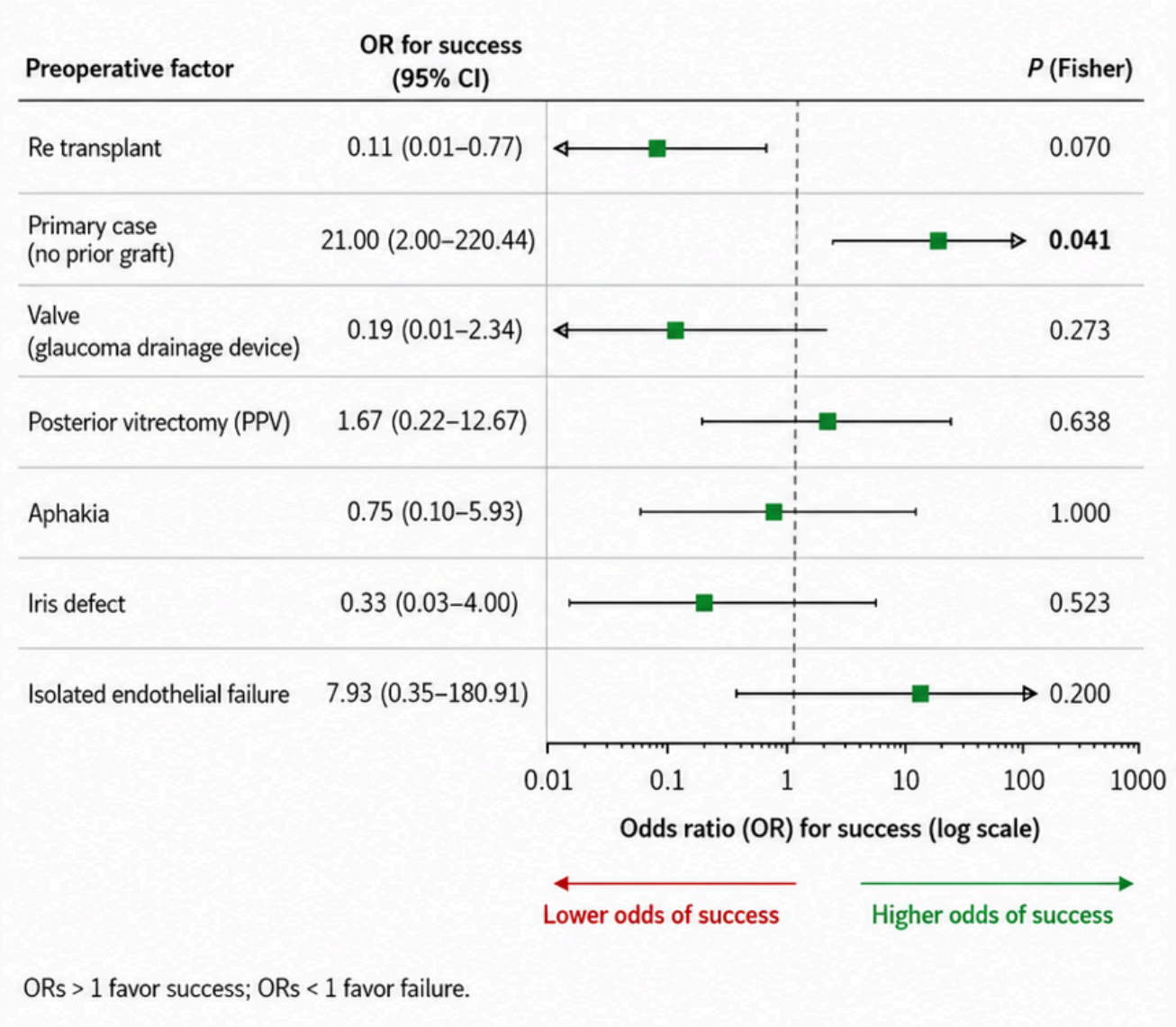

Figure 3

Forest plot of ORs with 95% confidence intervals for preoperative factors associated with clinical success (ORs for success). Haldane–Anscombe correction was applied when any cell count was zero; Fisher exact tests were two-sided. ORs, odds ratios

Supplementary Files

This is a list of supplementary files associated with this preprint. Click to download.

- SupplementaryTableS1.docx
- Video1.mp4